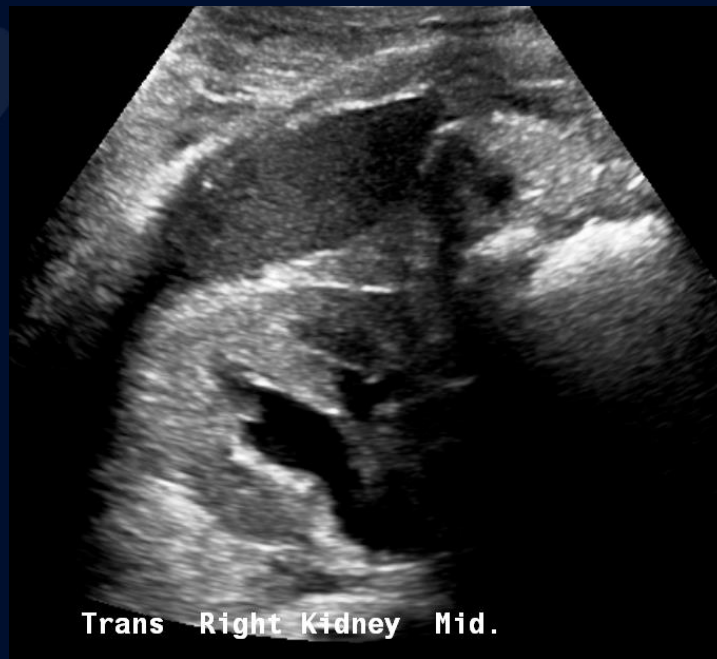
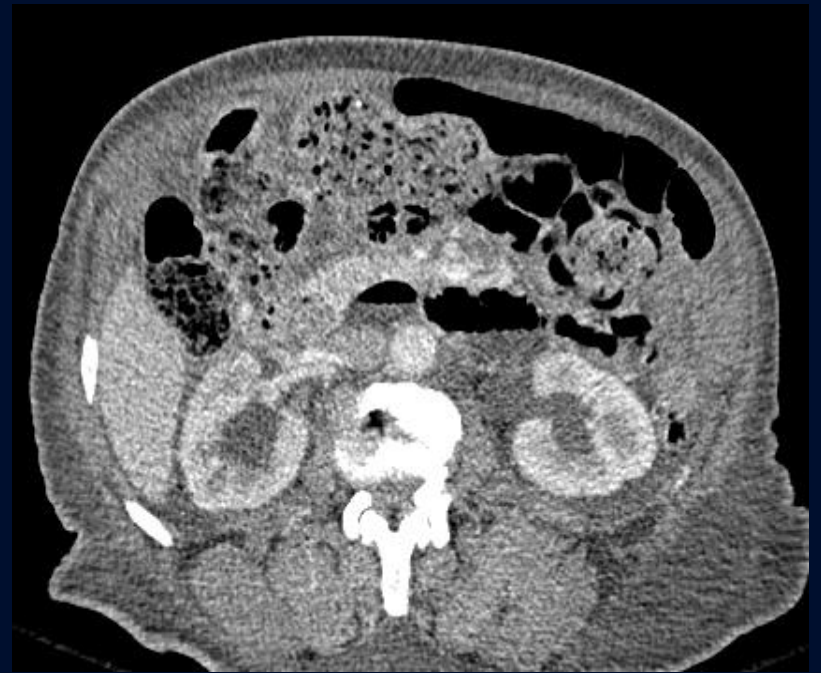
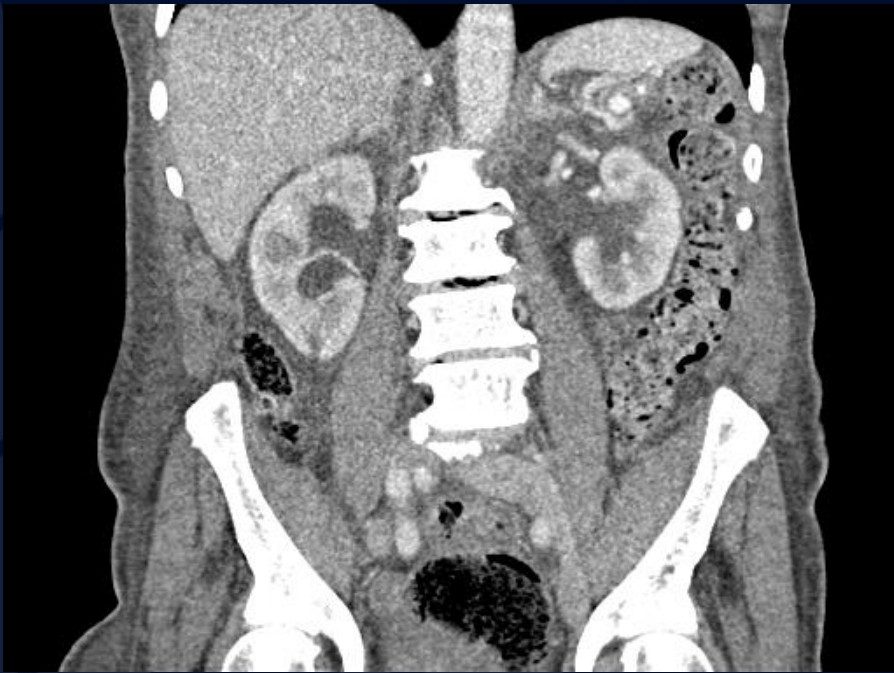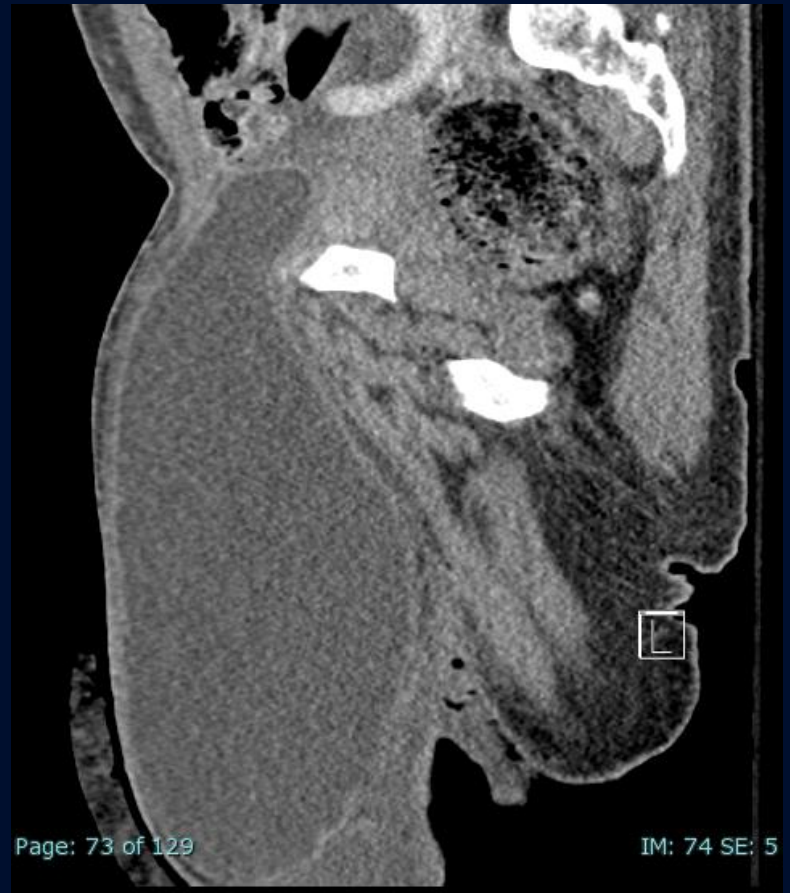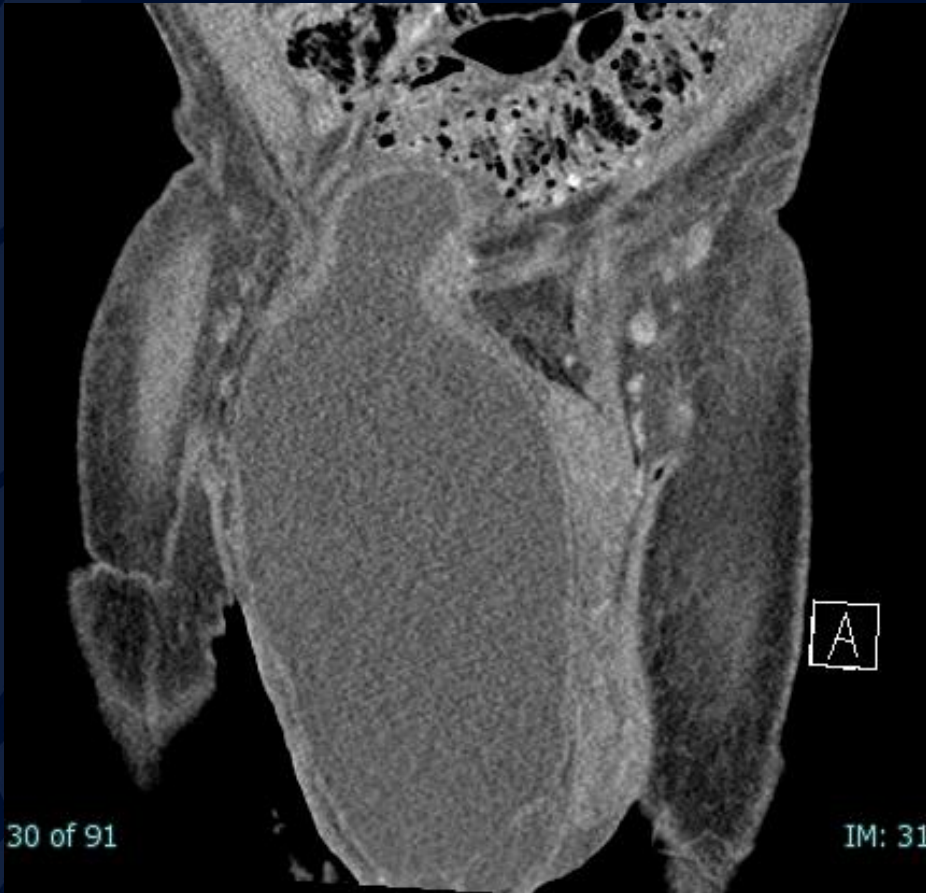92-year-old male presenting with abdominal pain and enlarging scrotum

Jaelle Thorne, MS4



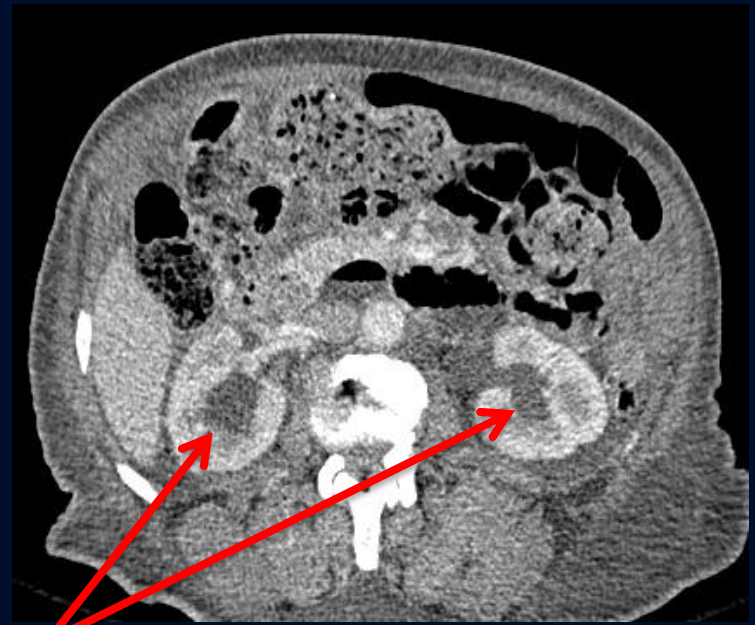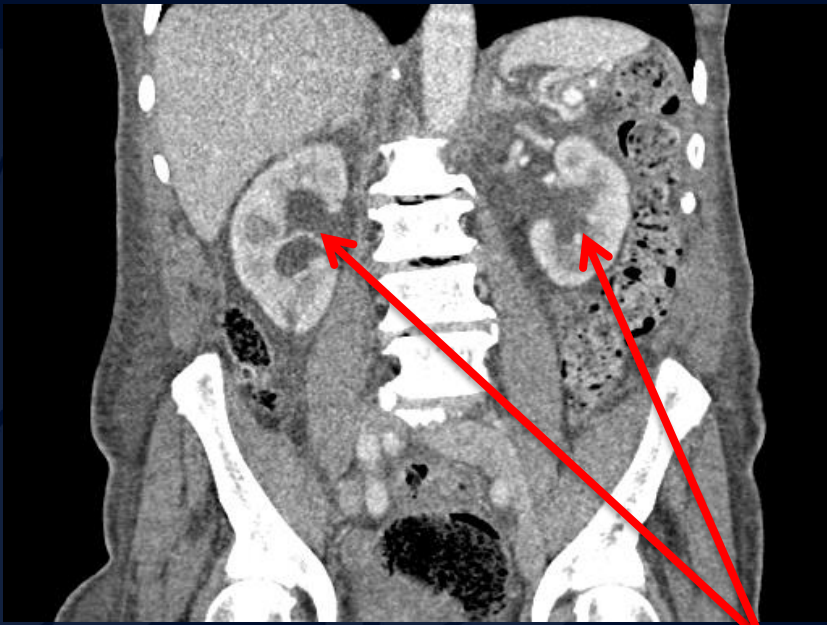
Trans Right Kidney Mid.



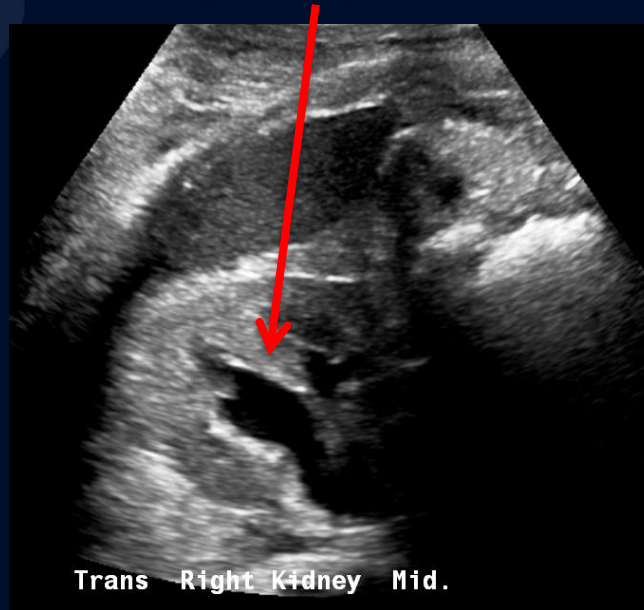
A large, stylized oak leaf graphic in a dark blue color, positioned on the left side of the slide. It features detailed vein patterns and a lobed edge.

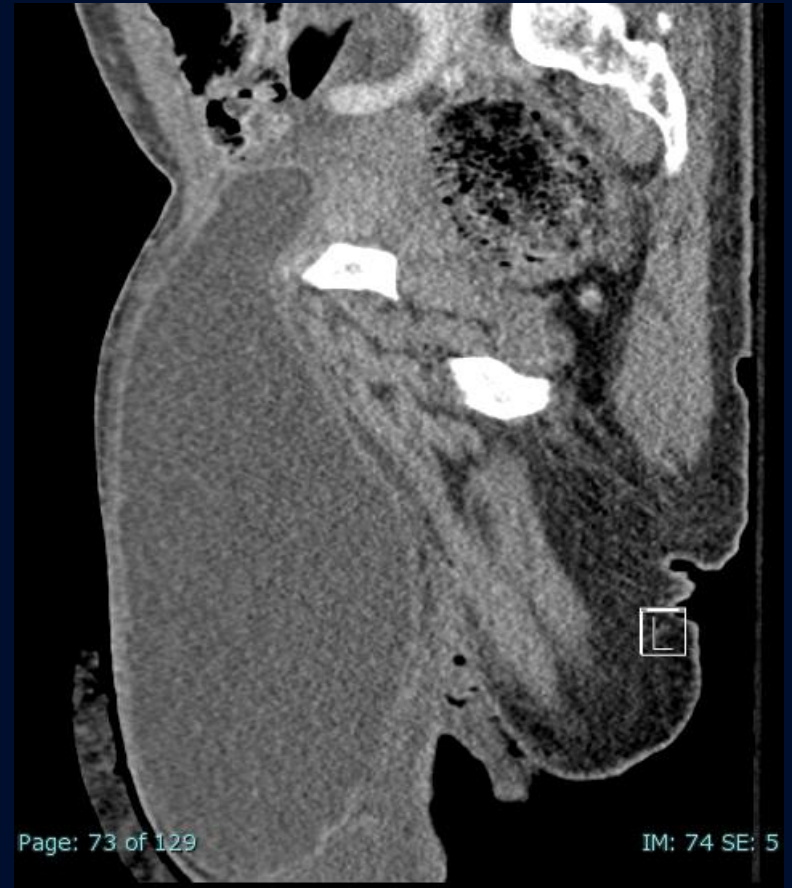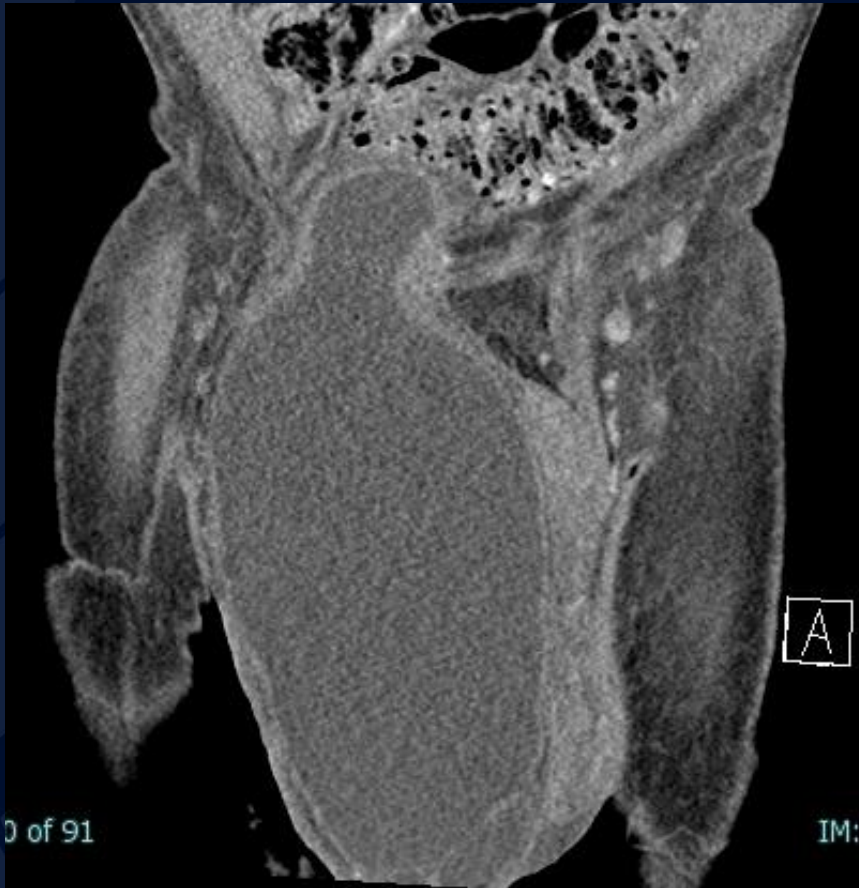?

Scrotal Cystocele



Bilateral
Hydronephrosis





Urinary bladder extending through the right inguinal canal and into the right hemiscrotum

Scrotal Cystocele

- Herniation of the bladder into the inguinal canal and into the scrotal sac.
- Rare, accounts for 1-3% of inguinal hernias
- Risk factors include male gender, age greater than 50 years and obesity
- Most often asymptomatic and found incidentally
 - If symptomatic, symptoms include pain, dysuria, urinary frequency changes, urgency, nocturia, hematuria
- Possible complications include hydronephrosis, renal failure, vesicoureteral reflux, bladder necrosis or perforation

References

Langer FW, Alves GRT, Suertegaray G, Santos D, Haygert CJP. Incidentally detected massive scrotal cystocele. *Radiol Bras*. 2018 Mar-Apr;51(2):129-130. doi: 10.1590/0100-3984.2016.0145. PMID: 29743747; PMCID: PMC5935414.

Levine B. SCROTAL CYSTOCELE. *JAMA*. 1951;147(15):1439–1441. doi:10.1001/jama.1951.73670320003013a

Zihni İ, Duran A, Soysal V. A rare cause of inguinal hernia: scrotal cystocele. *Ulus Cerrahi Derg*. 2014 Dec 25;32(2):137-9. doi: 10.5152/UCD.2014.2296. PMID: 27436925; PMCID: PMC4942160.