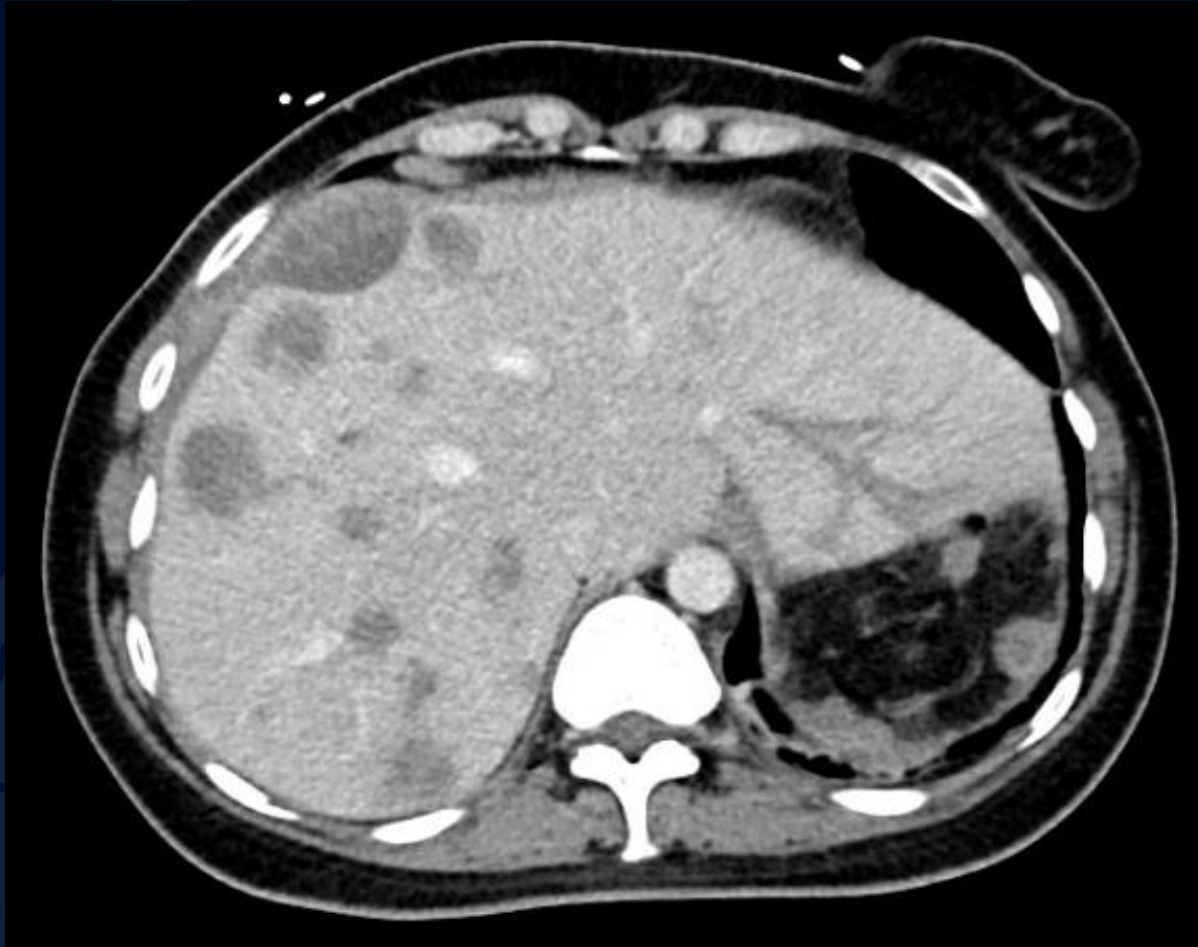

43-year-old female presenting with diffuse abdominal pain and fevers s/p left nephrectomy

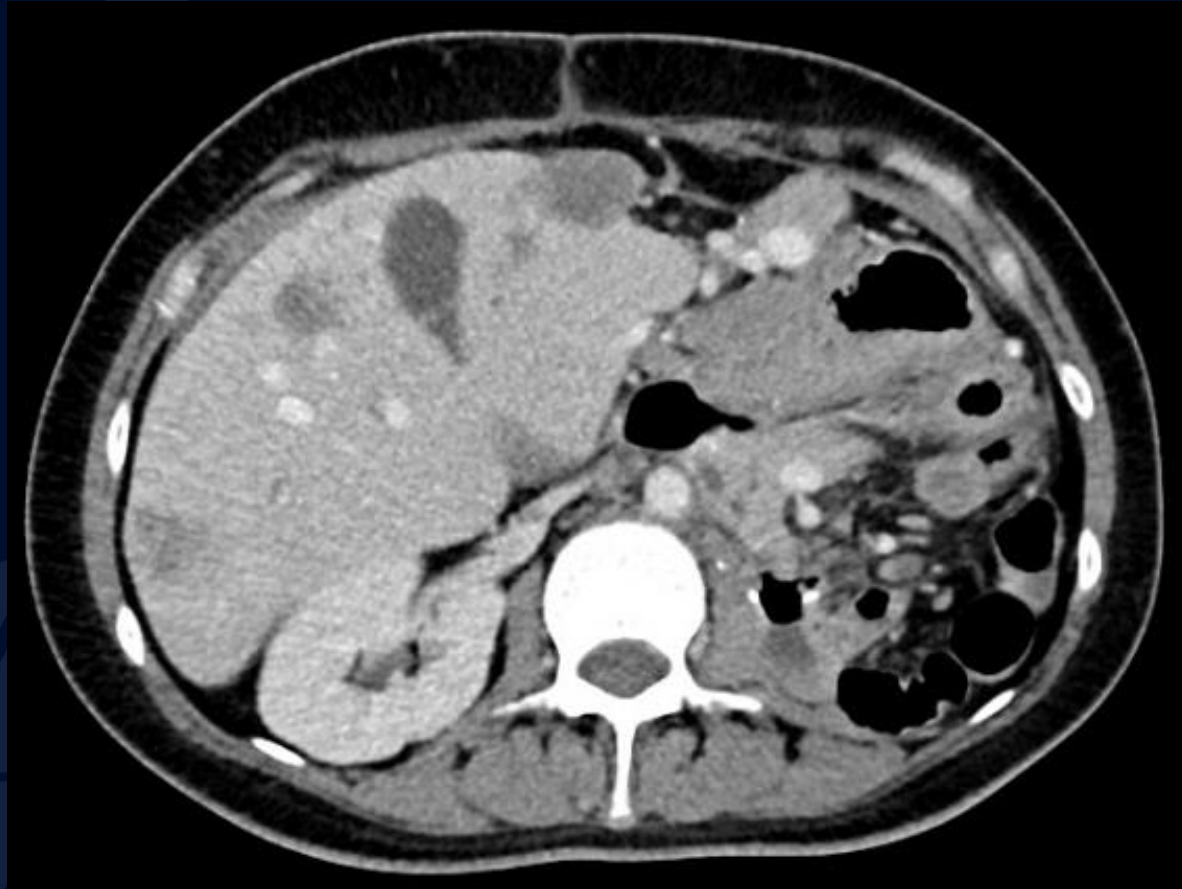
Amanda Hernandez Rodriguez, MS3

Racquel Helsing, MD

CT ABDOMEN AND PELVIS WITH CONTRAST



CT ABDOMEN AND PELVIS WITH CONTRAST



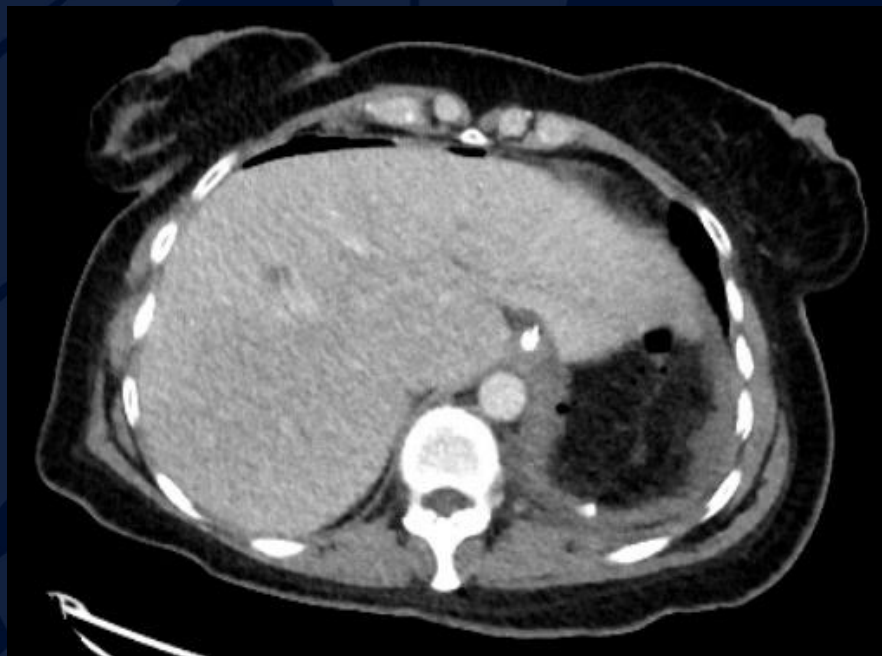A large, stylized oak leaf graphic in a dark blue color, positioned on the left side of the slide. The leaf has a prominent central vein and several smaller veins branching off it. The leaf's edge is serrated.

?

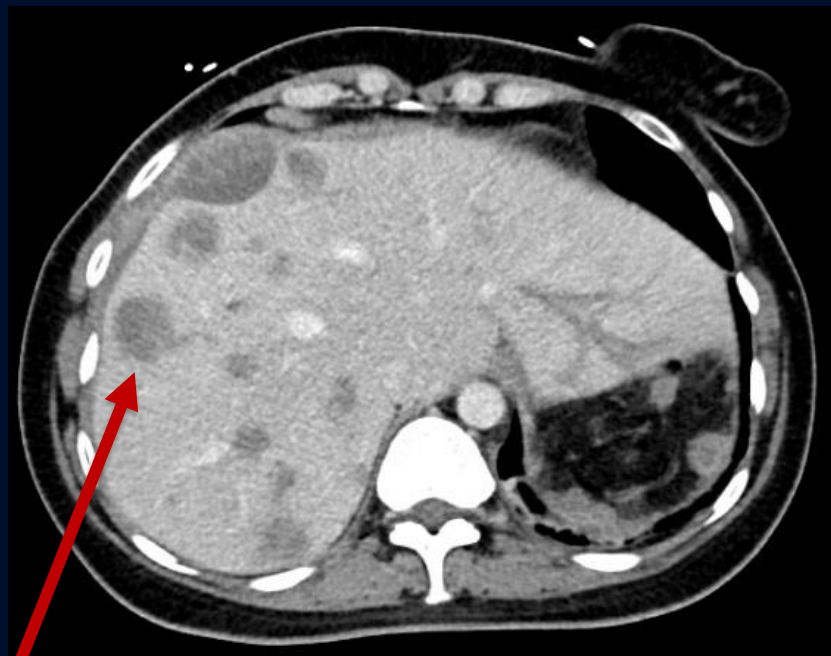
Metastatic Renal Cell Carcinoma (Sarcomatoid Subtype)

CT ABDOMEN AND PELVIS WITH IV CONTRAST

6 months prior



Current

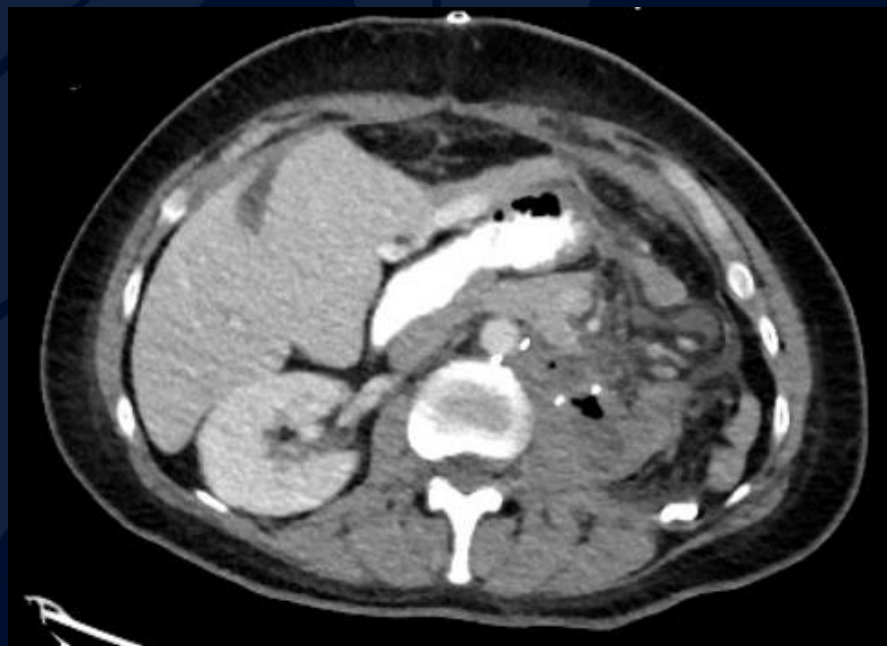

Enlarged liver

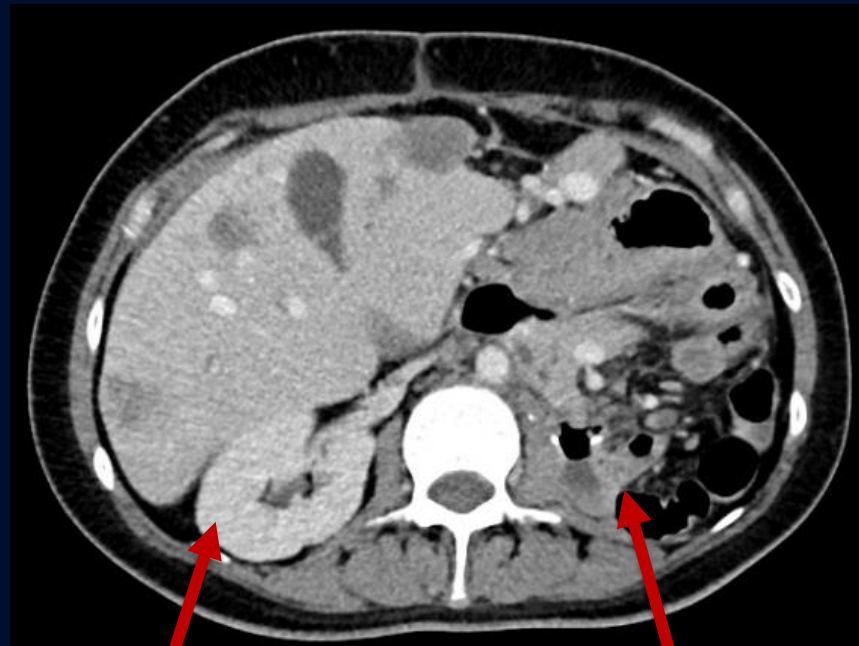
Interval development of multiple
hypodense hepatic masses

CT ABDOMEN AND PELVIS WITH IV CONTRAST

6 months prior



Current



Normal right kidney

S/p left nephrectomy

Metastatic Renal Cell Carcinoma (Sarcomatoid Subtype)

Epidemiology: Renal cell carcinoma (RCC) accounts for 80-85% of all primary renal neoplasms

- Twofold more common in males, predominantly ages 60-80 with median age being 64
- Sarcomatoid subtype accounts for ~15% of RCC cases

Clinical presentation: Patient's with sarcomatoid RCC often present with abdominal pain, hematuria, anorexia and night sweats. Often metastatic at the time of diagnosis.

Treatment: For localized disease, partial or radical nephrectomy is preferred. For metastatic disease, immunotherapy such as nivolumab plus ipilimumab are recommended

Imaging Findings

CT

- Hypodense, metastatic large lesions
- Irregular contours
- Enhancement noted with contrast

MR

- Heterogeneous renal mass
- Low T2 signal intensity

Histology is needed to diagnose sarcomatoid subtype, no differentiating imaging features

References

Morgan M, Glick Y, Deng F, et al. Sarcomatoid renal cell carcinoma. Reference article, Radiopaedia.org (Accessed on April 28th, 2024) <https://doi.org/10.53347/rID-32918>

Bakouny, Z. Choueiri, T.K. Renal cell carcinoma with sarcomatoid features. In: UpToDate, Connor RF (Ed), Wolters Kluwer. (Accessed on April 28th, 2024)

George, D., Jonasch, E. Systemic therapy for advanced and metastatic clear cell renal carcinoma. In: UpToDate, Connor RF (Ed), Wolters Kluwer. (Accessed on April 28th, 2024)