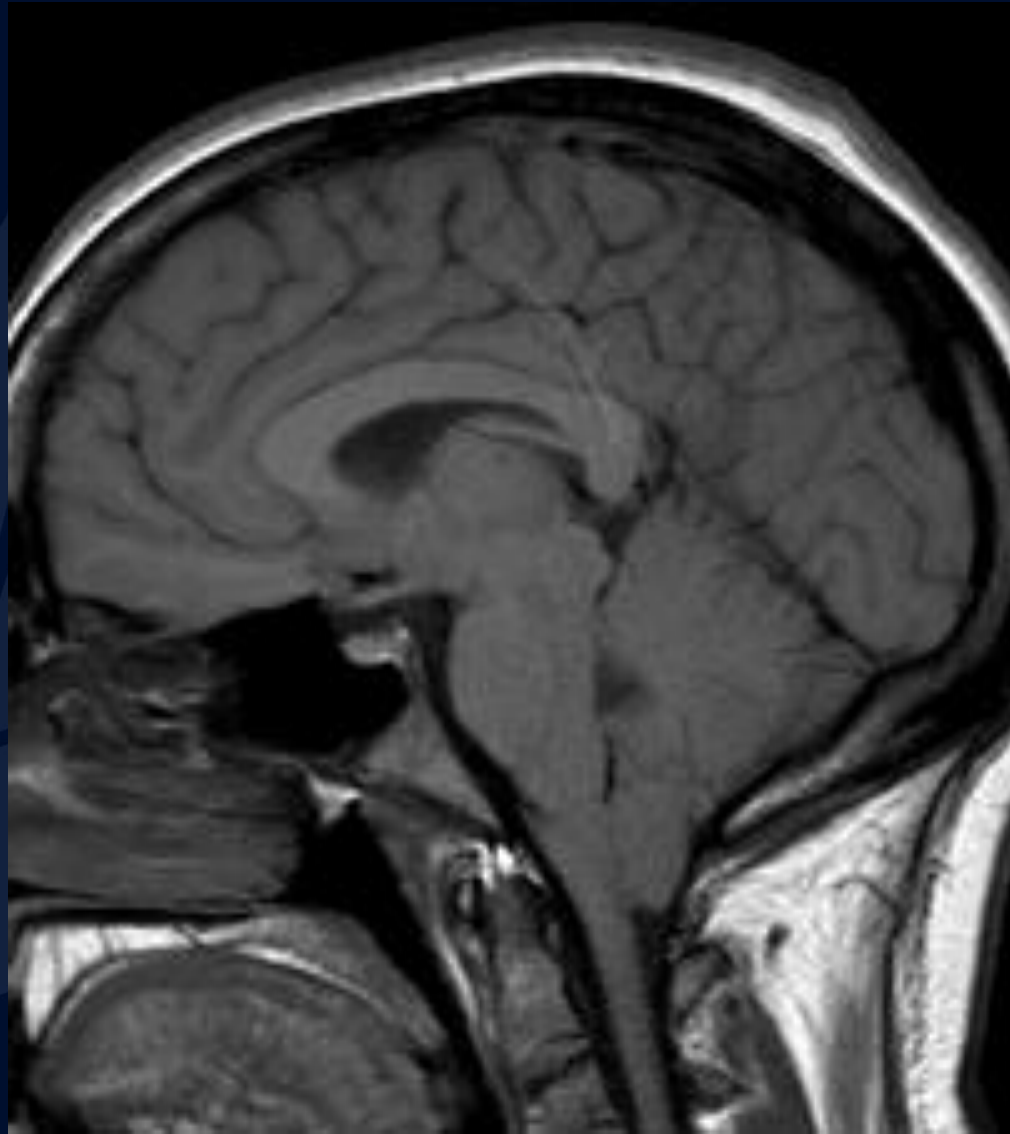


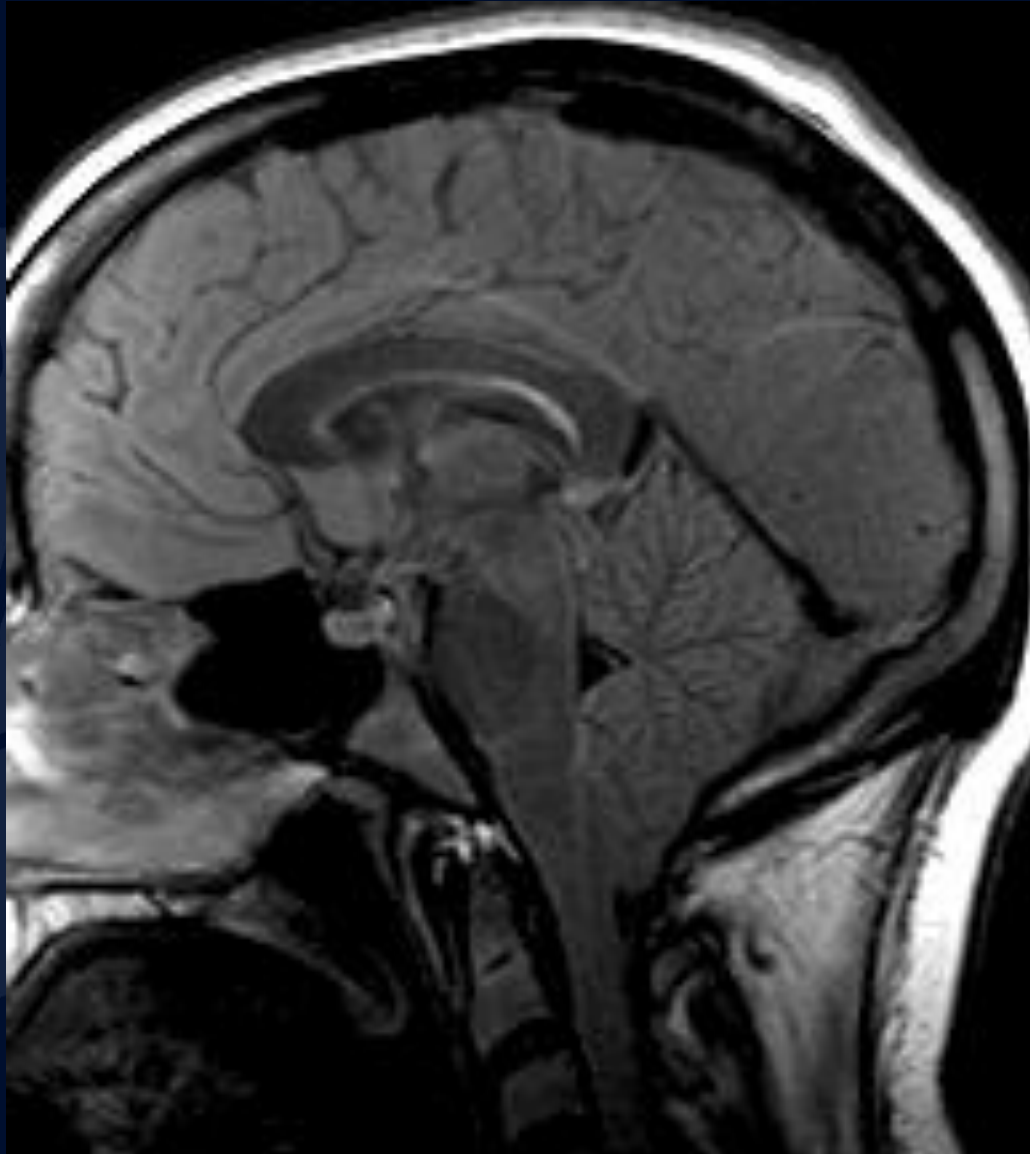
50-year-old female with presenting with headaches and dizziness

Andrew Klufas, MD MBA
Racquel Helsing, MD

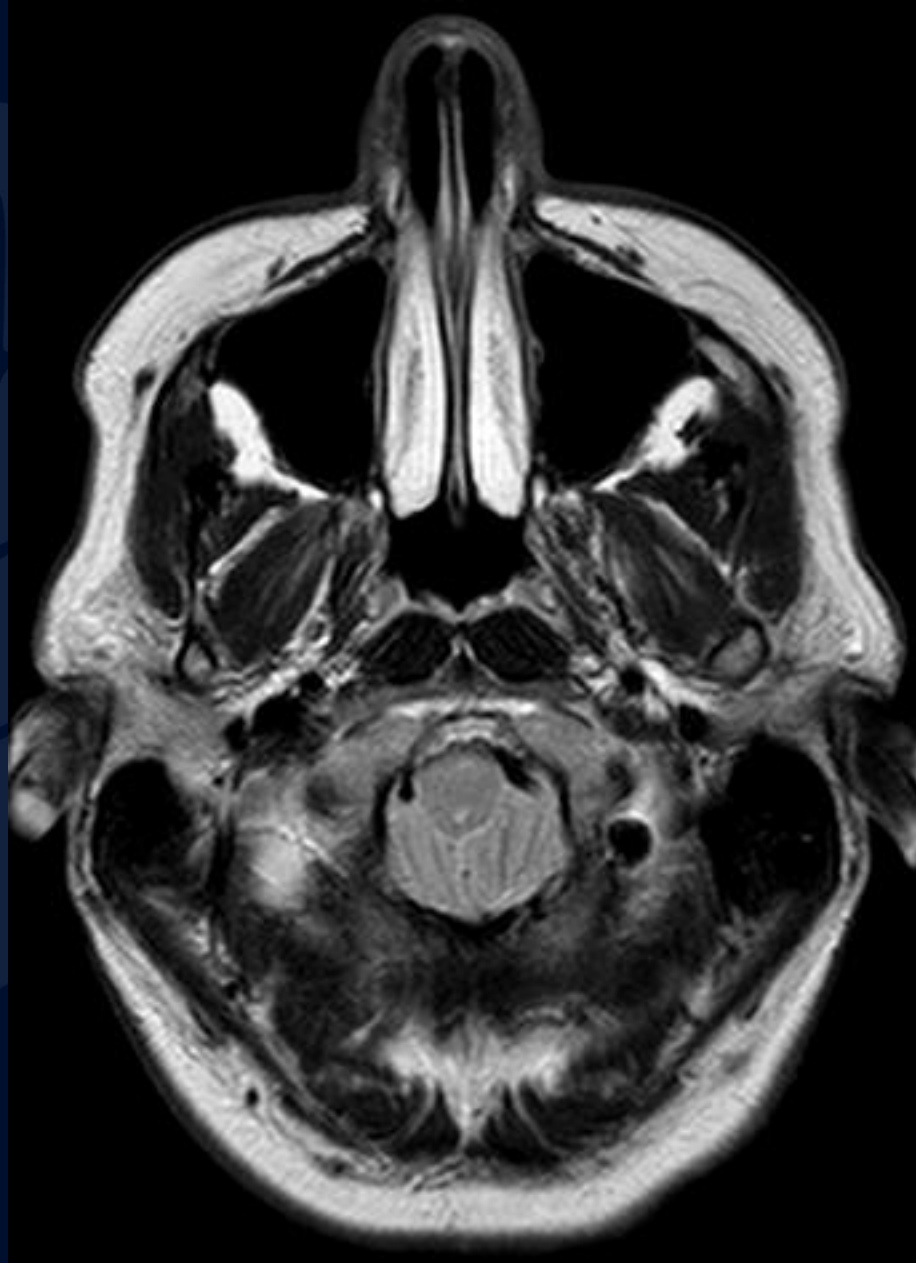
MR T1



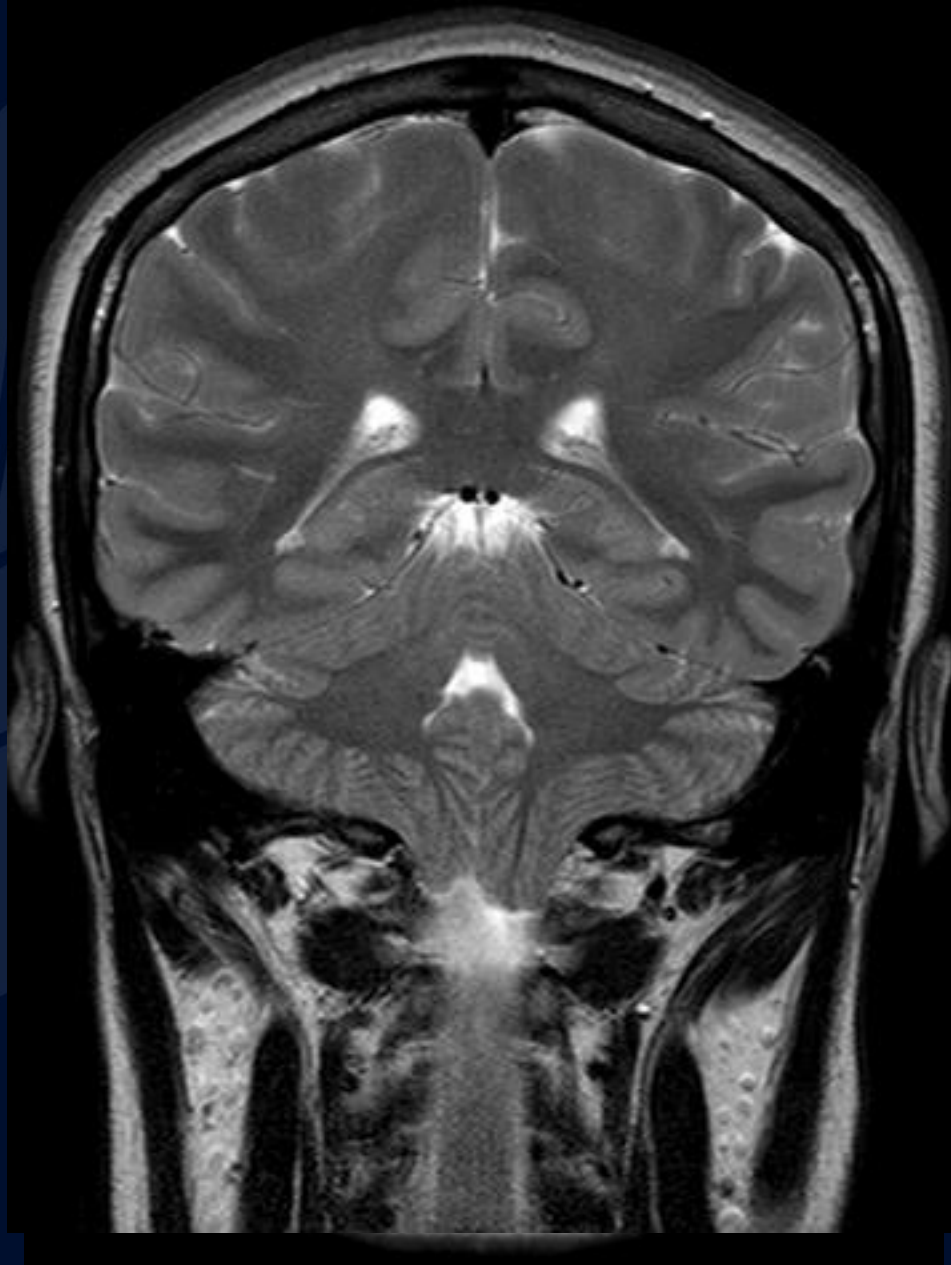
MR FLAIR



MR T2



MR T2

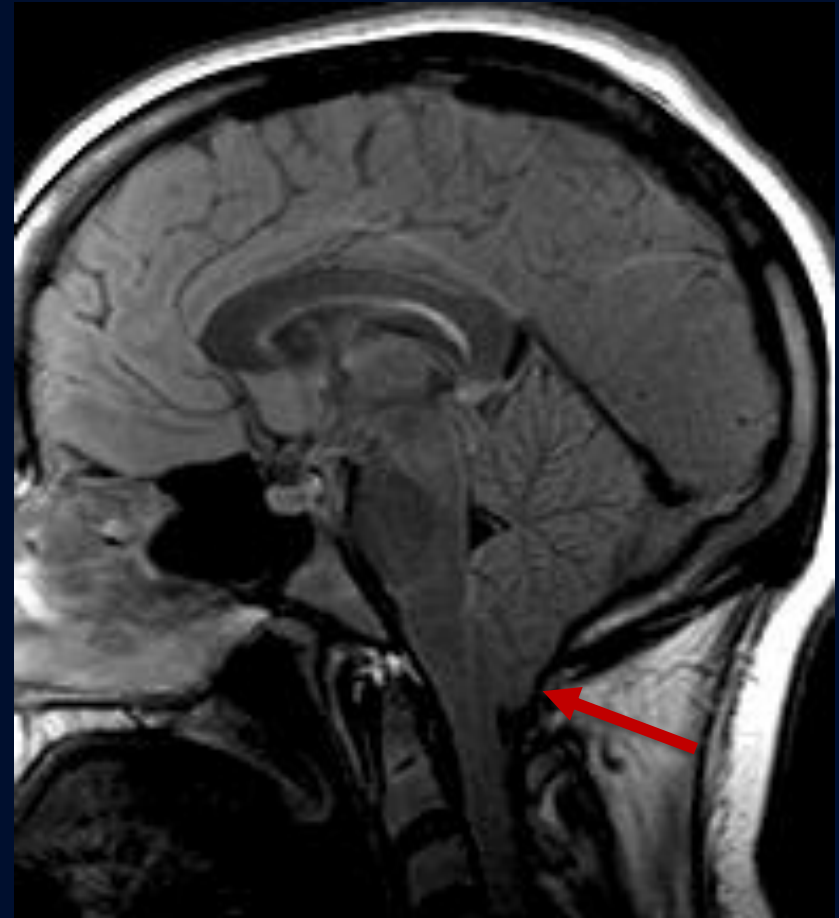
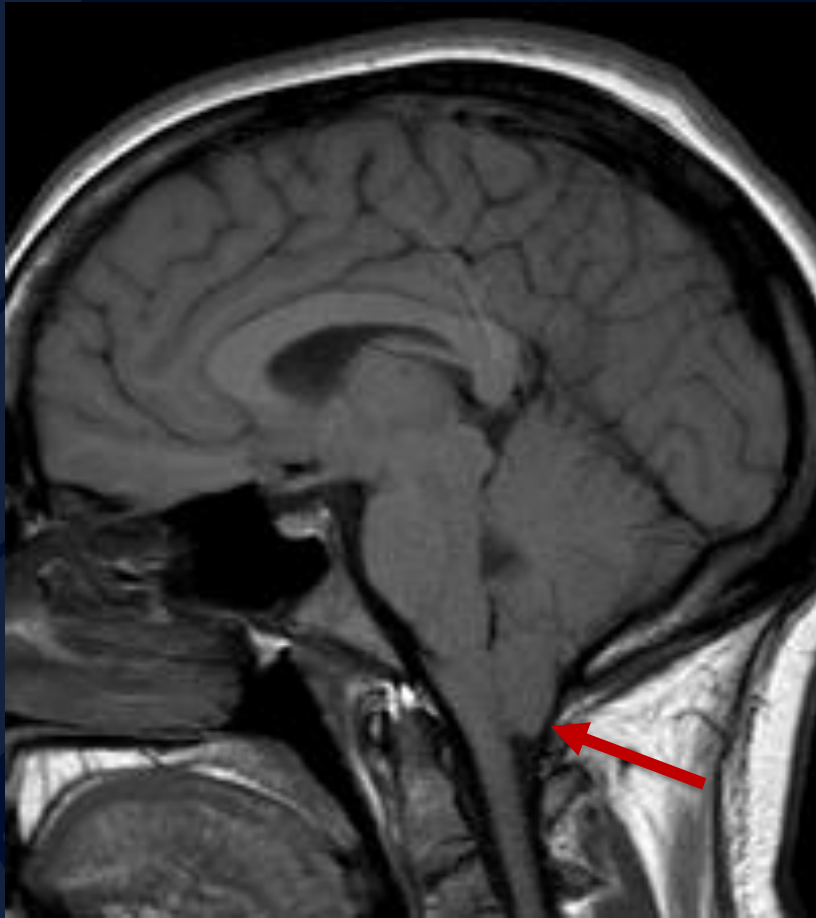




Chiari 1 Malformation

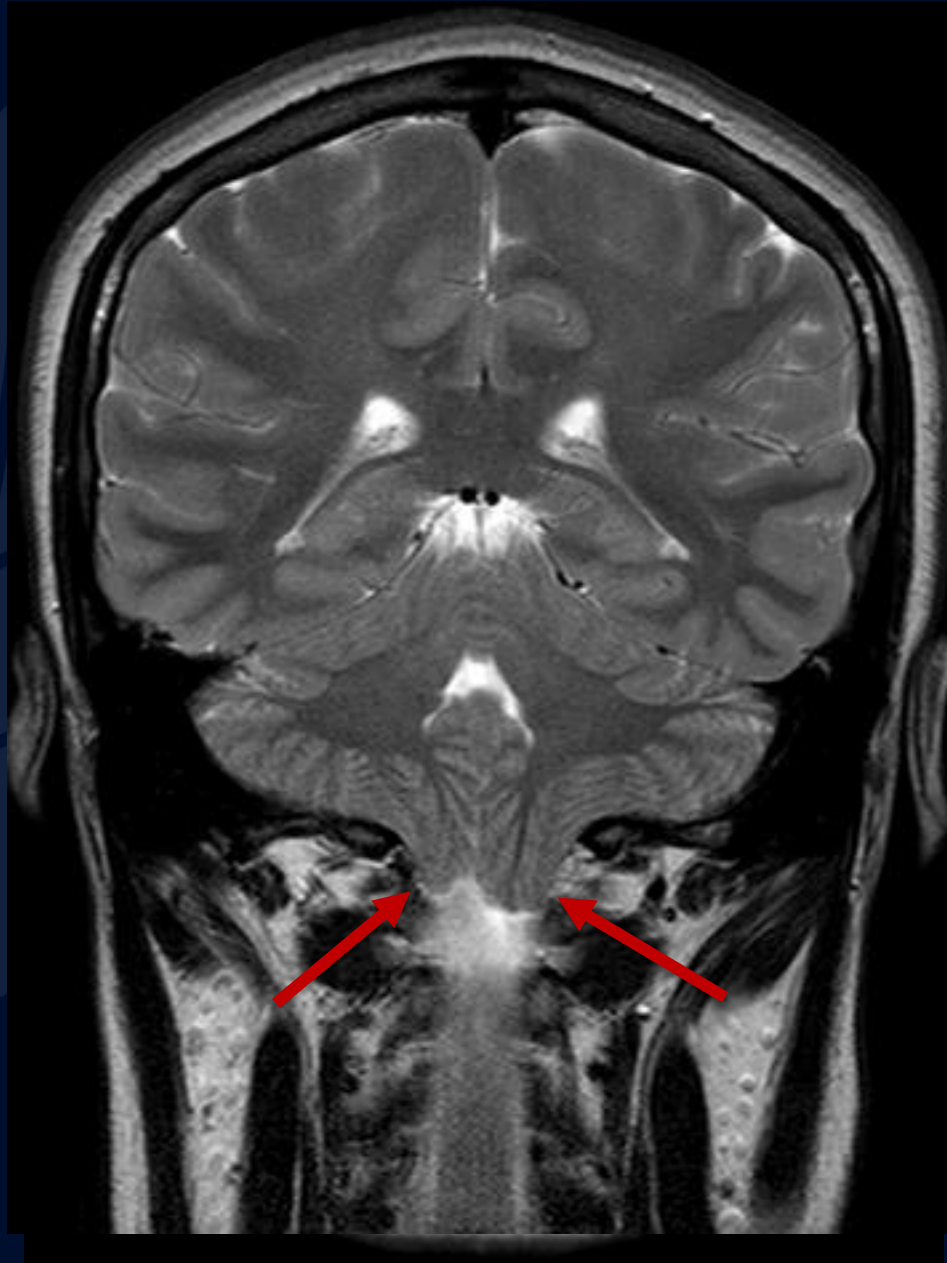
T1

FLAIR



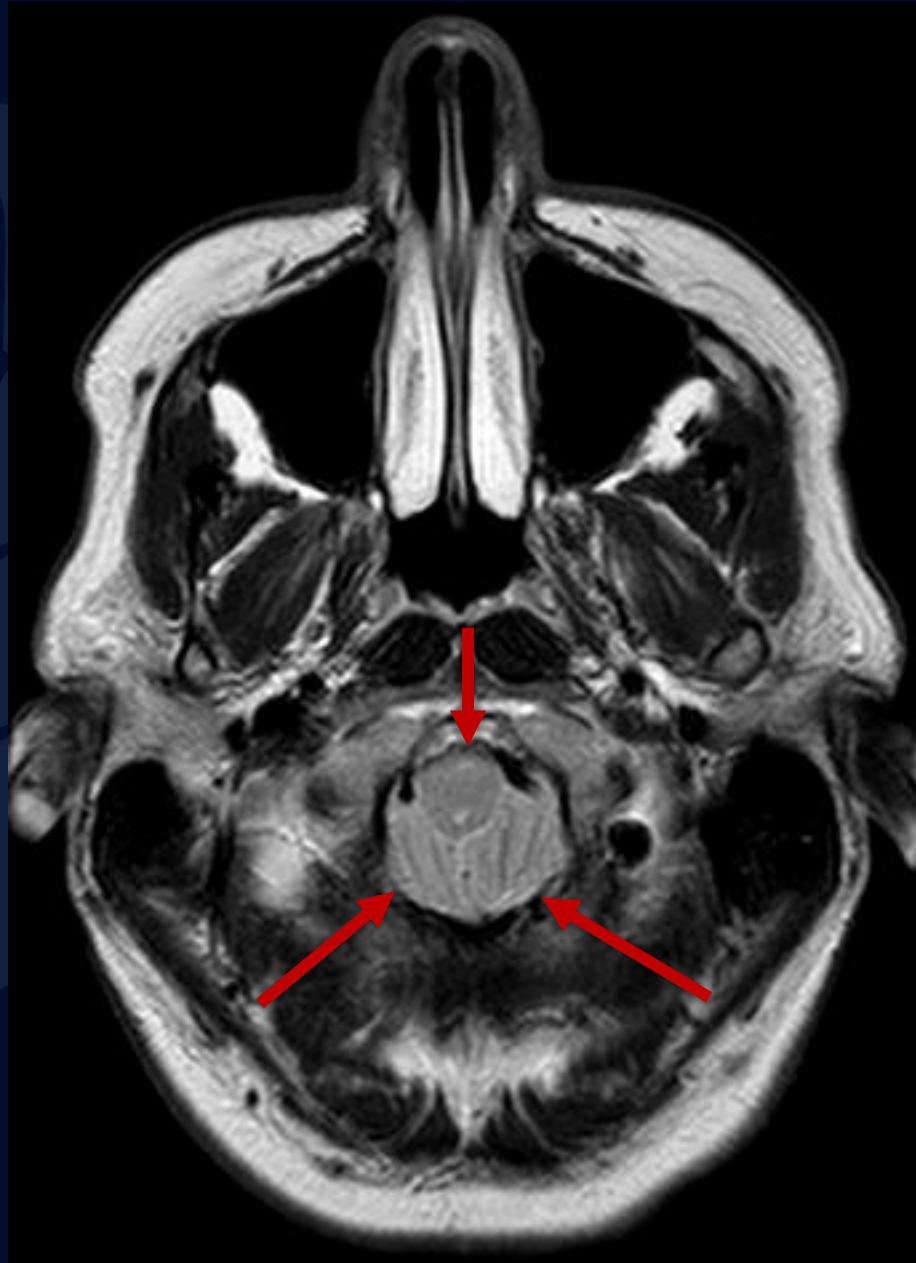Pointed cerebellar tonsils herniating
through the foramen magnum

MR T2



Pointed cerebellar
tonsils herniating
through the
foramen magnum

MR T2



Cerebellar tonsils
herniating through
the foramen
magnum with
crowding

Chiari I Malformation

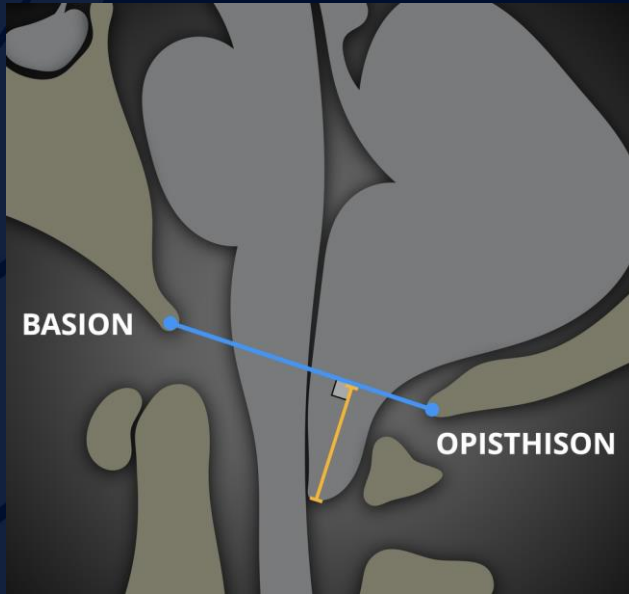
Clinical Presentation: Typically asymptomatic, may present with headache, dizziness, weakness, and other symptoms related to brainstem compression

Features: Abnormal skull base (i.e. a short clivus), cervical segmentation anomalies, small cranial vault or posterior fossa, excessive brain tissue

Associations

- Cervical Cord Syring (~35%)
- Hydrocephalus (~10%)
- Skeletal abnormalities (i.e. basilar invagination, atlanto-occipital assimilation, or Sprengel deformity)
- Other syndromic associations such as Klippel-Feil Syndrome, Crouzon Syndrome, and Hajdu-Cheney Syndrome

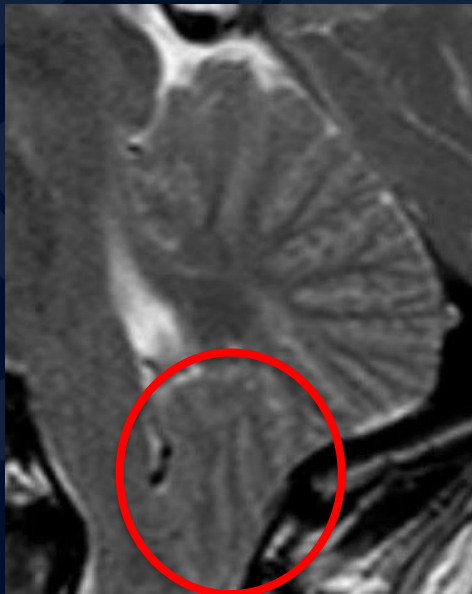
Chiari I Malformation



CT & MRI

– MRI is the modality of choice

- Pointed tonsils
- Cerebellar sulci are vertically oriented, forming “Sergeant Stripes (red circle)”
- Crowding by the cerebellar tonsils



References

Gaillard F, Ranchod A, Yap J, et al. Chiari I malformation. Reference article, Radiopaedia.org (Accessed on 03 Oct 2023) <https://doi.org/10.53347/rID-1111>

Kornienko VN, Pronin IN. Diagnostic Neuroradiology. Springer Verlag. (2008) ISBN:3540756523.

Decq P, Le Guérinel C, Sol JC, Brugières P, Djindjian M, Nguyen JP. Chiari I malformation: a rare cause of noncommunicating hydrocephalus treated by third ventriculostomy. J Neurosurg. 2001 Nov;95(5):783-90. doi: 10.3171/jns.2001.95.5.0783. PMID: 11702868.

Elster AD, Chen MY. Chiari I malformations: clinical and radiologic reappraisal. Radiology. 1992 May;183(2):347-53. doi: 10.1148/radiology.183.2.1561334. PMID: 1561334.