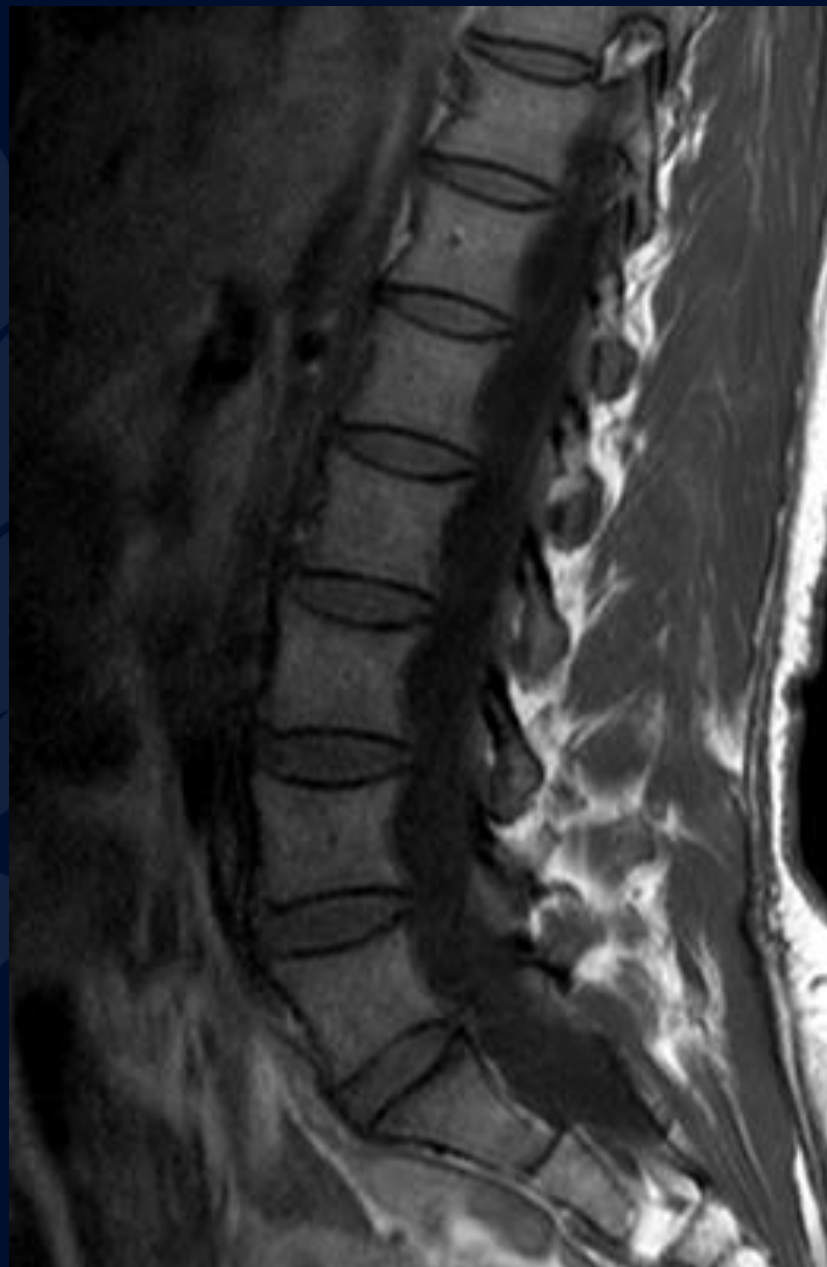


62-year-old female with gradually worsening back pain, leg weakness, and urinary incontinence

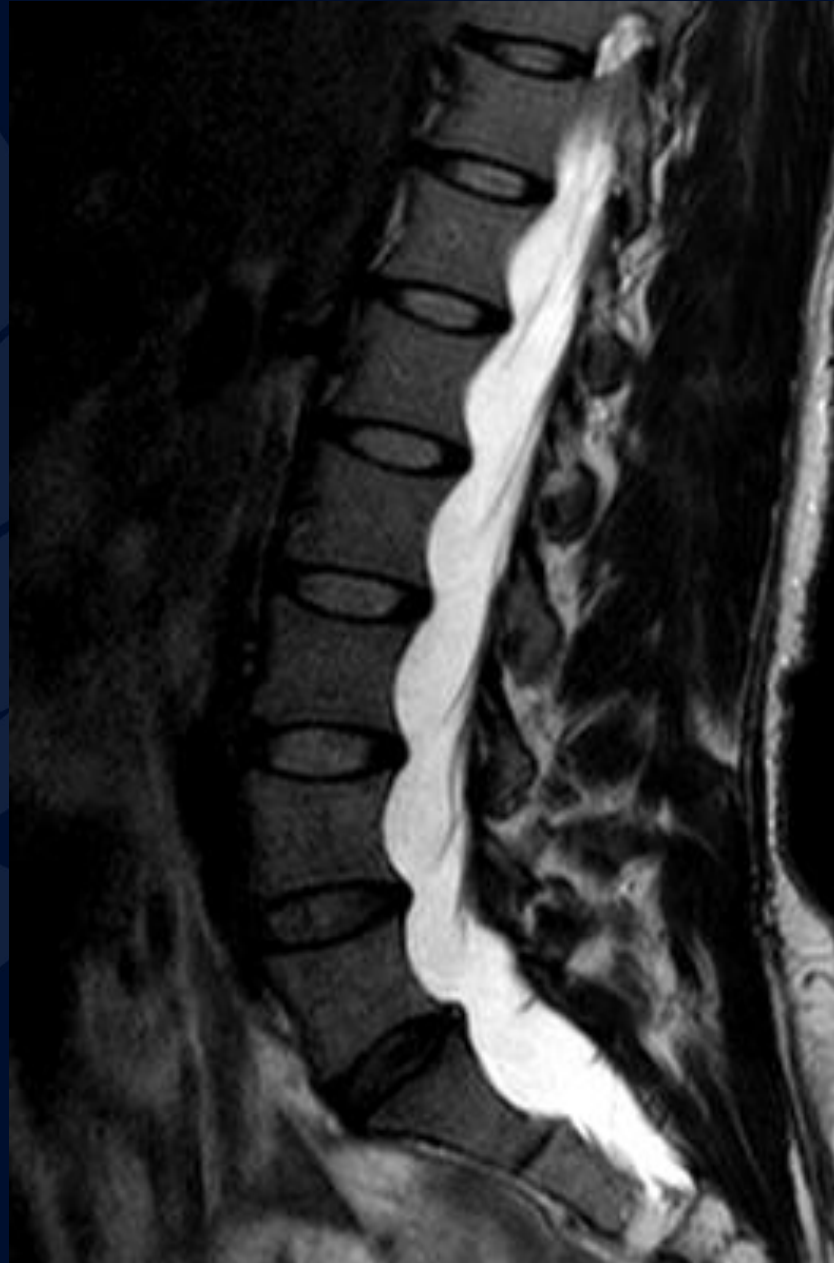Dr. Andrew Klufas, MD MBA

Dr. Leo Wolansky, MD

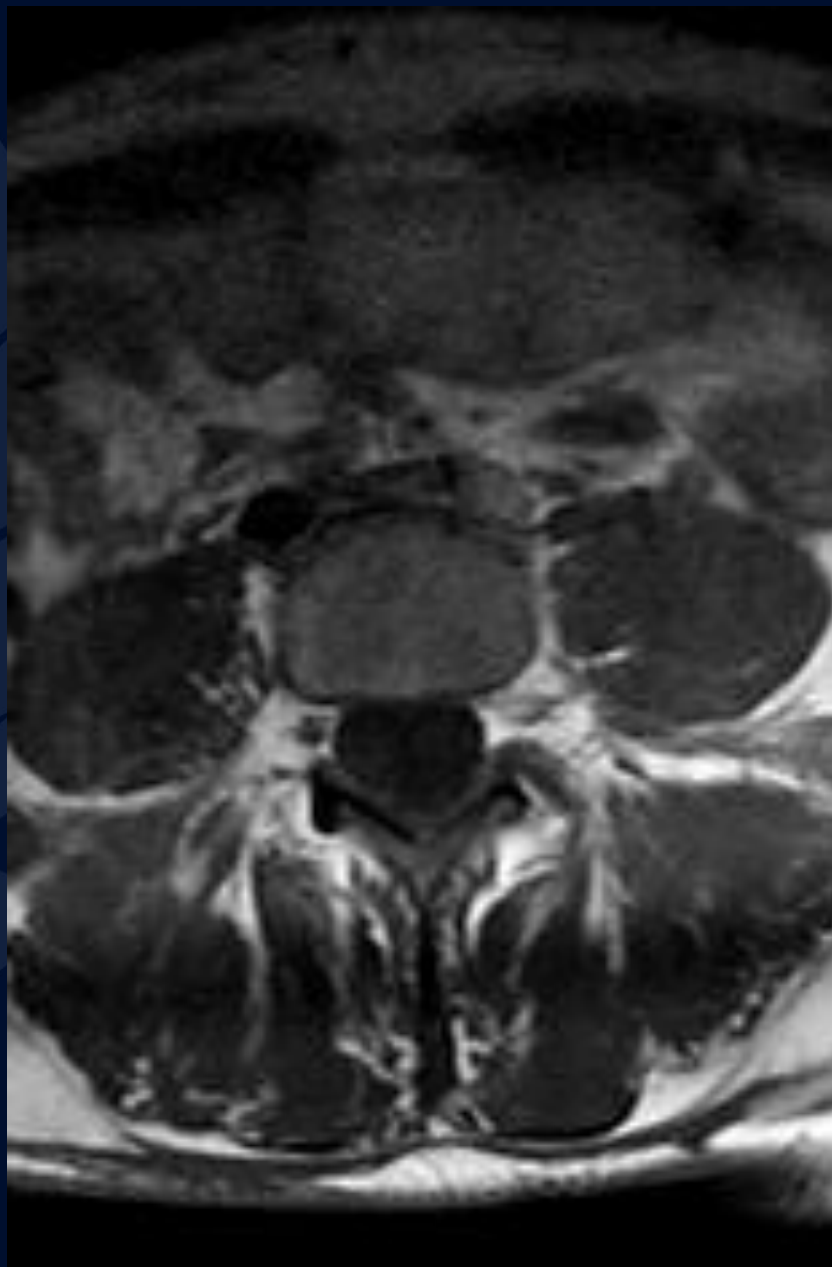
MR T1



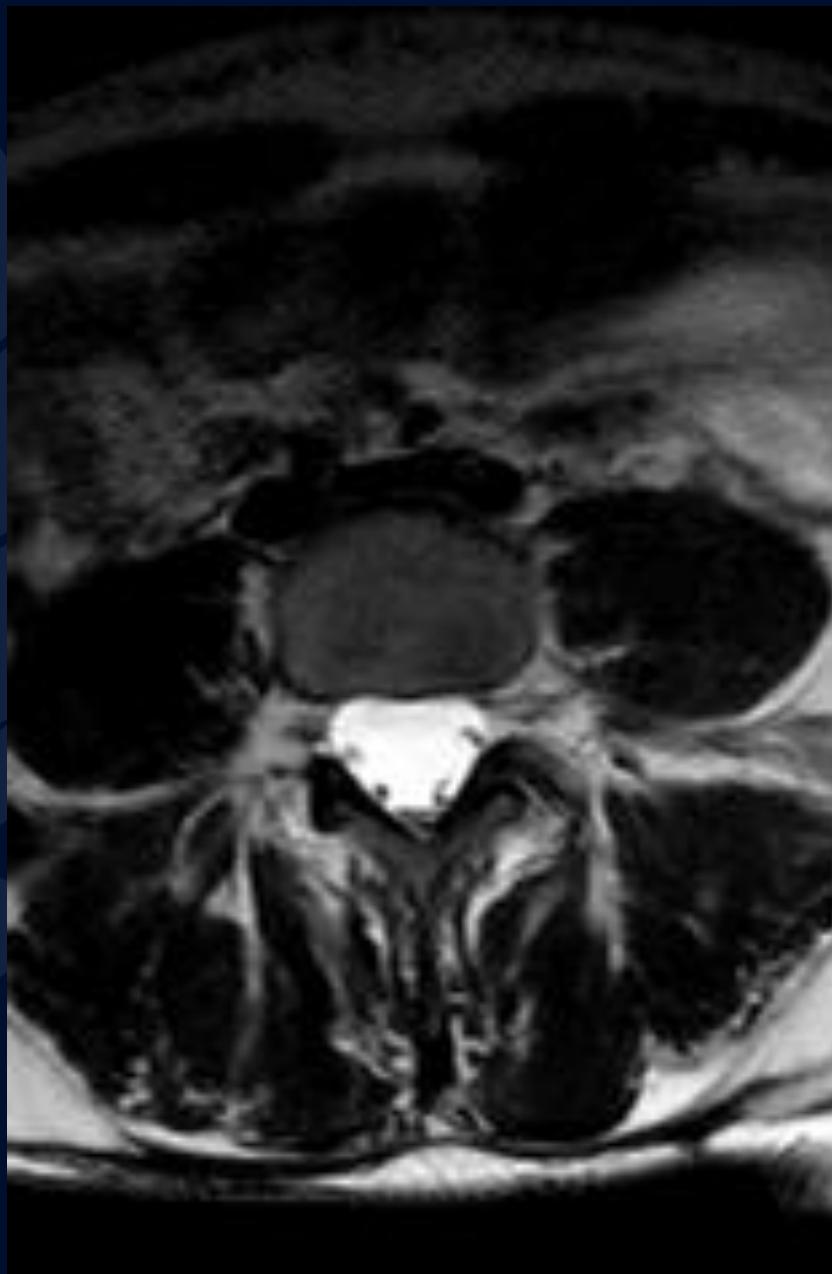
MR T2



MR T1



MR T2



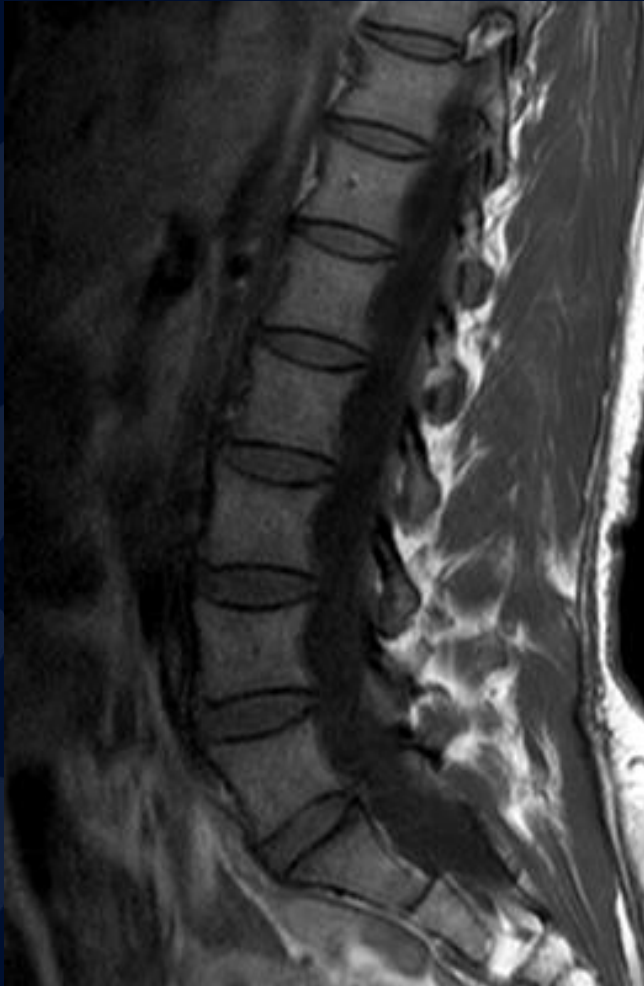

?

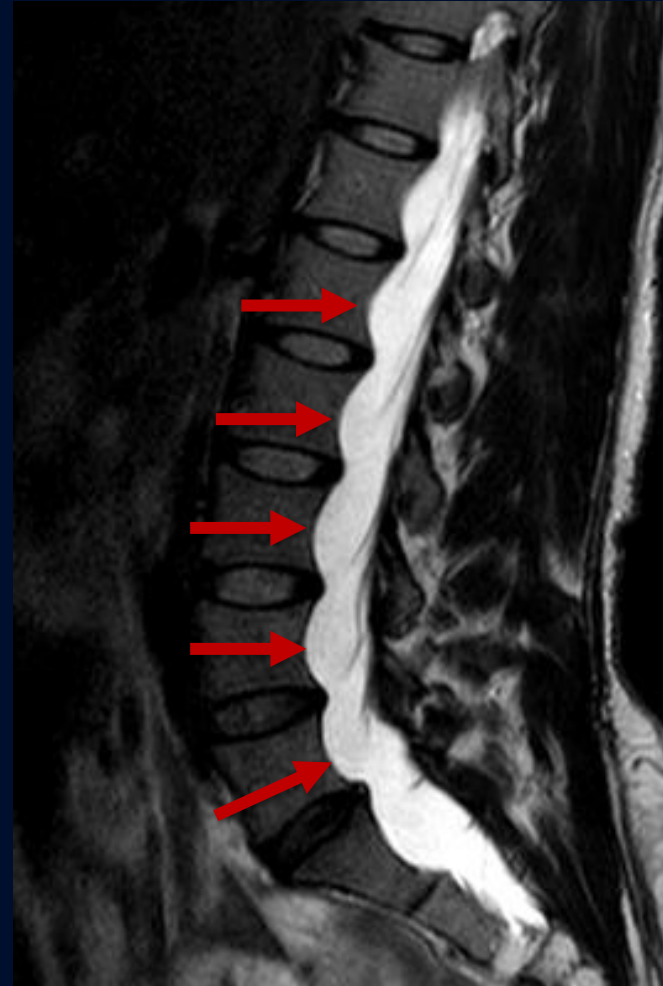
A large, stylized oak leaf graphic in a dark blue color, positioned on the left side of the slide, partially overlapping the title text.

Dural Ectasia

T1

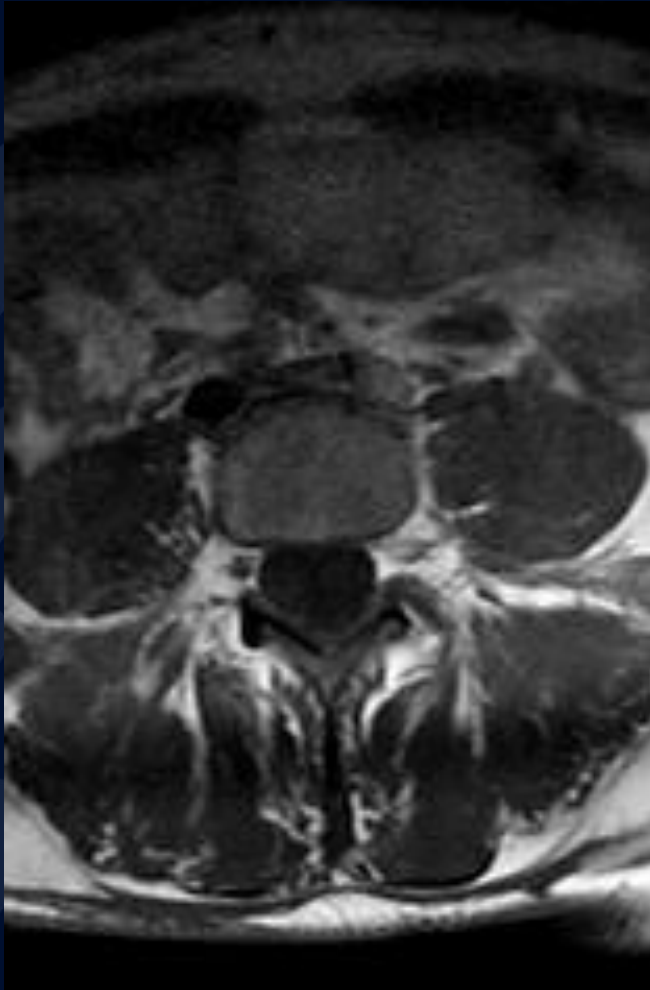


T2

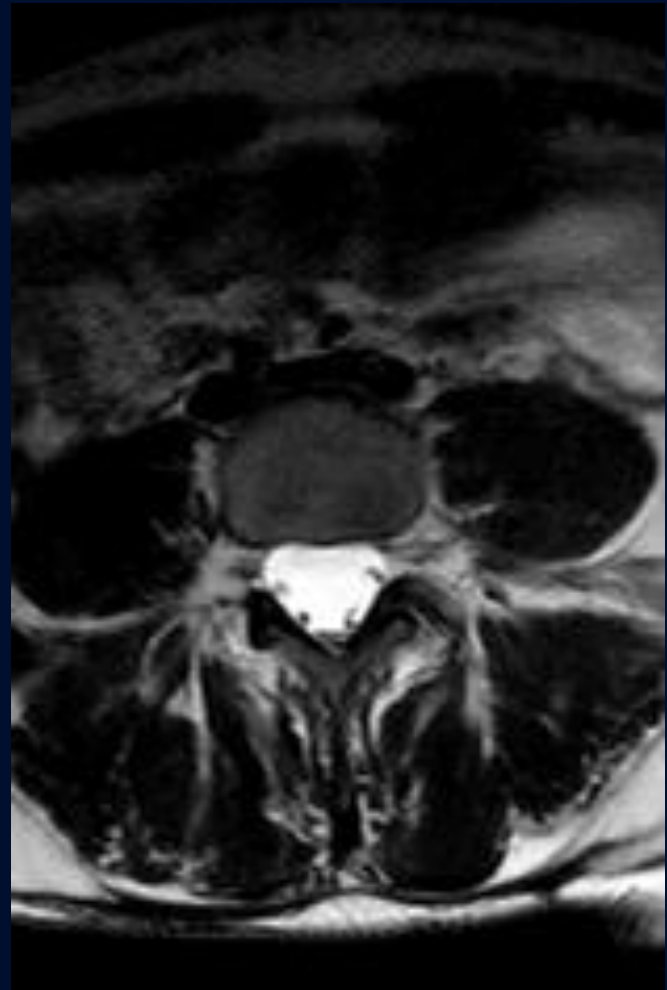

Multilevel vertebral body scalloping without evidence of central or foraminal stenosis or disc herniation

T1



T2



No evidence of central or foraminal stenosis at any level

Dural Ectasia

“Dural Ectasia” refers to widening or ballooning of the dural sac, resulting in vertebral scalloping. It is sometimes associated with nerve root sleeve herniation, although that is not seen in this case.

Clinical Presentation: Often asymptomatic, though may present with low back pain, radicular pain in the buttocks and legs, lower extremity weakness, or urinary incontinence

Associations:

- Connective Tissue Disorders (Marfan, Ehlers-Danlos, Loeys-Dietz)
- Neurofibromatosis Type 1
- Cauda Equina Syndrome
- Ankylosing Spondylitis
- Osteogenesis Imperfecta
- Acromegaly

Imaging Findings

Plain Radiograph

- Posterior vertebral scalloping on lateral view can be seen, but is not specific for this diagnosis

MRI:

- T1: Difficult to distinguish due to hypointensity of CSF on this sequence
- T2: Increase in anteroposterior diameter of dural sac, often in lumbar region

References

Weerakkody Y, Bickle I, El-Feky M, et al. Dural ectasia. Reference article, Radiopaedia.org (Accessed on 25 Sep 2023) <https://doi.org/10.53347/rID-7832>

Habermann CR, Weiss F, Schoder V, Cramer MC, Kemper J, Wittkugel O, Adam G. MR evaluation of dural ectasia in Marfan syndrome: reassessment of the established criteria in children, adolescents, and young adults. *Radiology*. 2005 Feb;234(2):535-41. doi: 10.1148/radiol.2342031497. Epub 2004 Dec 22. PMID: 15616116.

Lundby R, Rand-Hendriksen S, Hald JK, Lilleås FG, Pripp AH, Skaar S, Paus B, Geiran O, Smith HJ. Dural ectasia in Marfan syndrome: a case control study. *AJNR Am J Neuroradiol*. 2009 Sep;30(8):1534-40. doi: 10.3174/ajnr.A1620. Epub 2009 May 20. PMID: 19461064; PMCID: PMC7051621.