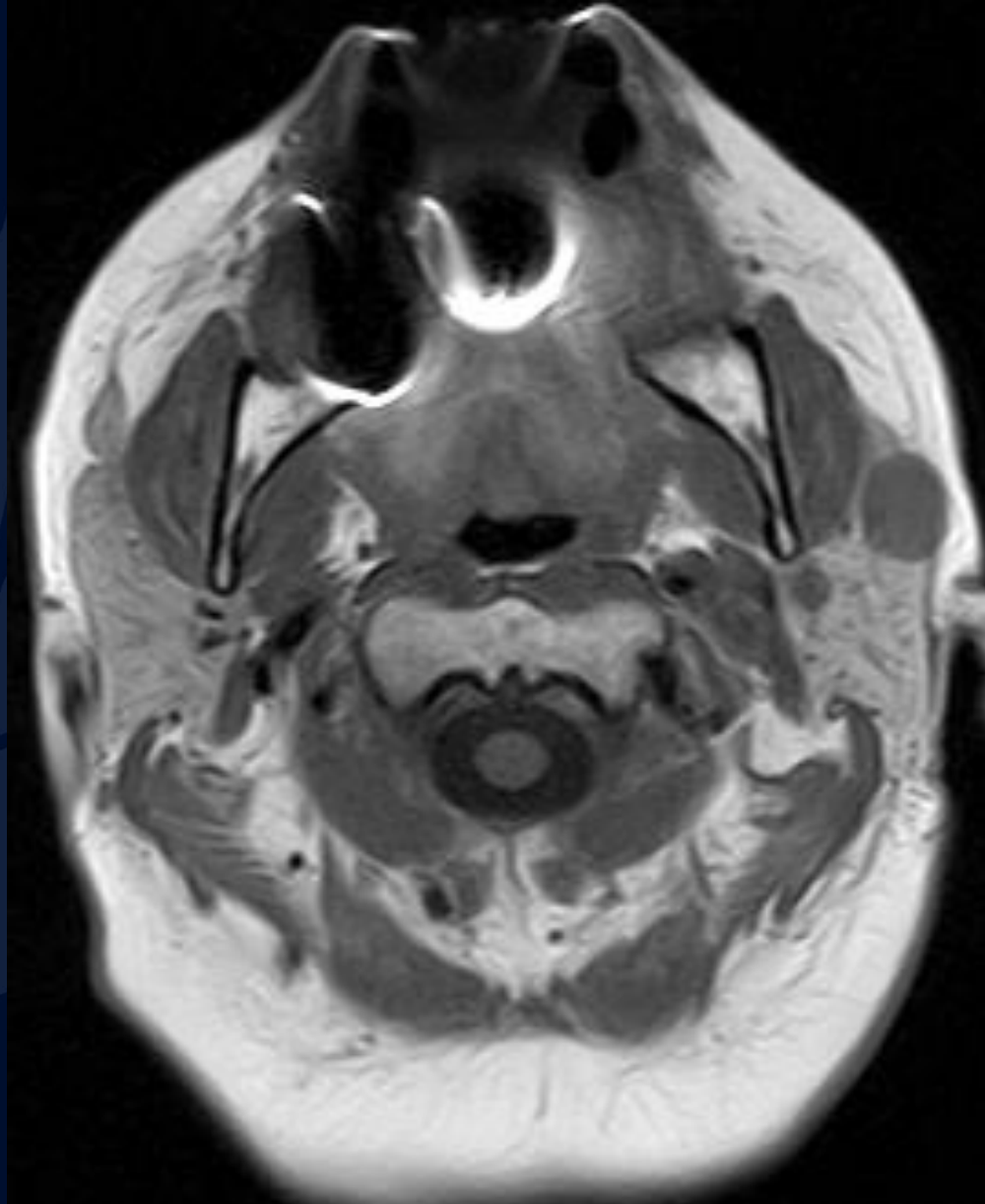


45-year-old male presenting with
a smooth, painless, enlarging
facial mass

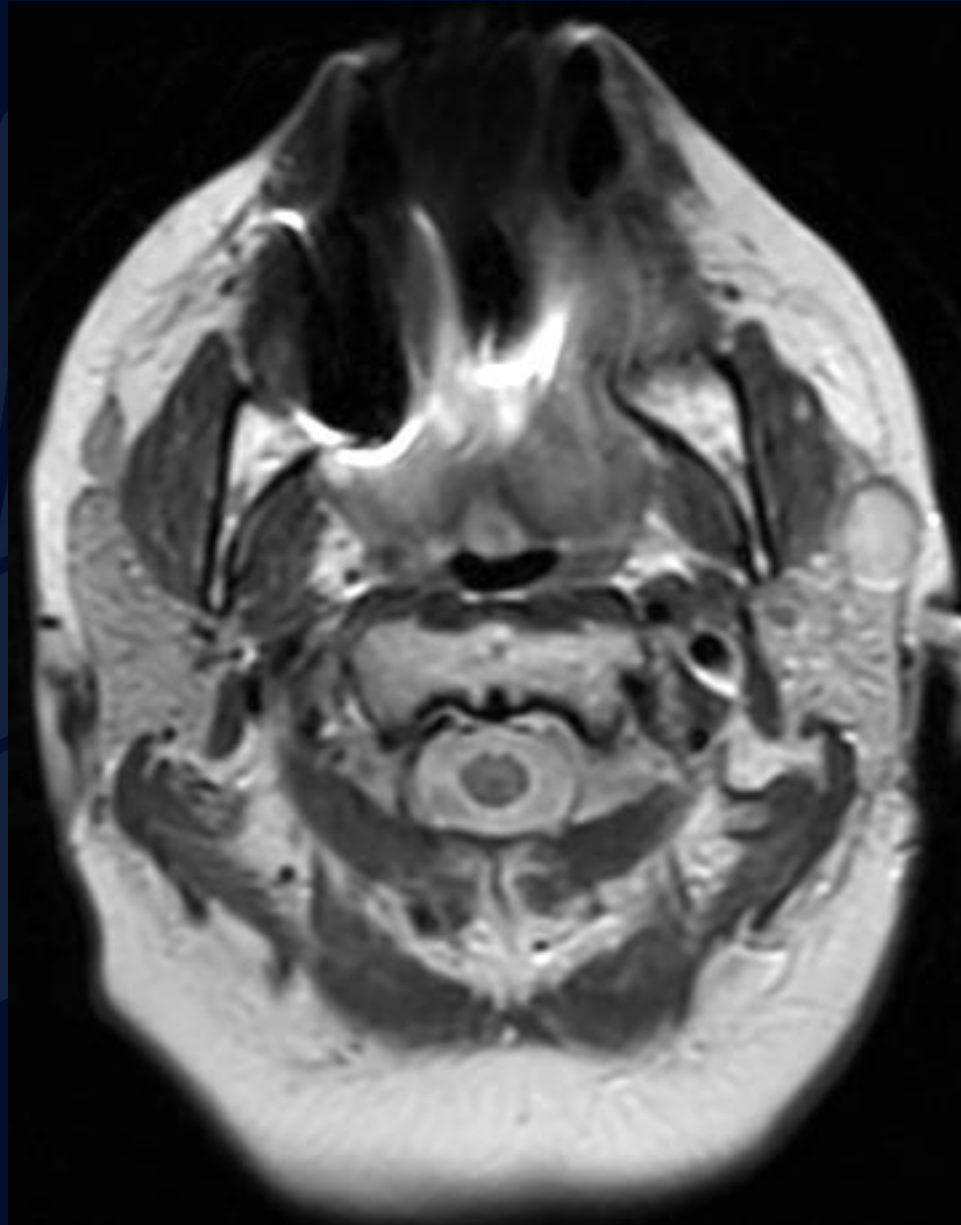
Andrew Klufas, MD, MBA

Leo Wolansky, MD

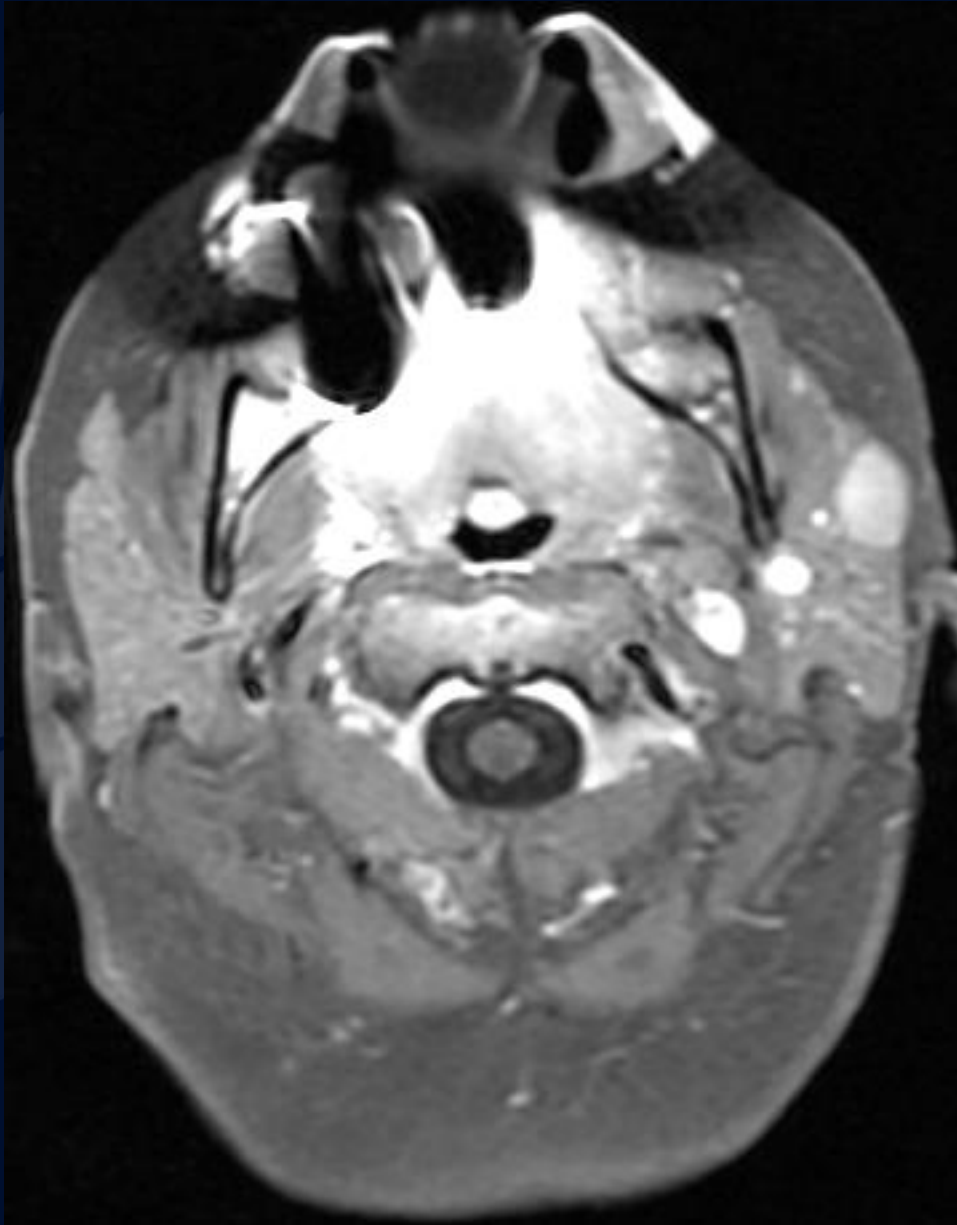
MR T1



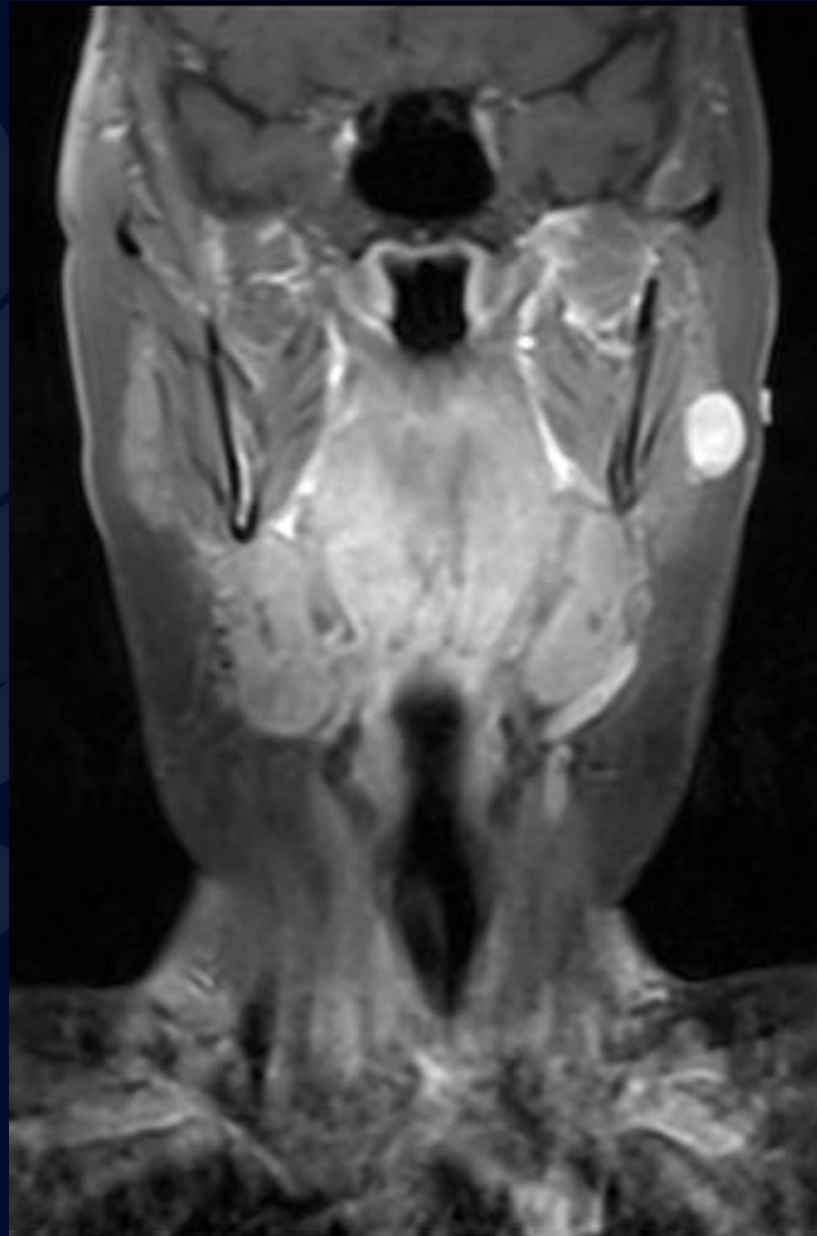
MR T2



MR T1 + Gad



MR T1 + Gad



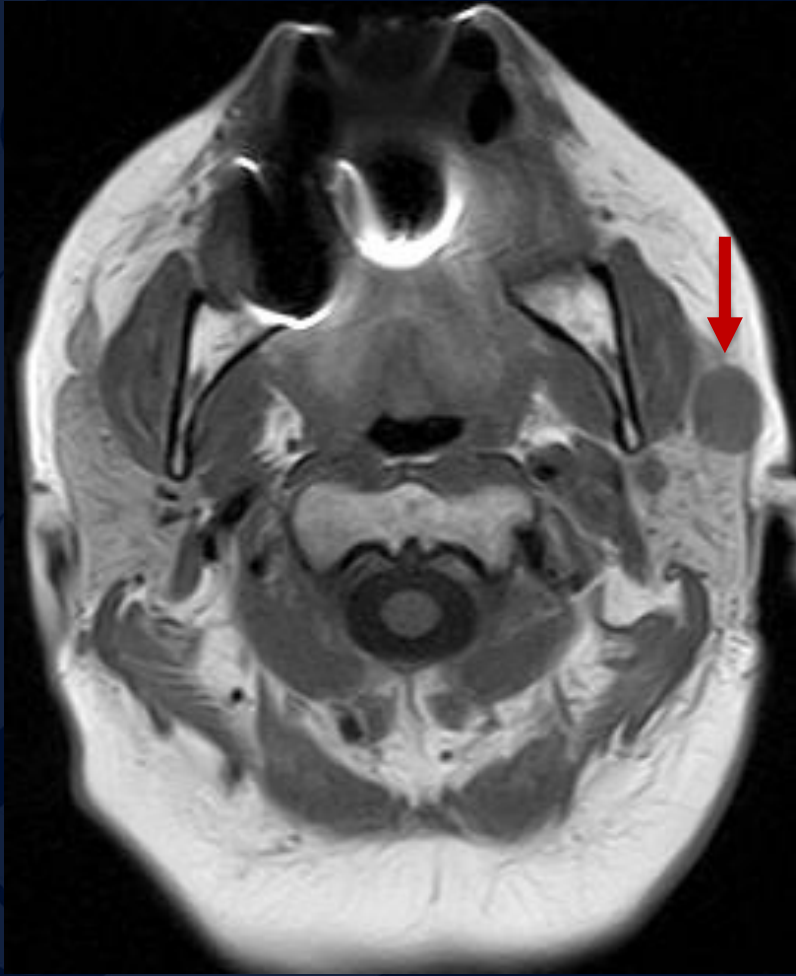


?

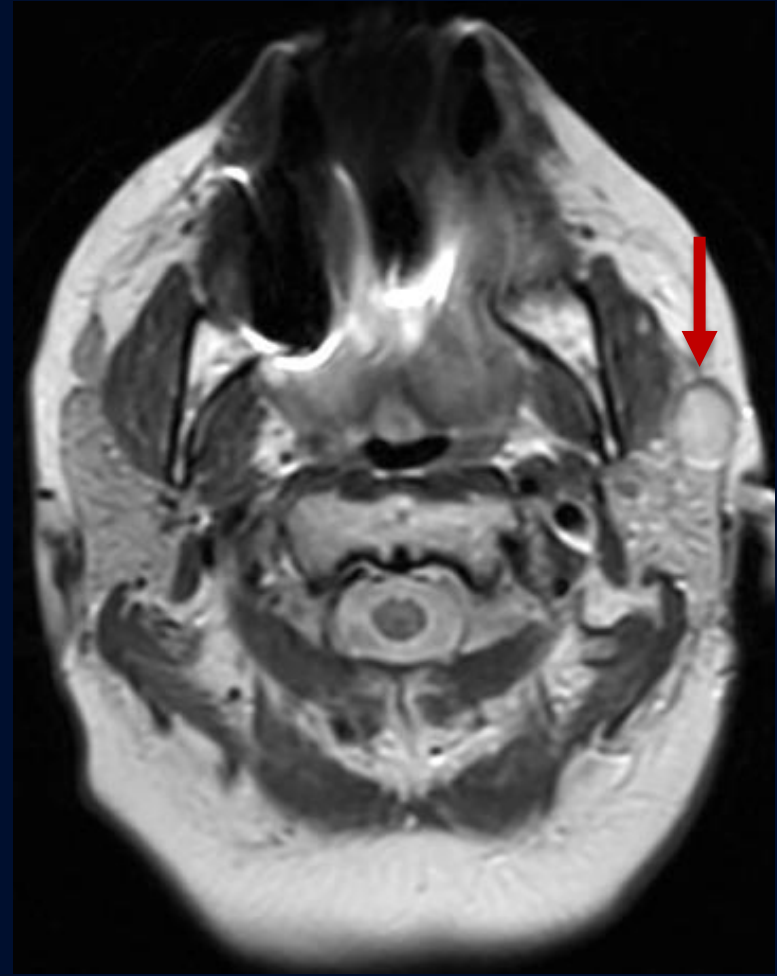
A large, stylized oak leaf graphic in a dark blue color, positioned on the left side of the slide. The leaf has a prominent central vein and several smaller veins branching off, with a serrated edge.

Parotid Pleomorphic Adenoma

T1



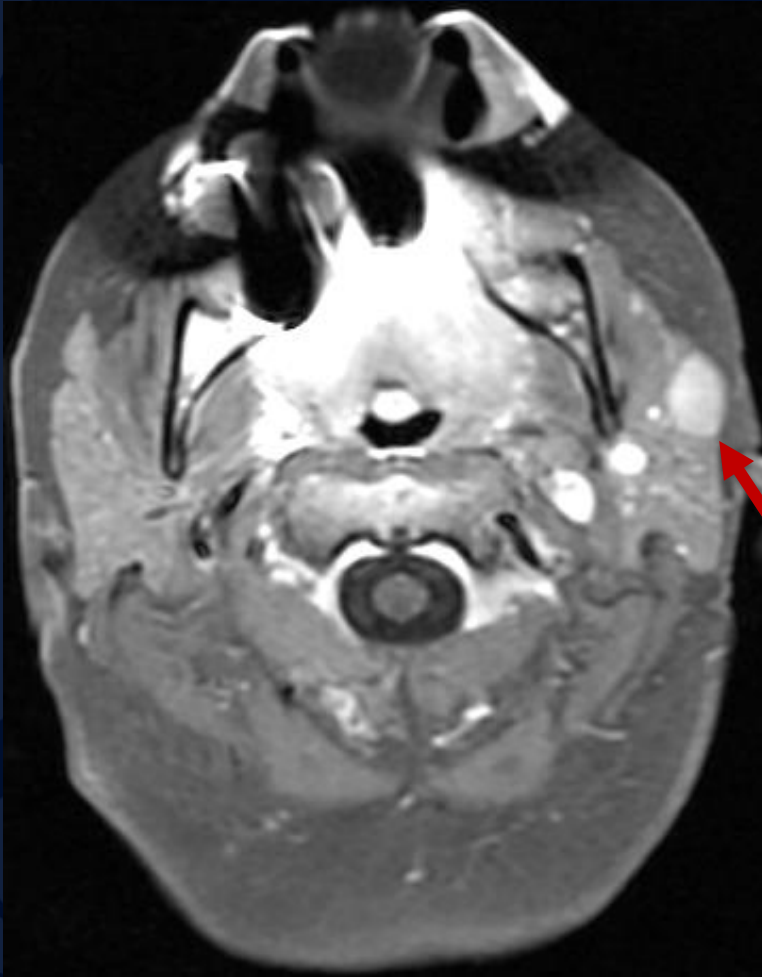
T2



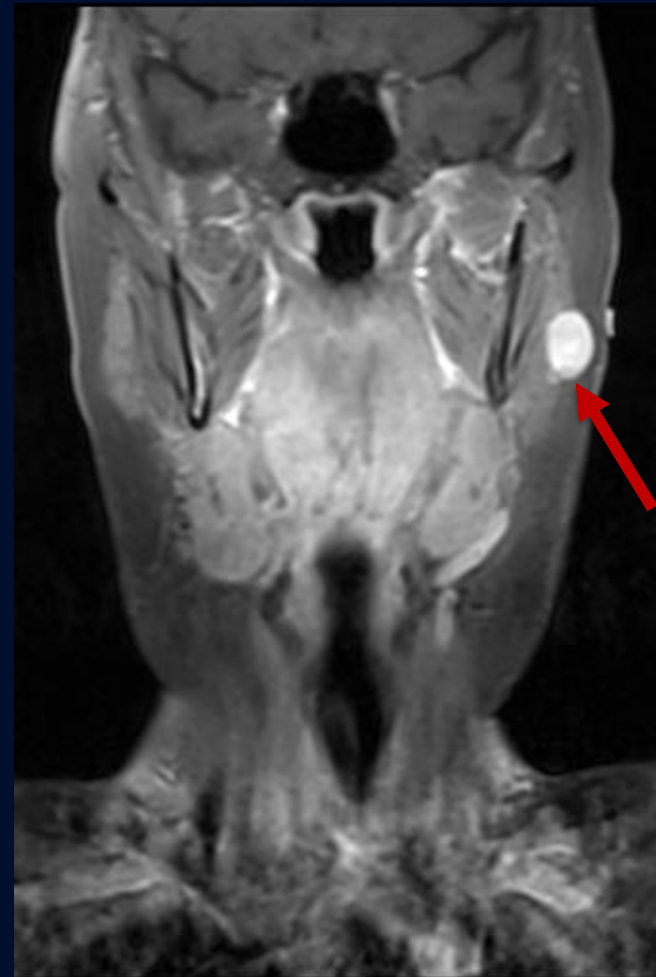
T1 hypointense

T2 hyperintense

T1 + Gad



T1 + Gad



Homogenously enhancing left parotid mass

Parotid Pleomorphic Adenoma

Clinical Presentation

- Often benign and asymptomatic, with patients incidentally noting a smooth, painless, enlarging mass.

Location

- Parotid Gland (84%)
- Submandibular Gland (8%)
- Minor Salivary Glands (6.5%)
- Sublingual Glands (0.5%)

Differential Diagnosis

- Warthin tumor
- Non-Hodgkin Lymphoma
- Adenoid Cystic Carcinoma
- Mucoepidermoid Carcinoma
- Parotid Nodal Metastasis

Imaging Findings

Ultrasound

- Typically hypoechoic, with posterior acoustic enhancement

CT

- Homogenous attenuation and prominent enhancement with smaller lesions
- Heterogenous appearance and less prominent enhancement with larger lesions

MRI

- T1: Usually low intensity
- T1 + Gad: Homogenous enhancement
- T2: High intensity with low intensity peripheral rim representing a fibrous capsule

References

Gaillard F, Ranchod A, Feger J, et al. Pleomorphic adenoma of the salivary glands. Reference article, Radiopaedia.org (Accessed on 25 Sep 2023) <https://doi.org/10.53347/rID-1893>

Thoeny HC. Imaging of salivary gland tumours. *Cancer Imaging*. 2007 Apr 30;7(1):52-62. doi: 10.1102/1470-7330.2007.0008. PMID: 17485257; PMCID: PMC1866314.

Moonis G, Patel P, Koshkareva Y, Newman J, Loevner LA. Imaging characteristics of recurrent pleomorphic adenoma of the parotid gland. *AJNR Am J Neuroradiol*. 2007 Sep;28(8):1532-6. doi: 10.3174/ajnr.A0598. PMID: 17846206; PMCID: PMC8134383.

Lev MH, Khanduja K, Morris PP, Curtin HD. Parotid pleomorphic adenomas: delayed CT enhancement. *AJNR Am J Neuroradiol*. 1998 Nov-Dec;19(10):1835-9. PMID: 9874532; PMCID: PMC8337714.