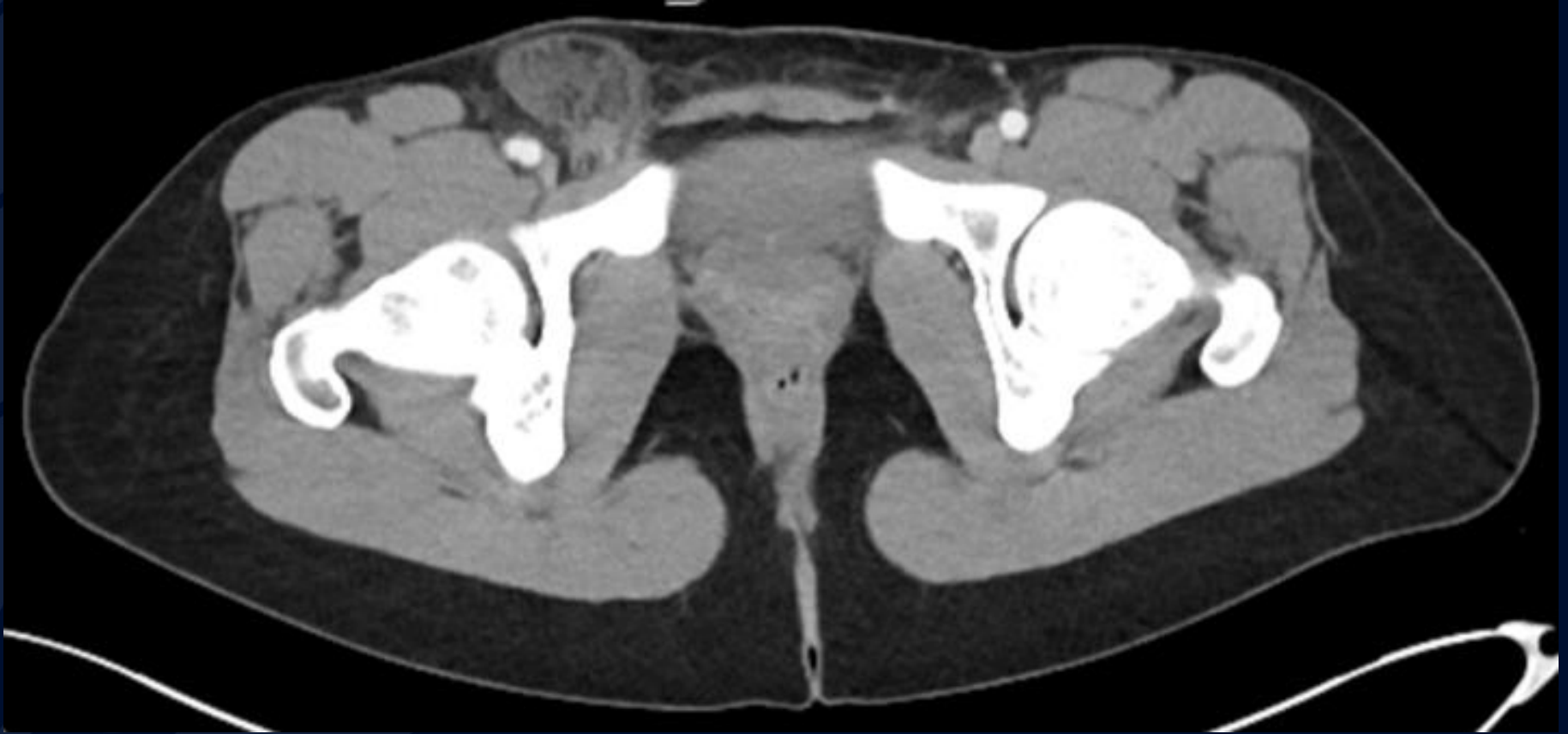

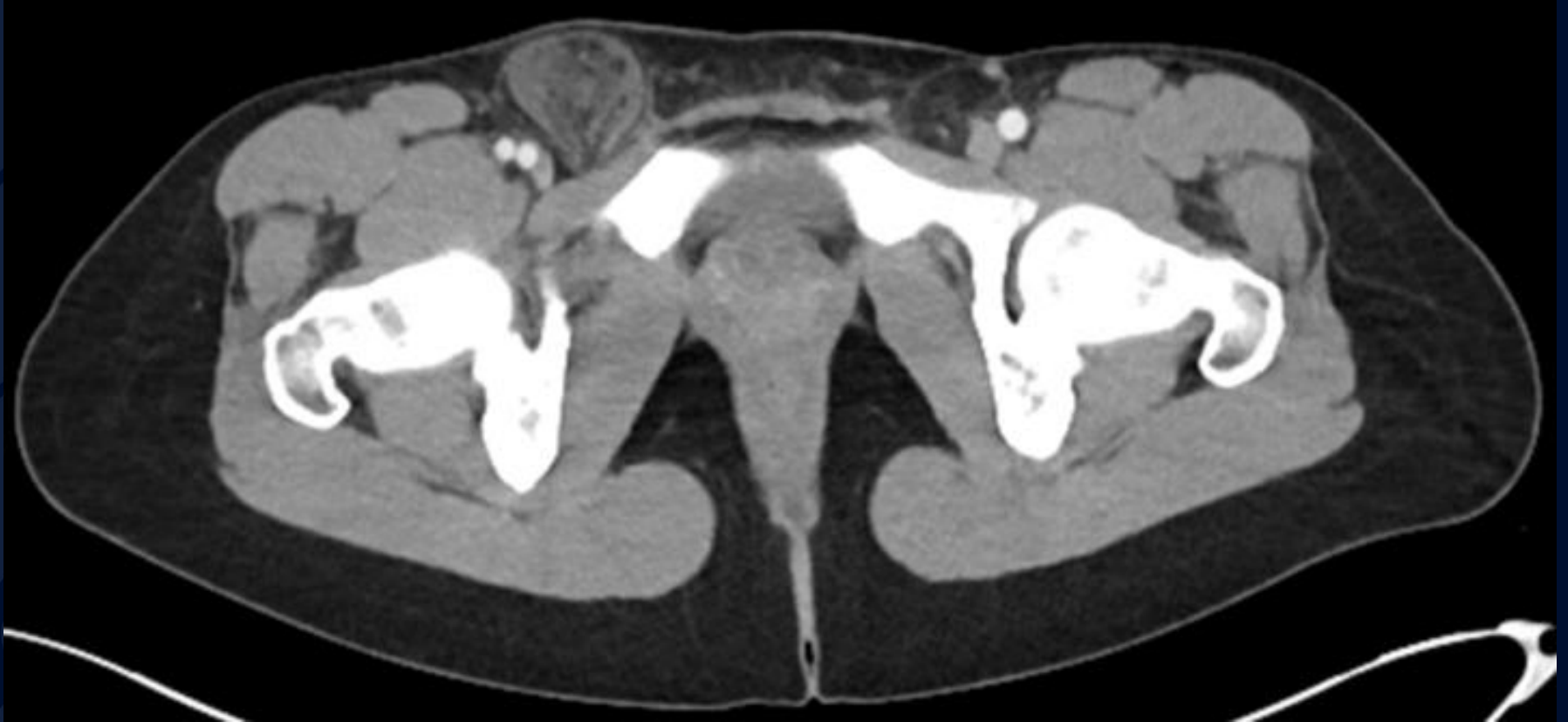# 34-year-old female with a nontender palpable right groin mass

Joseph Ryan, MD, PhD  
Carlos Badiola, MD, JD

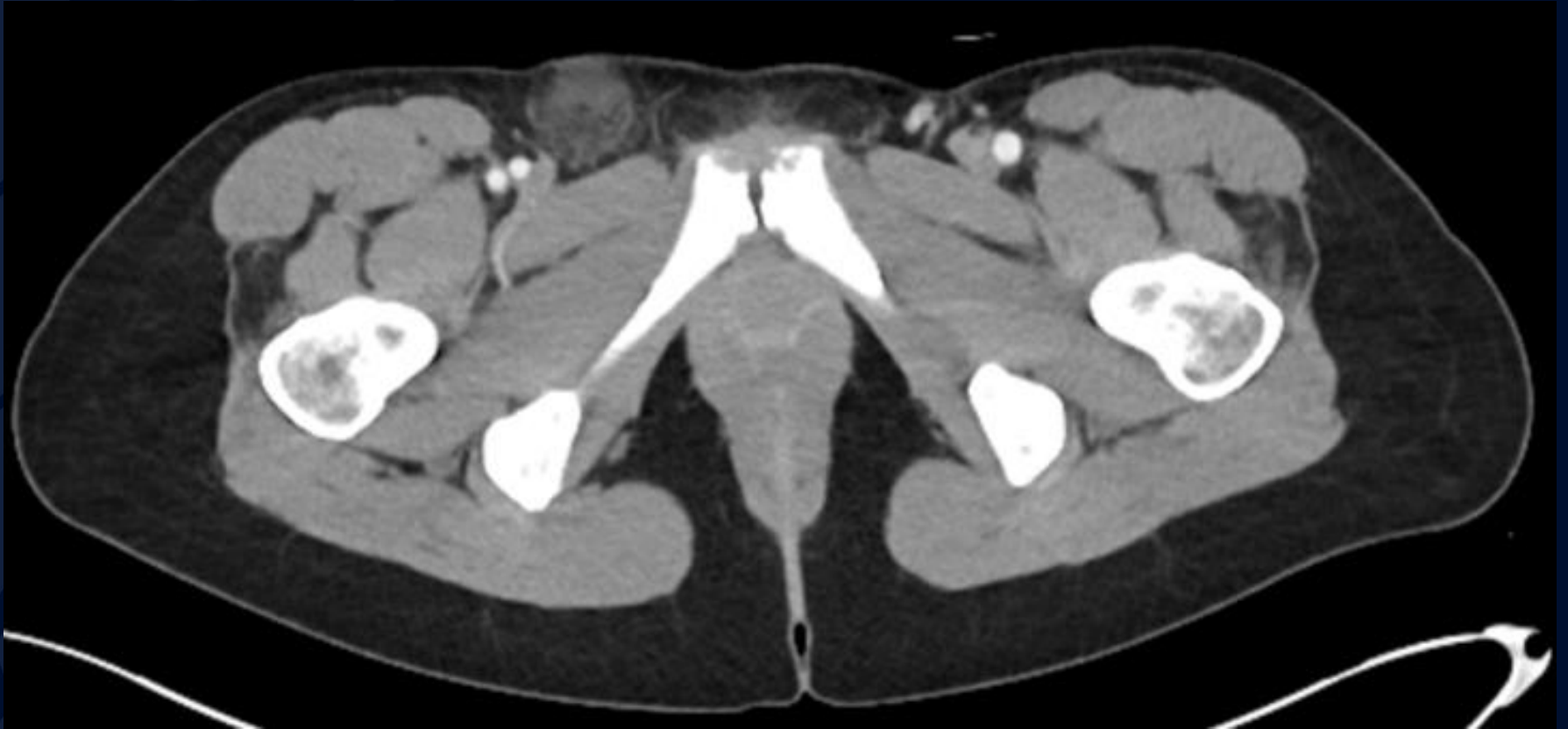# CT abdomen and pelvis with oral & IV contrast



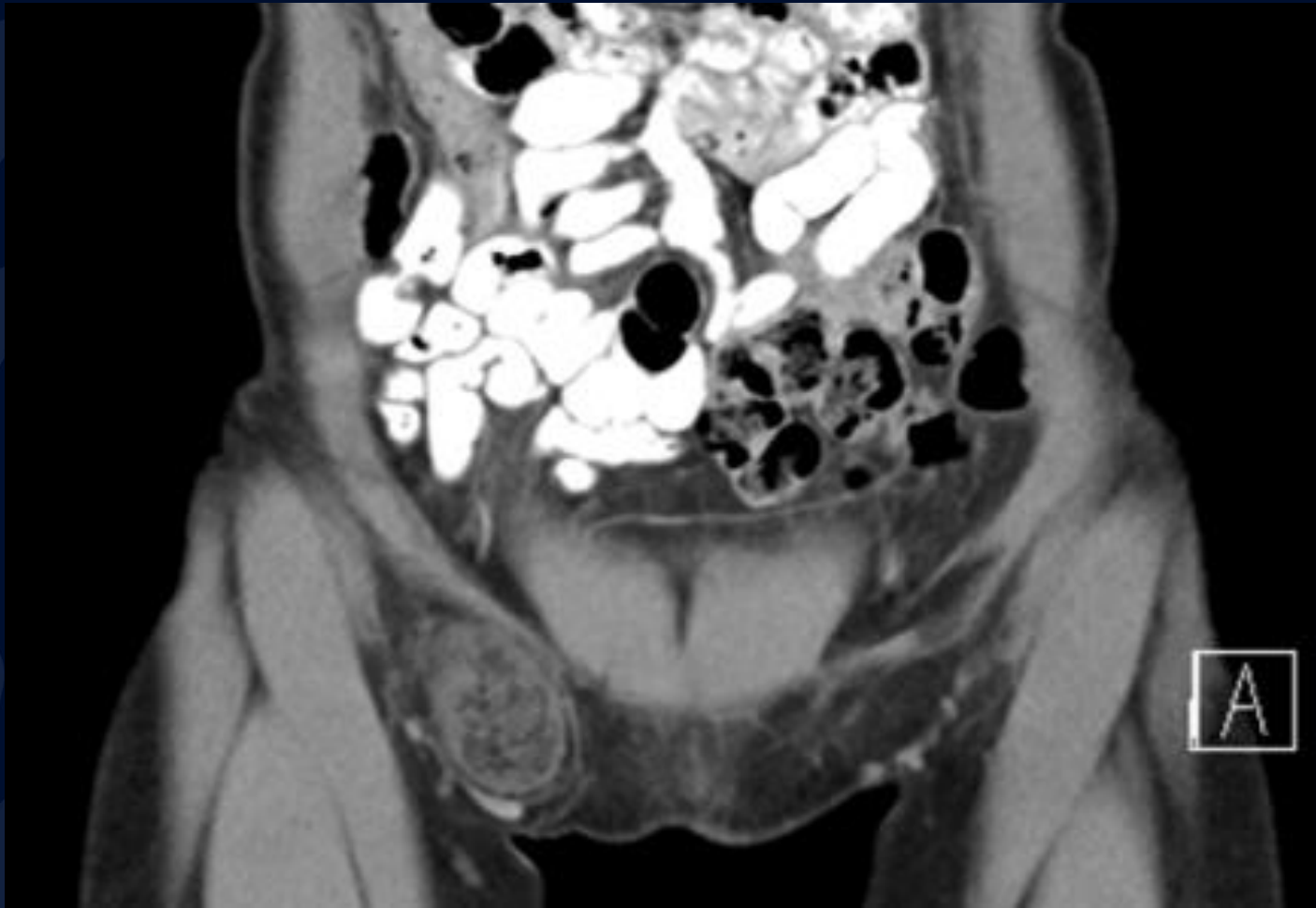
# CT abdomen and pelvis with oral & IV contrast



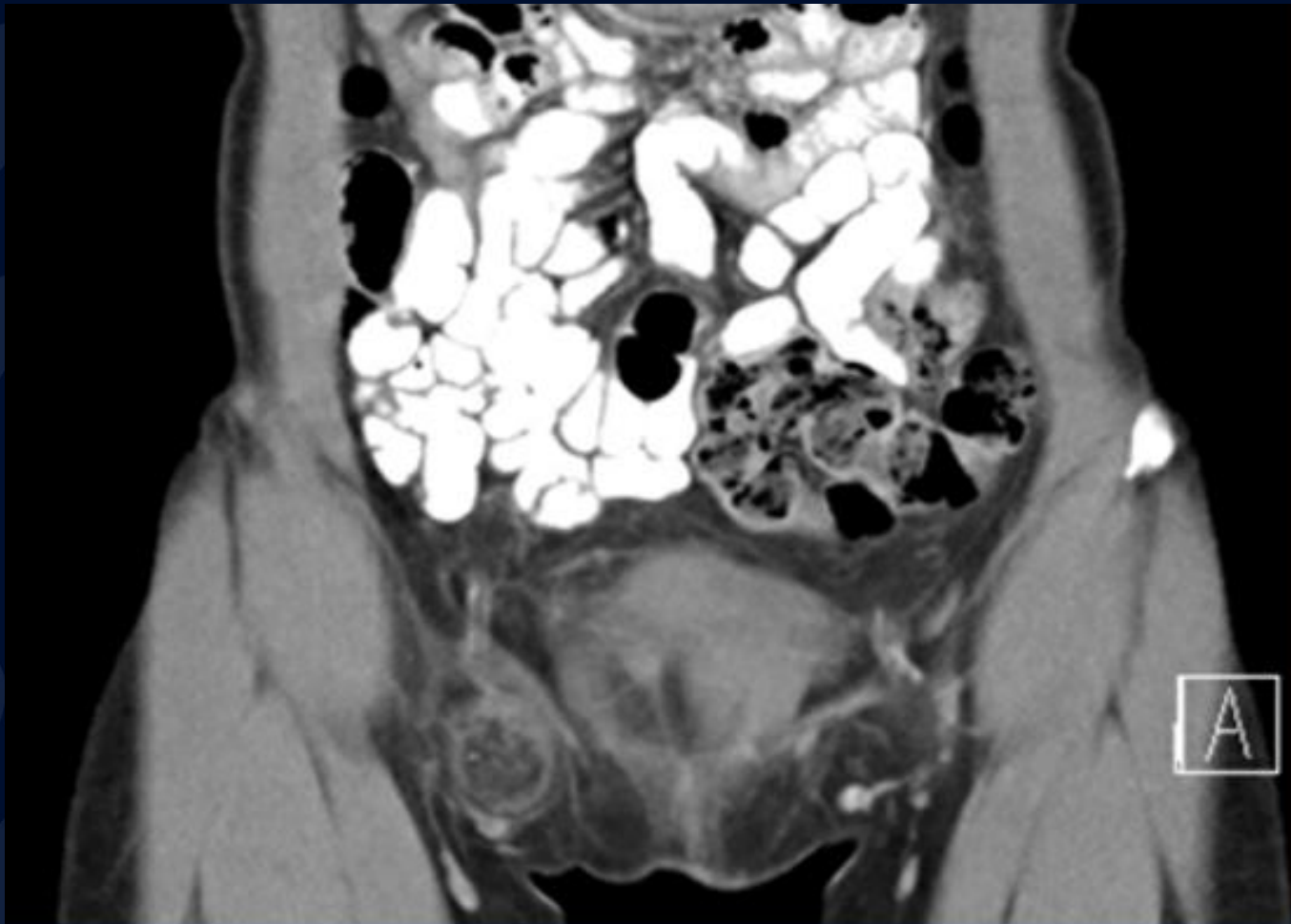# CT abdomen and pelvis with oral & IV contrast



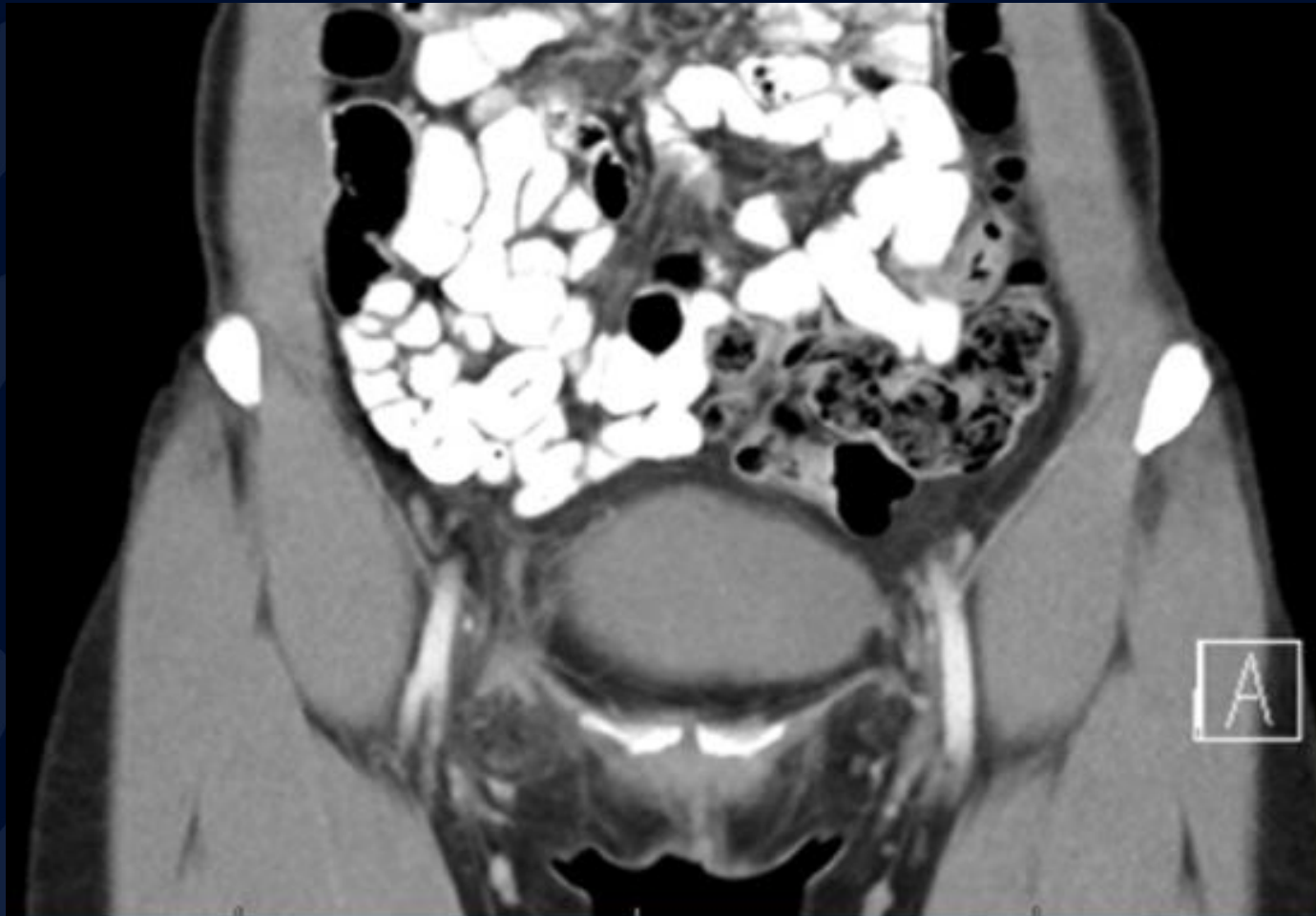
# CT abdomen and pelvis with oral & IV contrast



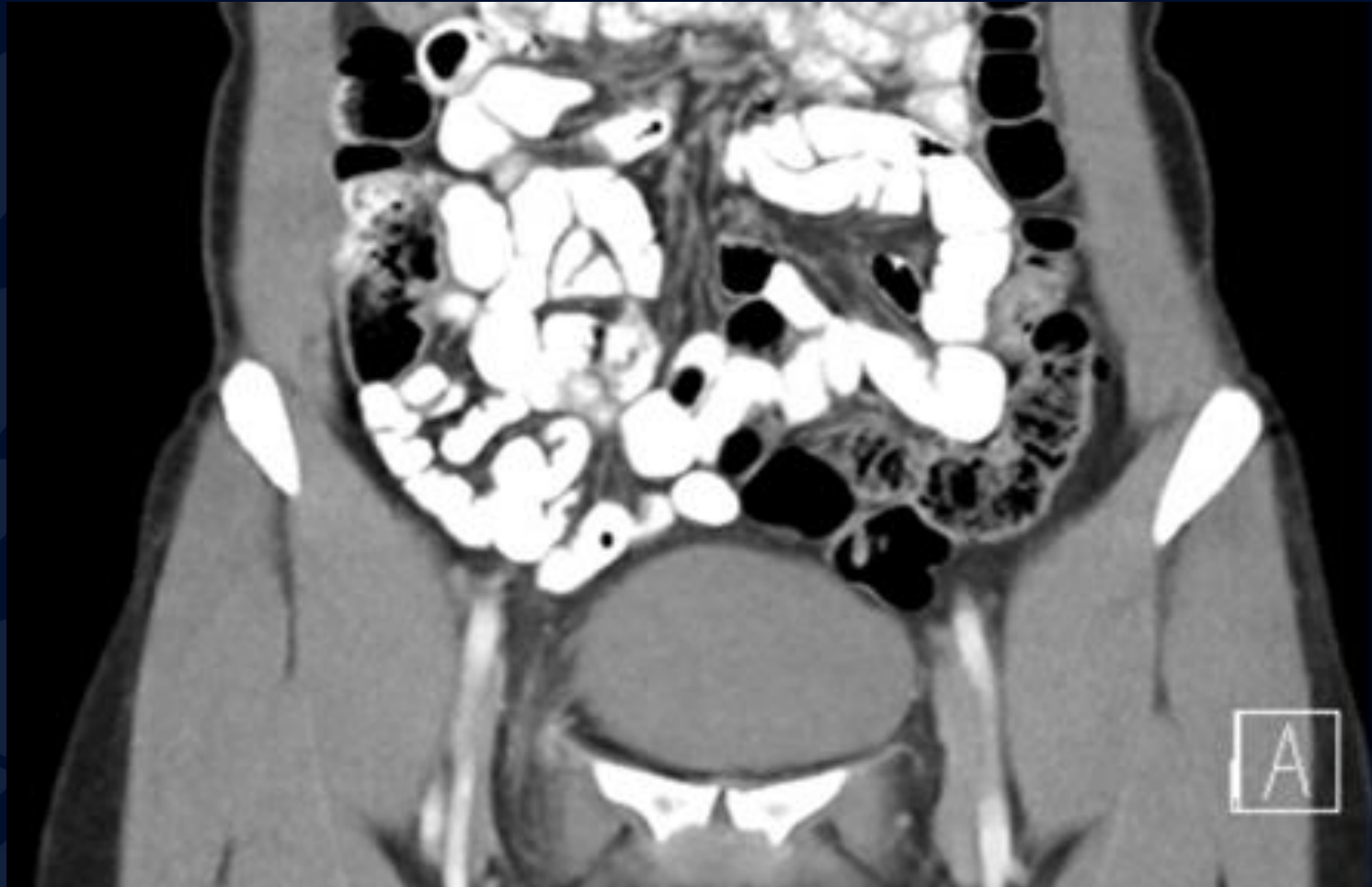# CT abdomen and pelvis with oral & IV contrast



# CT abdomen and pelvis with oral & IV contrast

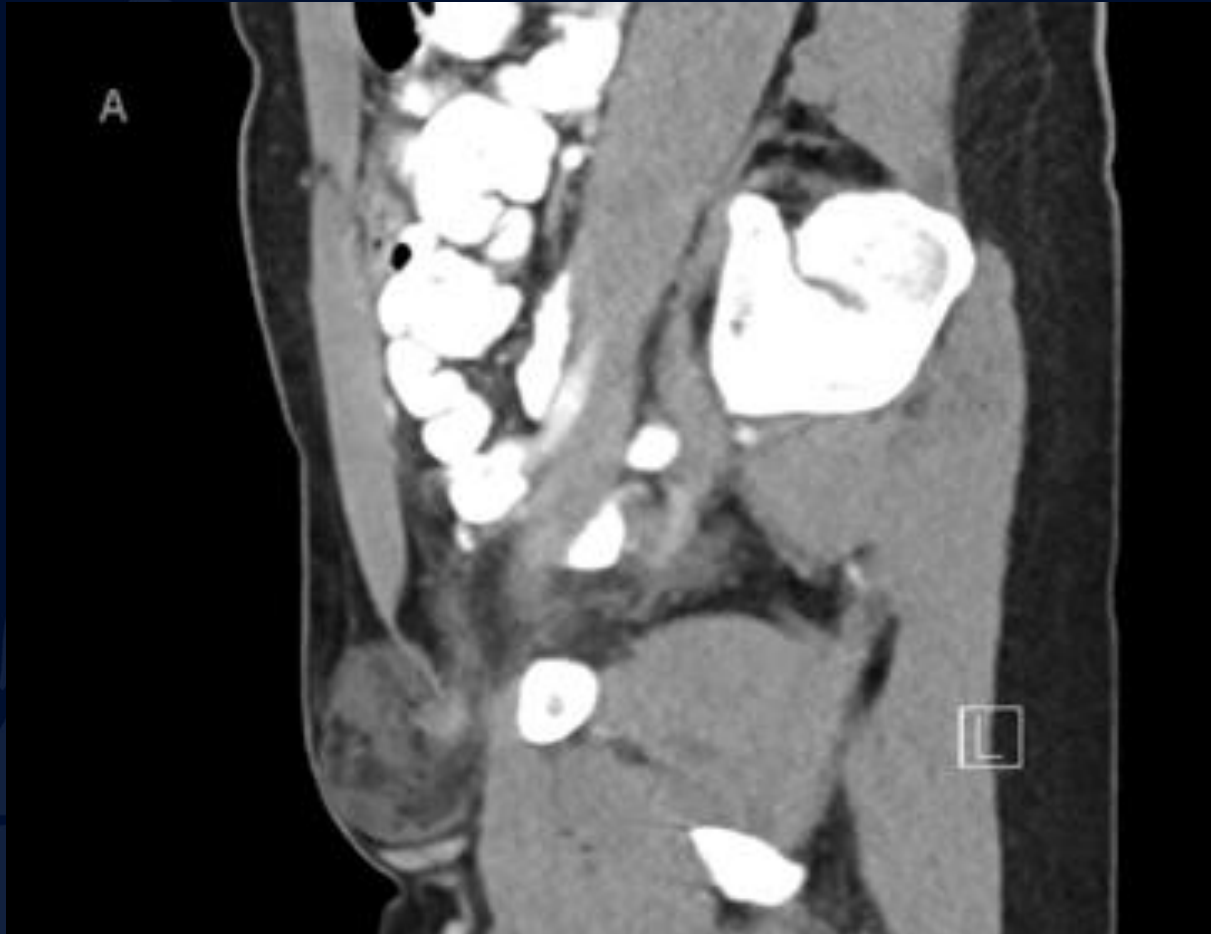

# CT abdomen and pelvis with oral & IV contrast





# CT abdomen and pelvis with oral & IV contrast



A large, stylized oak leaf graphic in a dark blue color, positioned on the left side of the slide. It features detailed vein patterns and a lobed edge.

?

# Right Femoral Hernia

# Femoral Hernia

- Type of groin herniation caused by abdominal wall defect
- Much less common than inguinal hernias (comprises 2-4% of all groin hernias)
- Stereotypical patient: middle-aged to elderly female
- 4x more likely in females than males
- Twice as likely to be right-sided than left-sided
- Can be found incidentally in asymptomatic patients
- Symptomatic hernias can present with palpable lump at the top of the thigh, swelling, vague pelvic/groin discomfort; nausea, vomiting and pain usually only occur with strangulation

# Femoral Hernia

- Protrusion of peritoneal contents through the femoral ring into the femoral canal
  - Posteroinferior to the inguinal ligament
  - Posterolateral to the pubic tubercle
  - Medial to the femoral vein (often causing compression of the femoral vein)
  - Inferior to the inferior epigastric vessels
- Hernia sac can contain omental fat or bowel
- Typically has a narrow funnel-shaped or pear-shaped neck
- Contrast-enhanced CT is generally considered the best imaging modality for definitive diagnosis
- Valsalva maneuver may help with identification and diagnosis on ultrasound

# Femoral Hernia

## Management

- Important to identify due to high risk of morbidity and mortality
  - Complications typically related to incarceration/bowel obstruction
  - 1% mortality rate for ages 70-79
  - 5% mortality rate for ages 80-90
- Can be challenging to diagnose clinically in obese patients
- For symptomatic femoral hernia or newly discovered asymptomatic femoral hernia, prompt surgical repair should be considered to avoid high risk of complications and mortality
  - Highest risk of complications of all groin hernias including incarceration and strangulation (25-40%), as well as increased mortality
  - No consensus on ideal approach (i.e., open vs. laparoscopic surgery)
  - Longstanding asymptomatic hernias sometimes can be managed conservatively depending on clinical context

# References

<https://radiopaedia.org/articles/femoral-hernia>

Raman SP. Femoral Hernia. STATdx. 6/15/2021.

Lee RKL, Griffith JF. Groin Hernia. STATdx. 9/24/2018.

Suzuki S, Furui S, Okinaga K et al. Differentiation of Femoral Versus Inguinal Hernia: CT Findings. AJR Am J Roentgenol. 2007;189(2):W78-83.

Cherian P & Parnell A. The Diagnosis and Classification of Inguinal and Femoral Hernia on Multisection Spiral CT. Clin Radiol. 2008;63(2):184-92.

Jamadar D, Jacobson J, Morag Y et al. Sonography of Inguinal Region Hernias. AJR Am J Roentgenol. 2006;187(1):185-90.