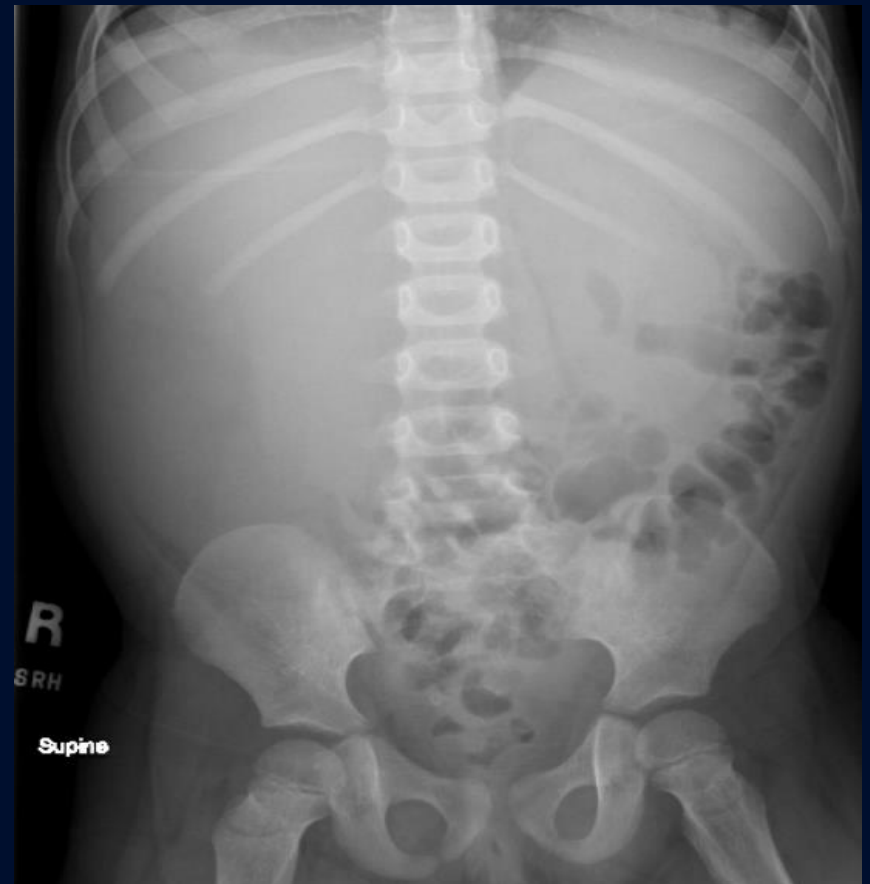
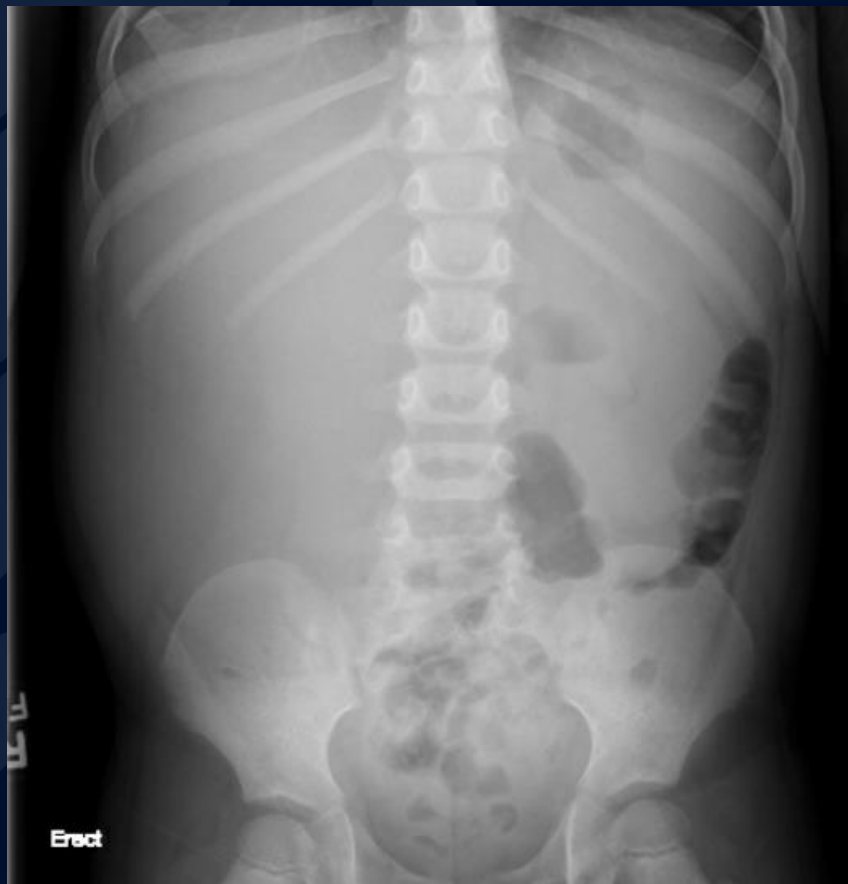
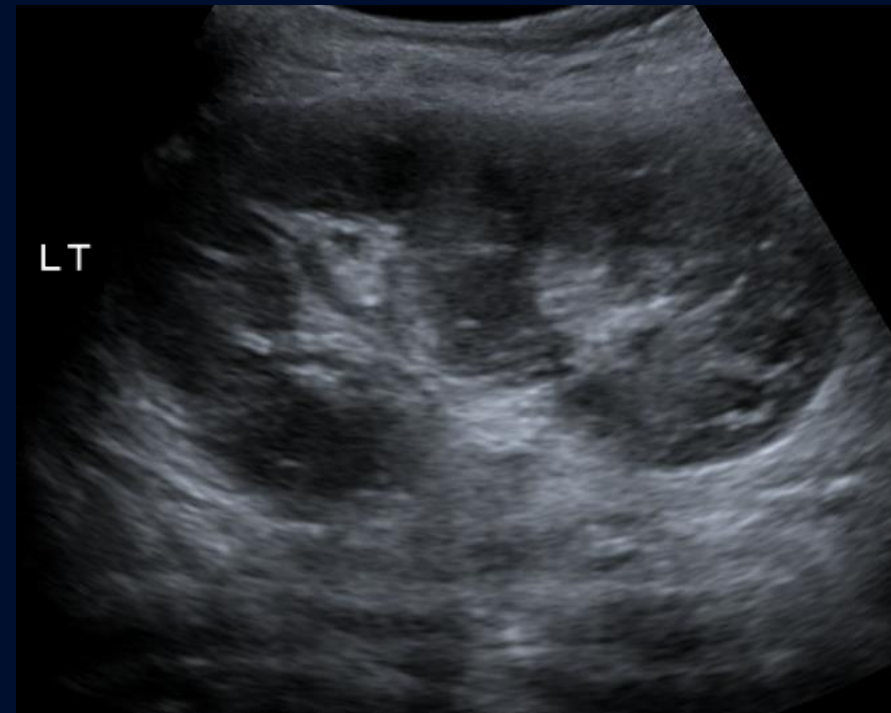
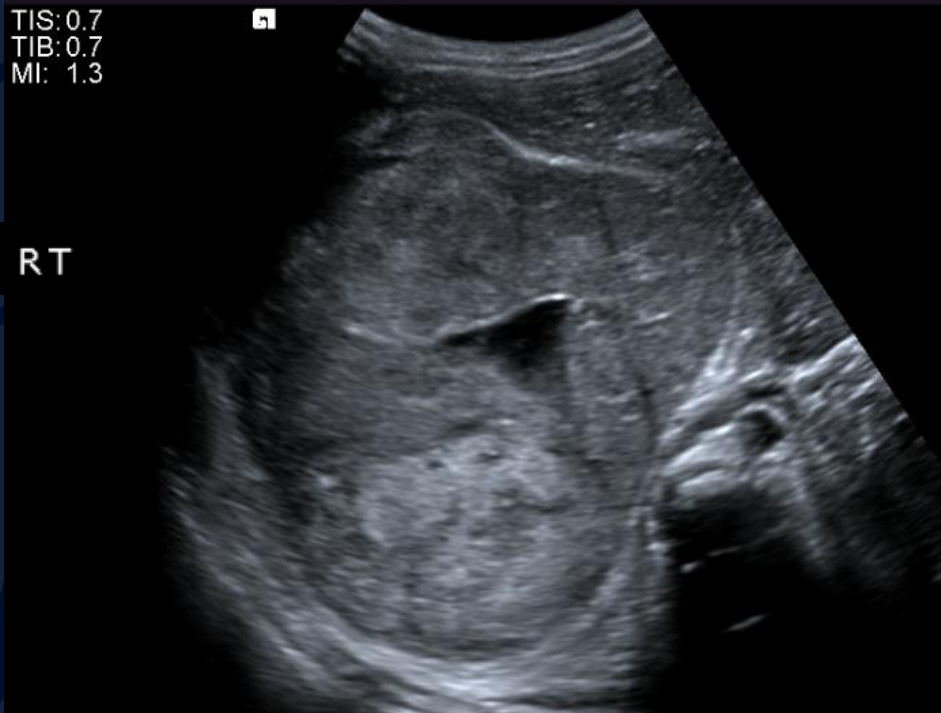# 3-year-old girl with abdominal pain and vaginal bleeding

Charissa Joy Okang, MS3

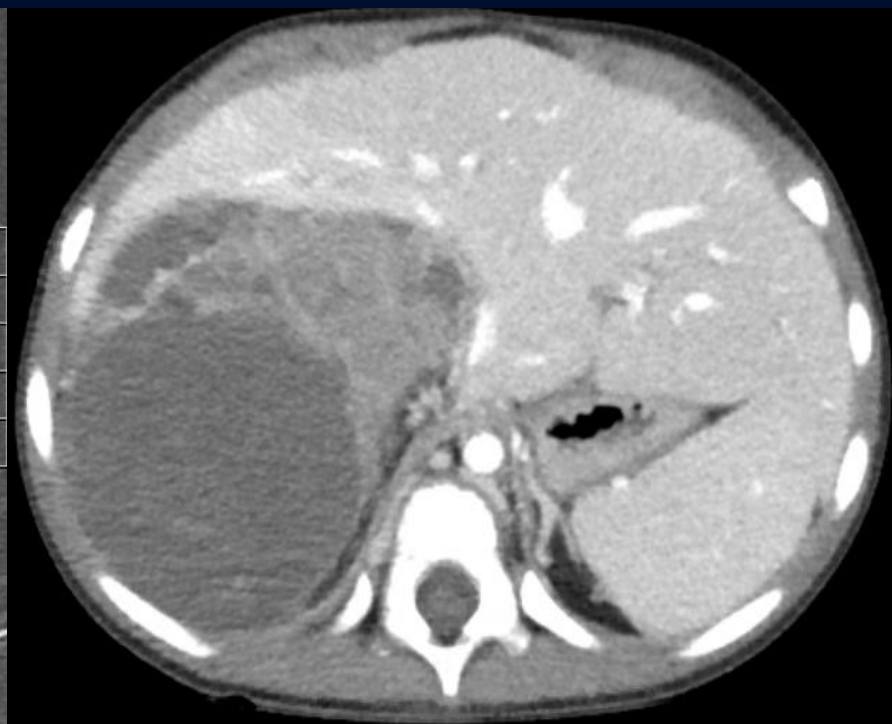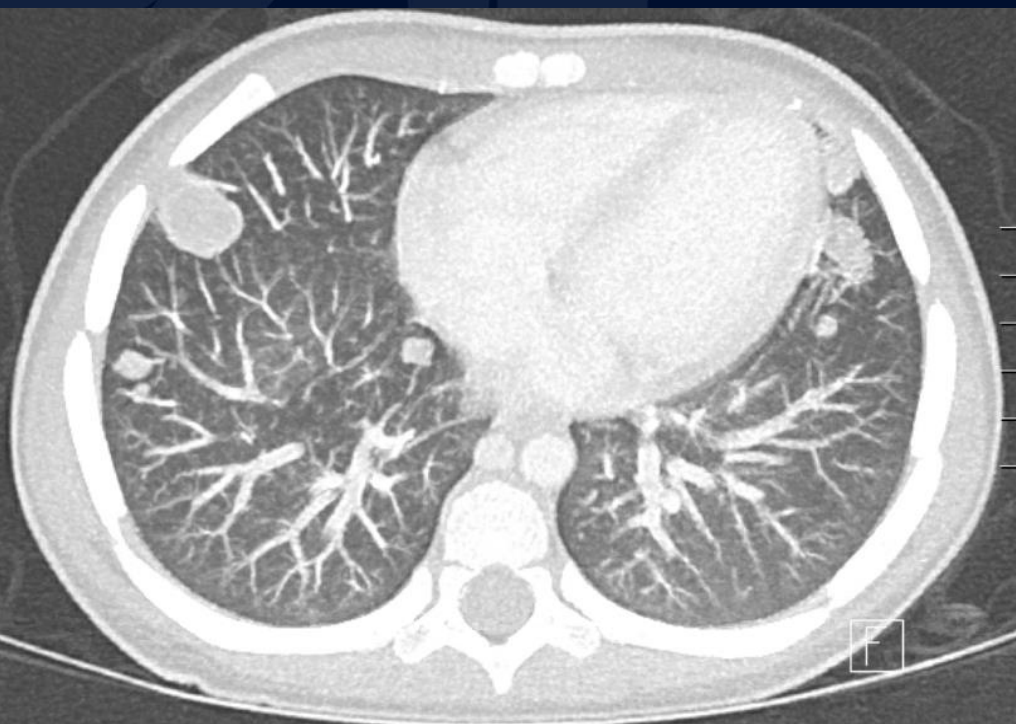
# Radiograph



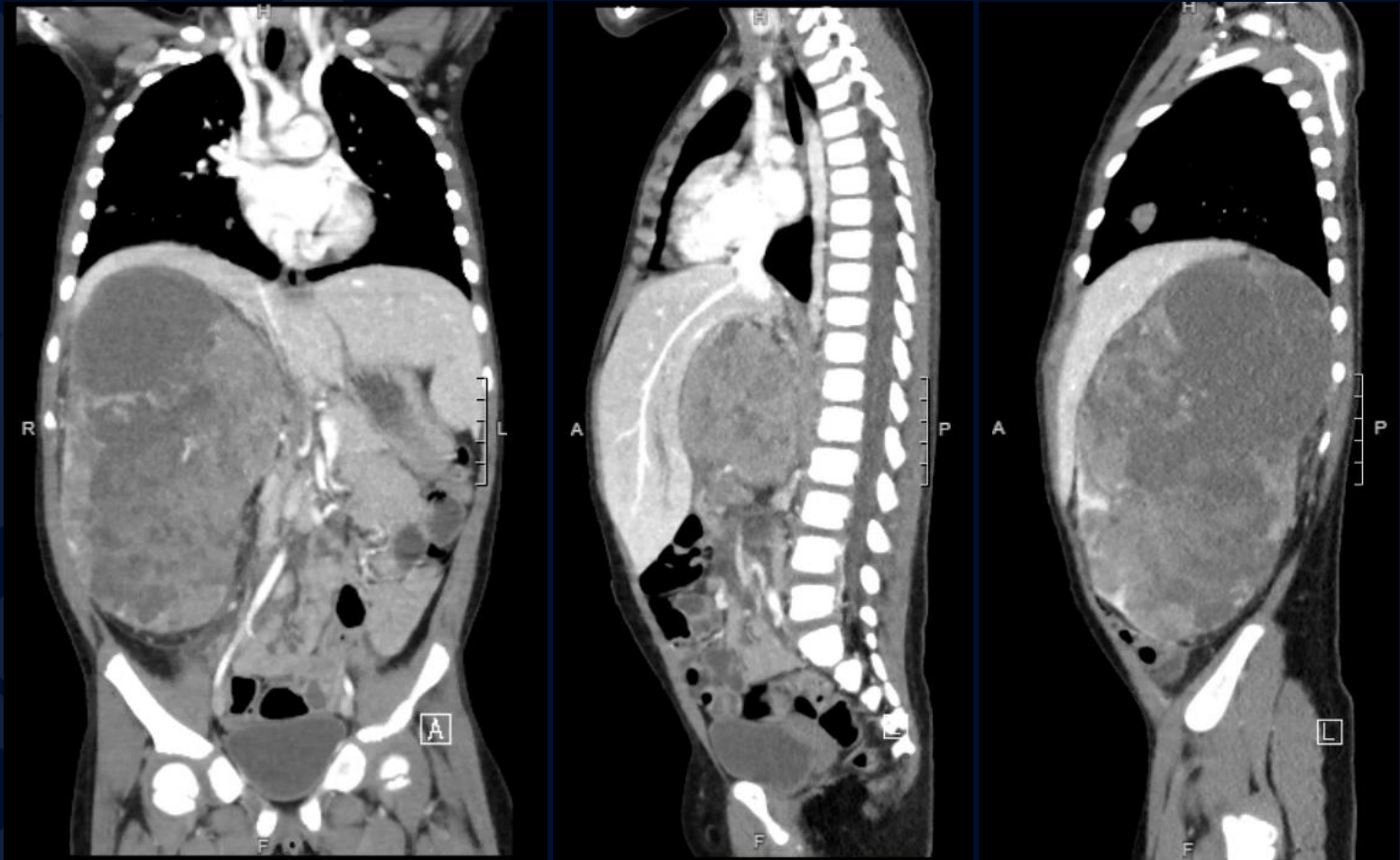
# Ultrasound



# CT IV Contrast



# CT IV Contrast



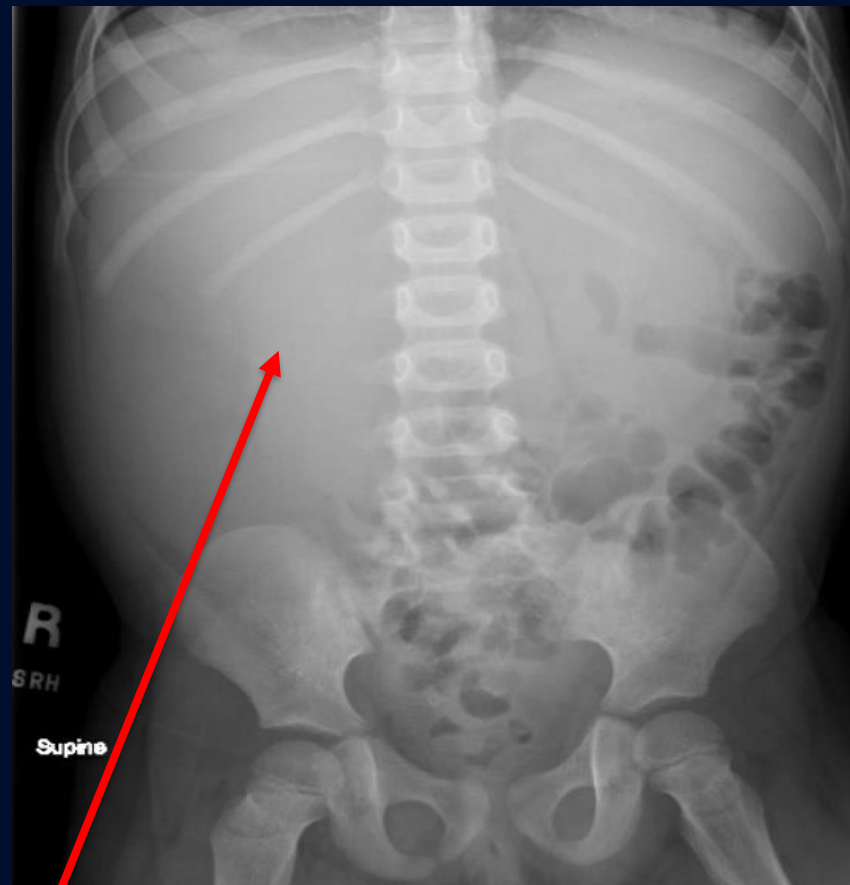
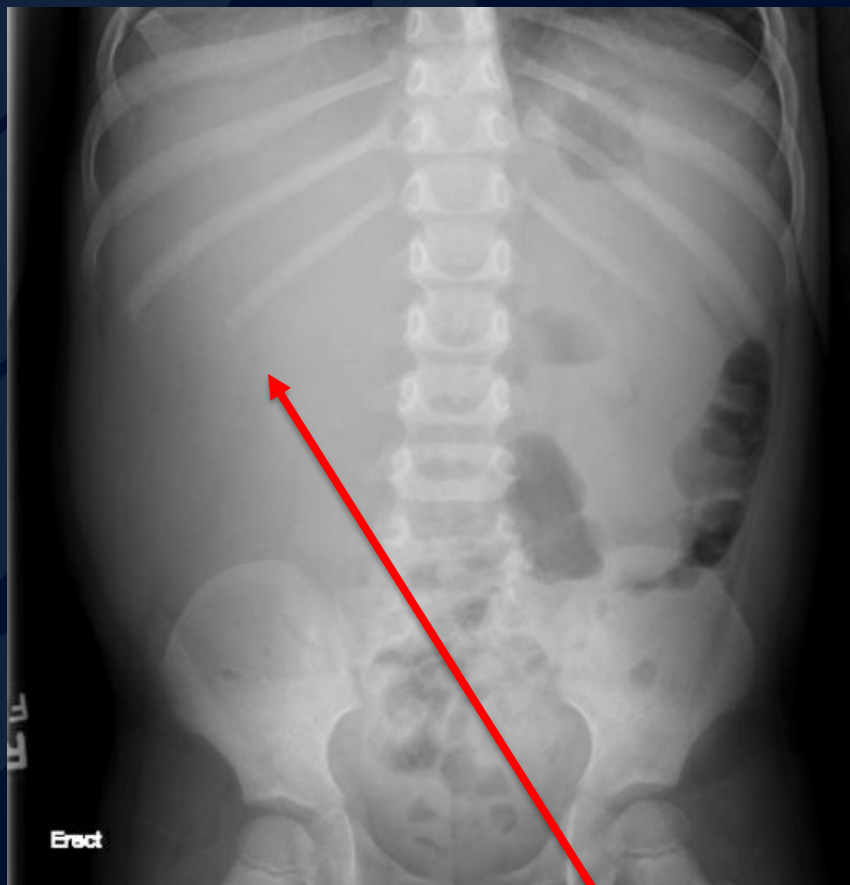

?

# Nephroblastoma (Wilms Tumor)



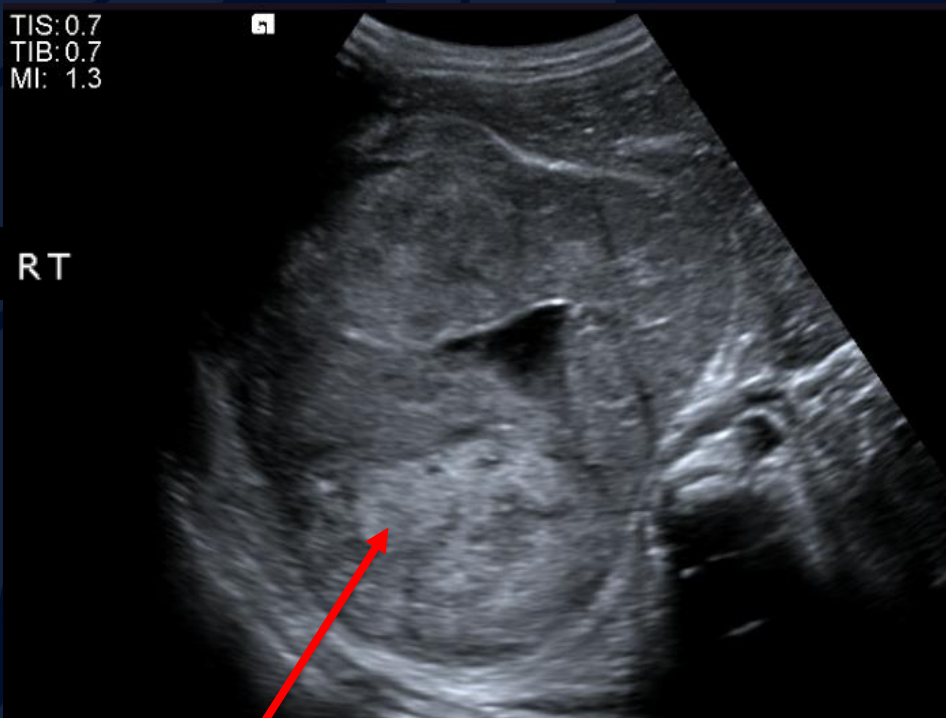
# Radiograph



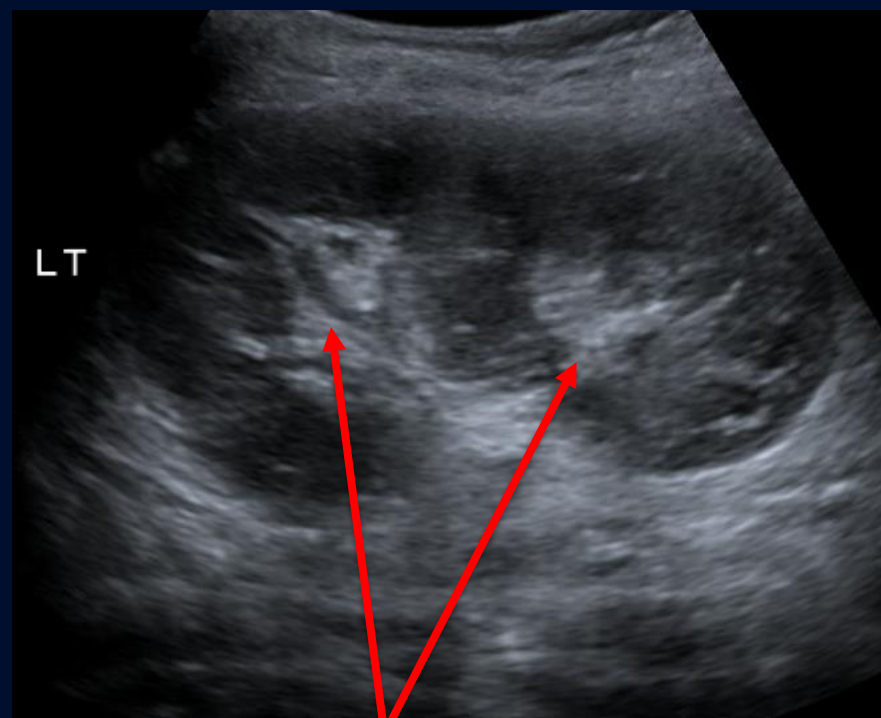
Right upper quadrant  
soft tissue mass



# Ultrasound



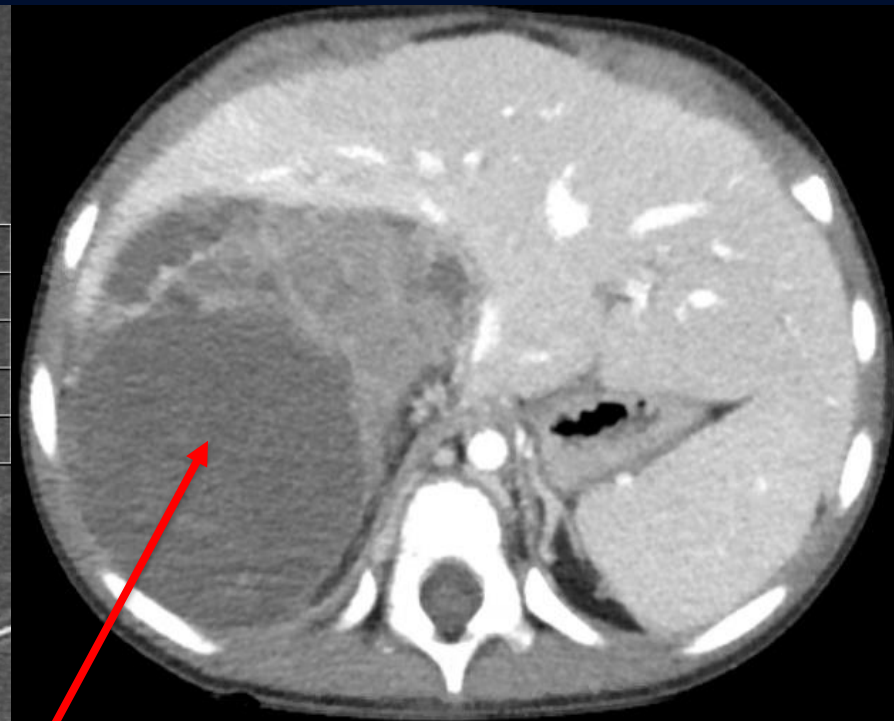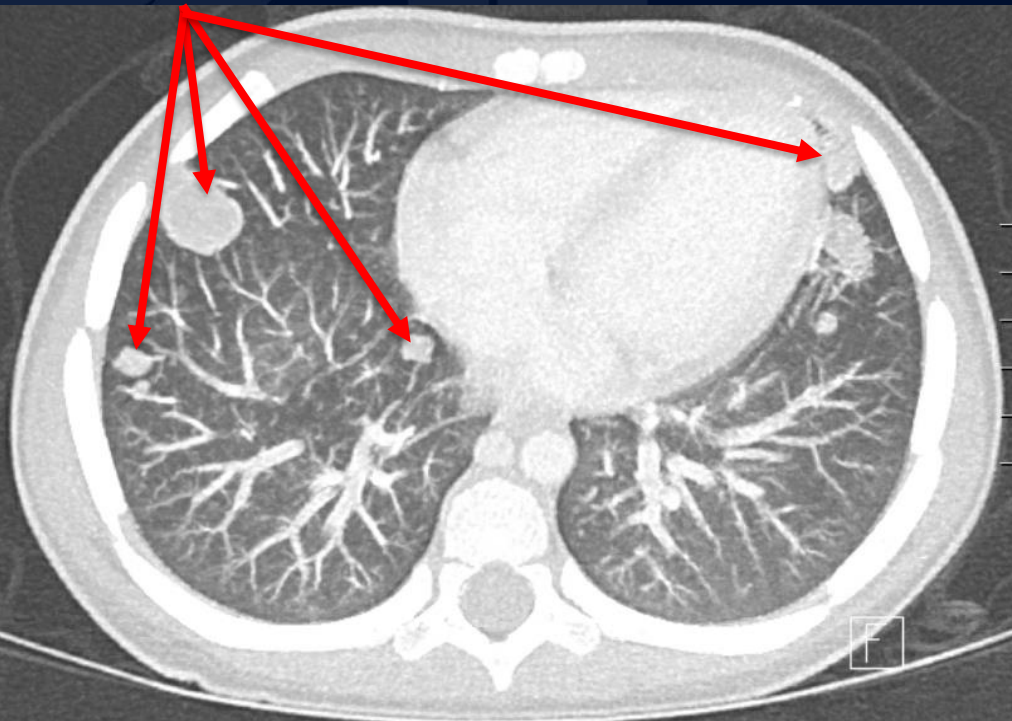
Heterogenous right renal mass



Duplex left kidney

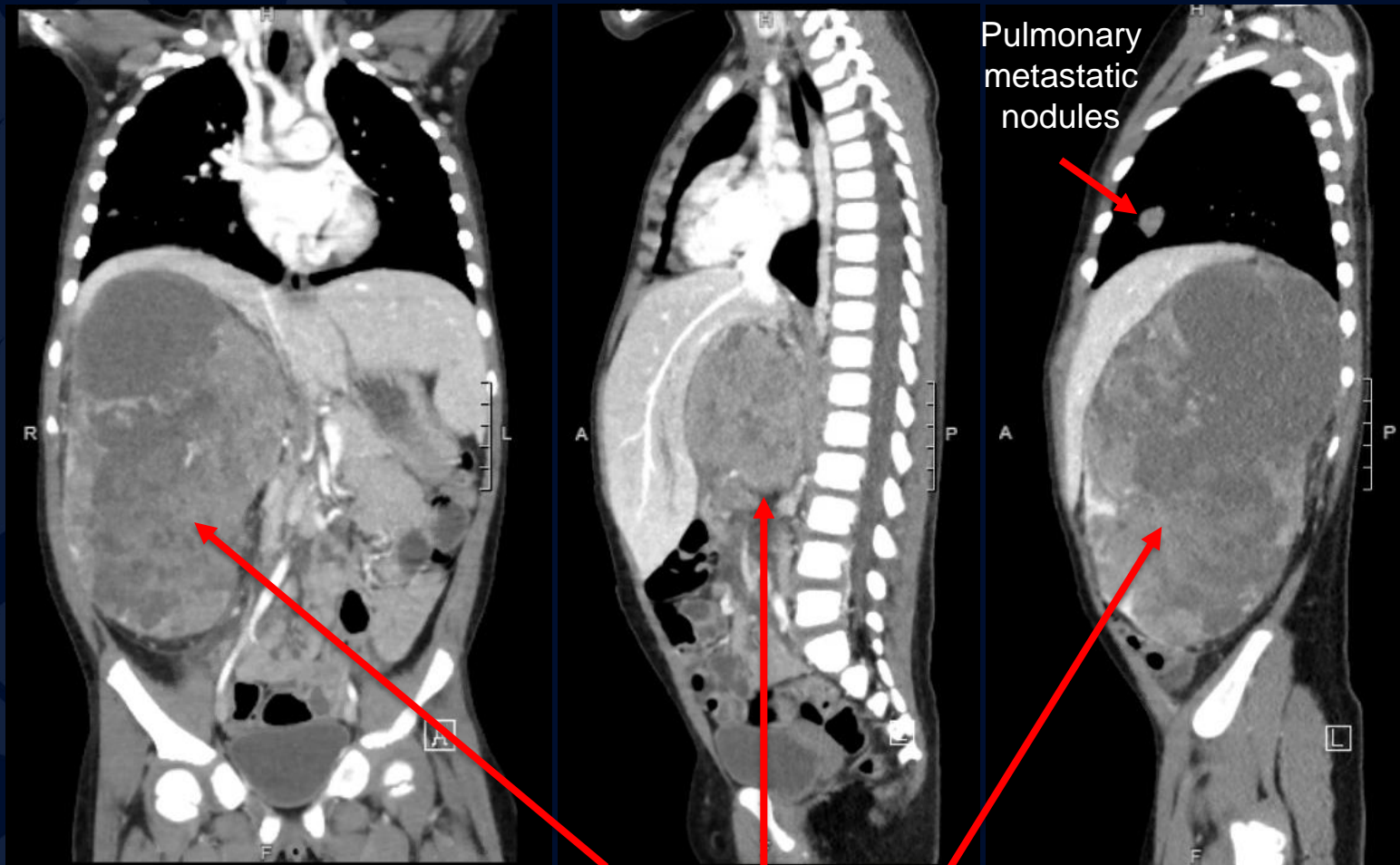
# CT IV Contrast

Pulmonary metastatic nodules



Heterogenous right  
kidney mass

# CT IV Contrast



Heterogenous right  
kidney mass

# Nephroblastoma (Wilms Tumor)

- Malignant tumor of primitive metanephric blastema
- Most common renal malignancy in children; ~ 500 new cases in the US per year
- 80% occur in children < 5 years old
- Most often incidentally discovered as a palpable mass
- May be part of multiple malformation syndromes (e.g., WAGR syndrome)
- Abdominal imaging used to determine extent of disease
  - CT or MRI preferred
  - Chest imaging for evaluation of lung metastasis
- Overall 5-year survival rate in patients with localized abdominal disease >90%
- Recurrence in ~15% of patients

# Imaging Findings

## Ultrasound

- Large heterogeneously hypoechoic mass
- “claw” of splayed residual kidney surrounding mass

## CT

- Large, poorly enhancing, heterogeneous mass
- Often have well-defined margins or pseudocapsule
- Displaced adjacent organs
- +/- enlarged retroperitoneal lymph nodes
- +/- tumor thrombus in renal vein, IVC, right atrium
- May have local extension into perirenal fat or gross tumor rupture with ascites

## MR

- T1: Heterogeneous, predominantly intermediate to low signal, may have foci of high signal due to blood products; heterogeneously hypoenhancing relative to normal renal parenchyma
- T2: heterogeneous, solid, predominantly high signal; purely cystic lesions are uncommon
- DWI: solid portions restrict diffusion



# References

Chintagumpala, M., & Smith, V. (2022, June). *Presentation, diagnosis, and staging of Wilms tumor*. UConn Health Sciences Library. Retrieved from [https://www-uptodate-com.online.uchc.edu/contents/presentation-diagnosis-and-staging-of-wilms-tumor?search=wilms+tumor&source=search\\_result&selectedTitle=1~121&usage\\_type=default&display\\_rank=1#H2528436941](https://www-uptodate-com.online.uchc.edu/contents/presentation-diagnosis-and-staging-of-wilms-tumor?search=wilms+tumor&source=search_result&selectedTitle=1~121&usage_type=default&display_rank=1#H2528436941)

Chintagumpala, M., & Smith, V. (2022, June). UConn Health Sciences Library. Retrieved from [https://www-uptodate-com.online.uchc.edu/contents/treatment-and-prognosis-of-wilms-tumor?sectionName=Lung+metastases&search=wilms+tumor&topicRef=6249&anchor=H14&source=see\\_link#H14](https://www-uptodate-com.online.uchc.edu/contents/treatment-and-prognosis-of-wilms-tumor?sectionName=Lung+metastases&search=wilms+tumor&topicRef=6249&anchor=H14&source=see_link#H14)

<https://app.statdx.com/document/wilms-tumor/6758069f-ec22-406f-ac3a-91d73b4f5089?term=Wilms%20Tumor&searchType=documents&category=All>