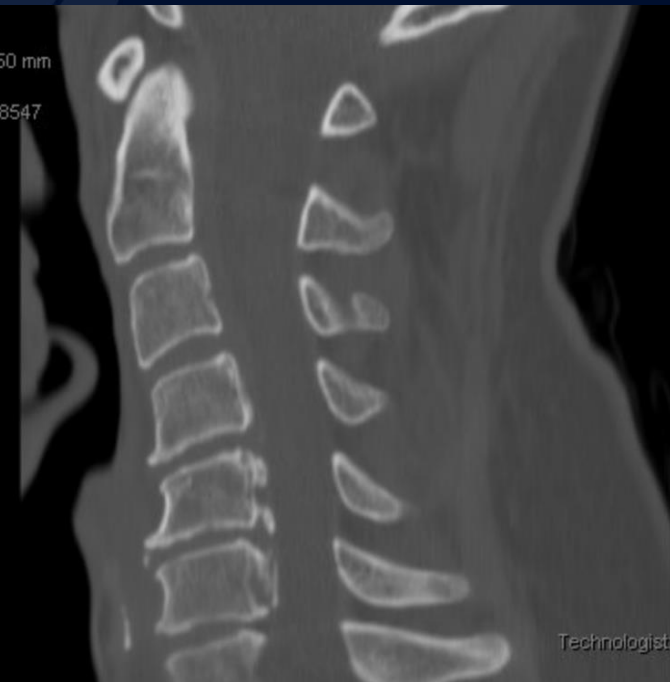

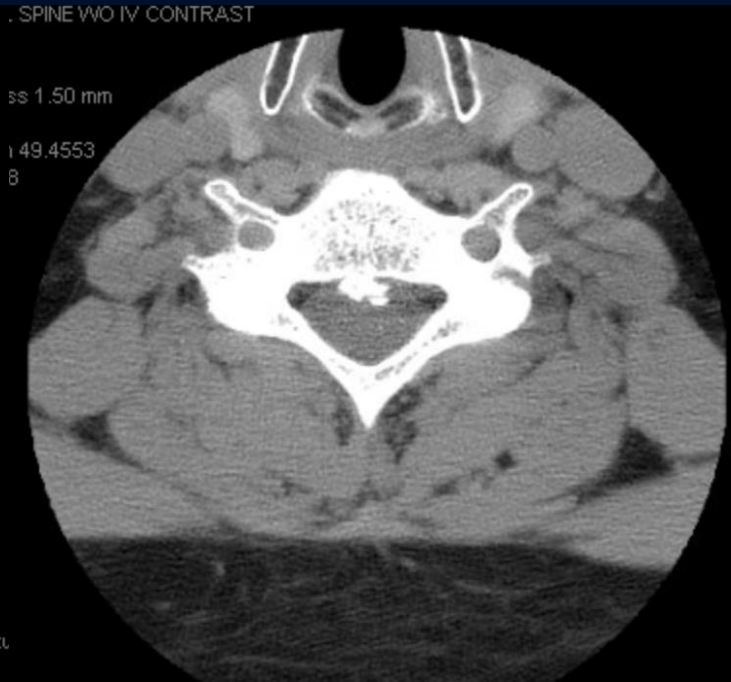# 41-year-old male with non-traumatic neck and left arm pain

Maxwell Trudeau, MS3

# Non-contrast CT

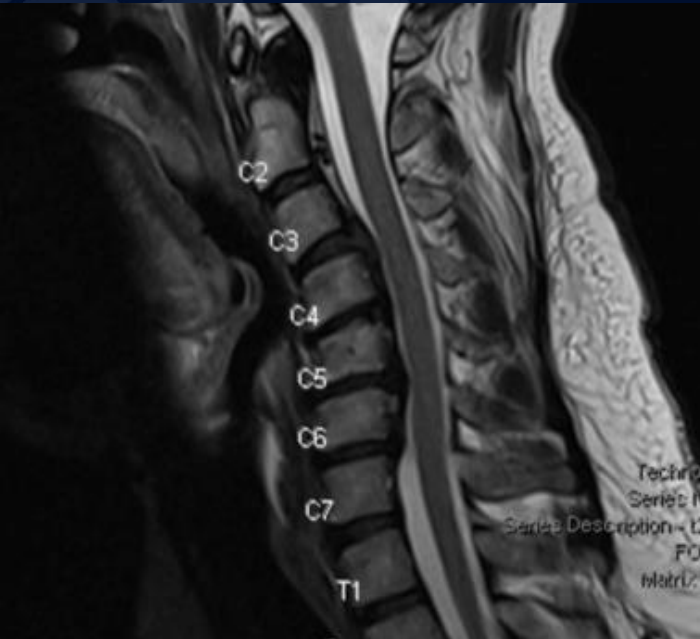


Sagittal

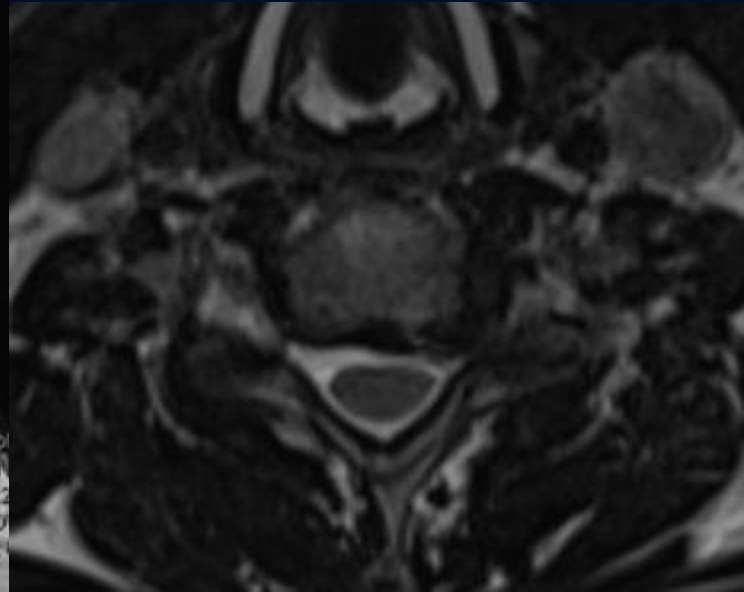


Axial

# Non-contrast T2




Sagittal



Axial

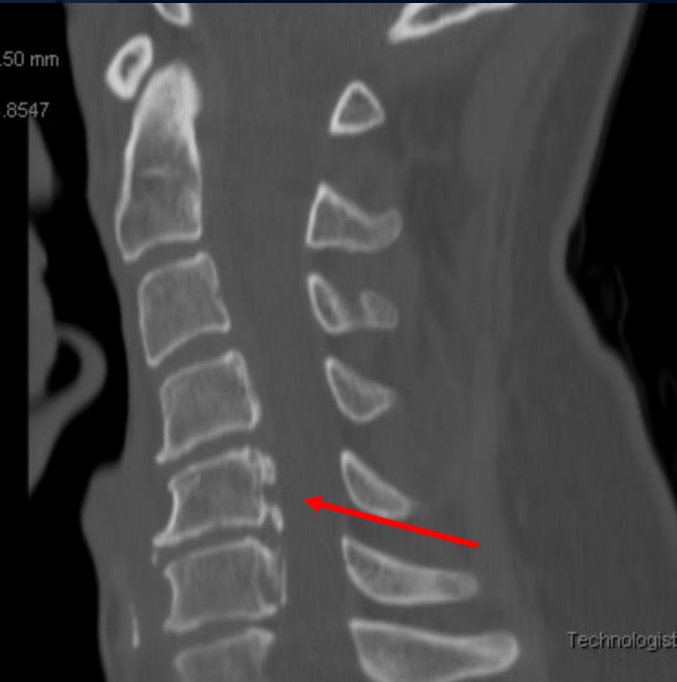

?

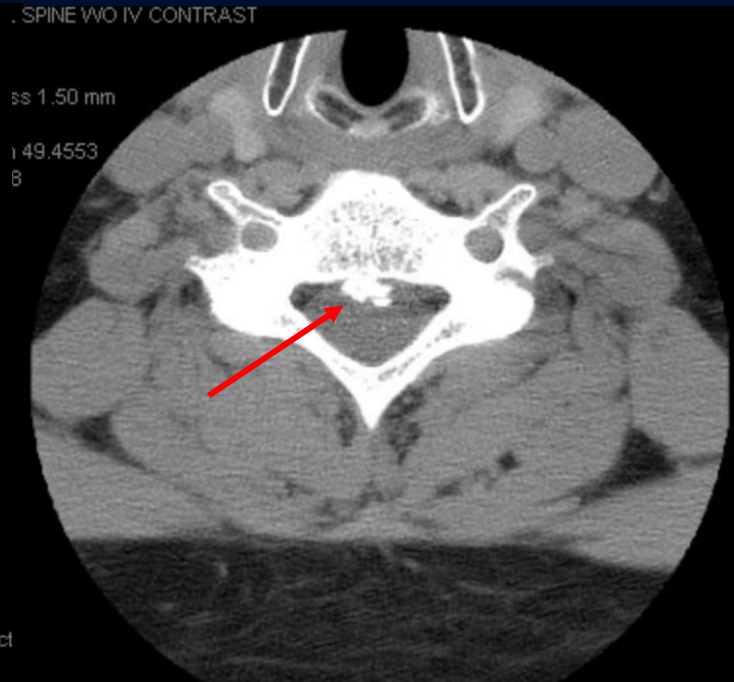
A large, stylized oak leaf graphic in a dark blue color, positioned on the left side of the slide, partially overlapping the text.

# Ossification of the Posterior Longitudinal Ligament (OPLL)

# Non-contrast CT



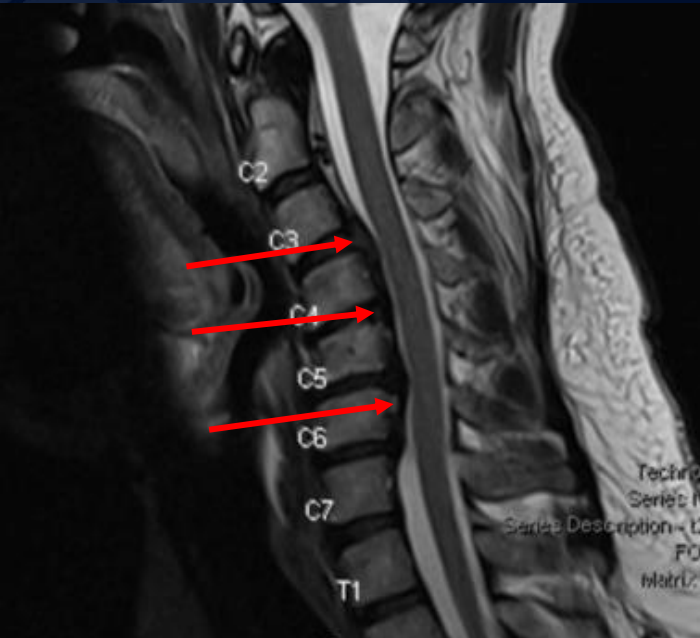
Sagittal



Axial

Calcification of the posterior longitudinal ligament

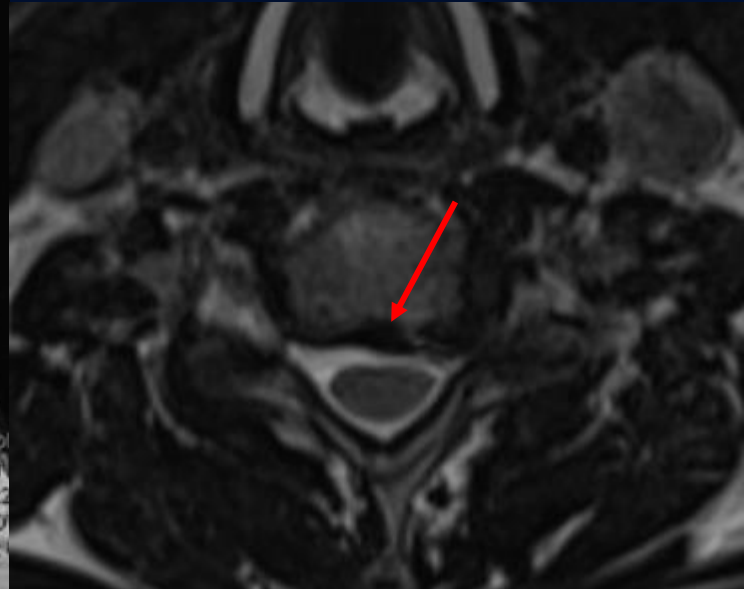
# Non-contrast T2



Sagittal

Loss of the normal cervical lordosis

Hypointense thickening of the posterior longitudinal ligament resulting in compression of the epidural space and spinal cord



Axial

# Ossification of the Posterior Longitudinal Ligament (OPLL)

Idiopathic cervical spine anomaly that most commonly affects the cervical spine and results in cervical myelopathy

- **Pathophysiology**

- Calcification and hardening of the posterior longitudinal ligament leading to compression of the spinal cord and nerves

- **Clinical presentation**

- Middle to older aged adults
- Asian decent
- Associated with diabetes, hypertension or obesity
- Neck or back pain, numbness or weakness in arms or legs; difficulty with coordination and balance

- **Differential diagnosis:** bone spurs/osteophytes, herniated disc, ligamentum flavum hypertrophy (or ossification), spondylolisthesis

- **Treatment**

- Observation if symptoms are minimal
- Patients with myelopathy require surgical decompression and stabilization



# References

- Moore DM. Ossification of Posterior Longitudinal Ligament. Orthobullets. 2022.  
<https://www.orthobullets.com/spine/2046/ossification-posterior-longitudinal-ligament>
- Matsunaga S, Sakou T. Ossification of the posterior longitudinal ligament of the cervical spine: etiology and natural history. Spine (Phila Pa 1976). 2012 Apr 20;37(9):E478-83.
- Doi T, et al. Risk factors for progression of ossification of the posterior longitudinal ligament in asymptomatic subjects. Journal of Neurosurgery. 2020;33(3):316-322.