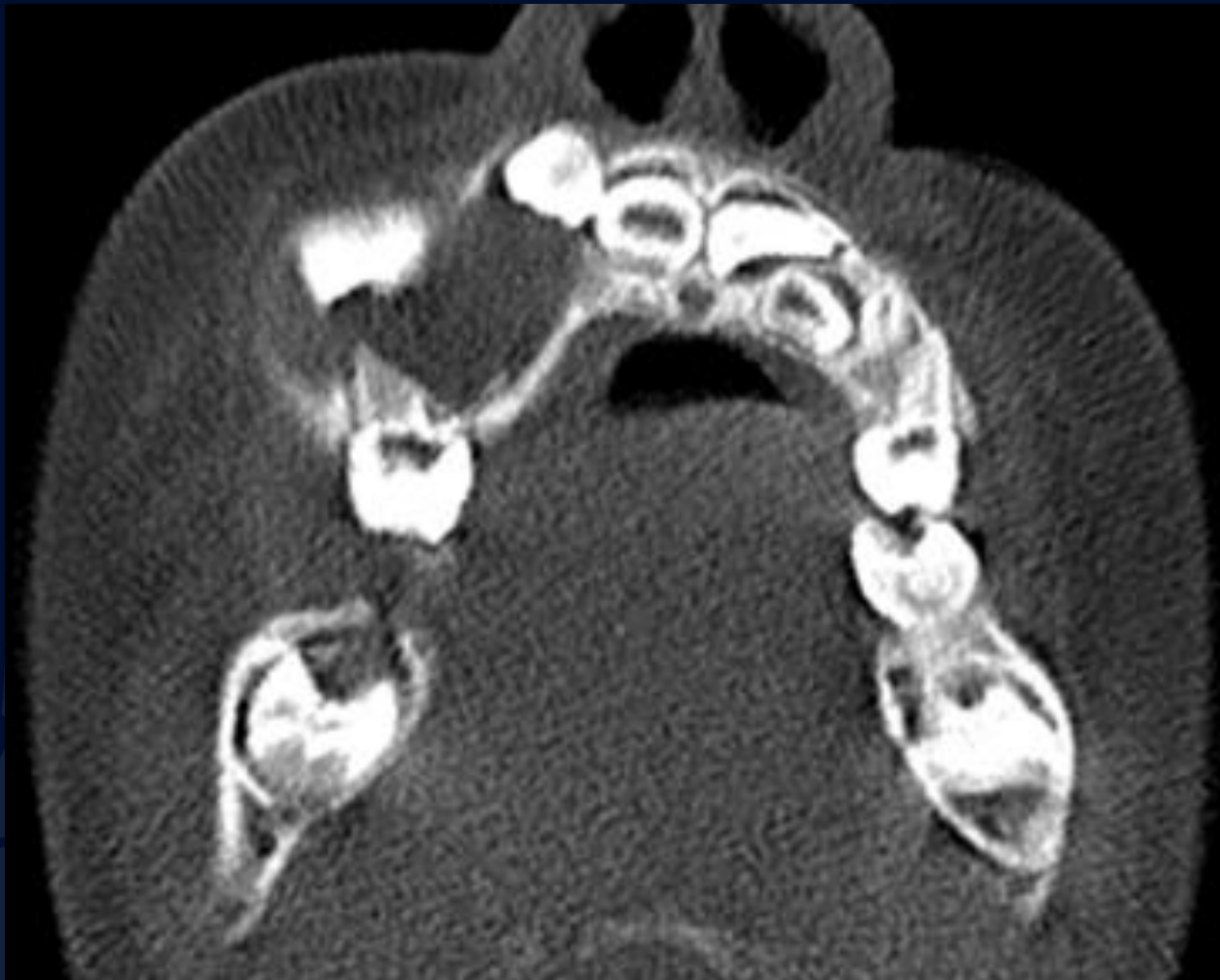

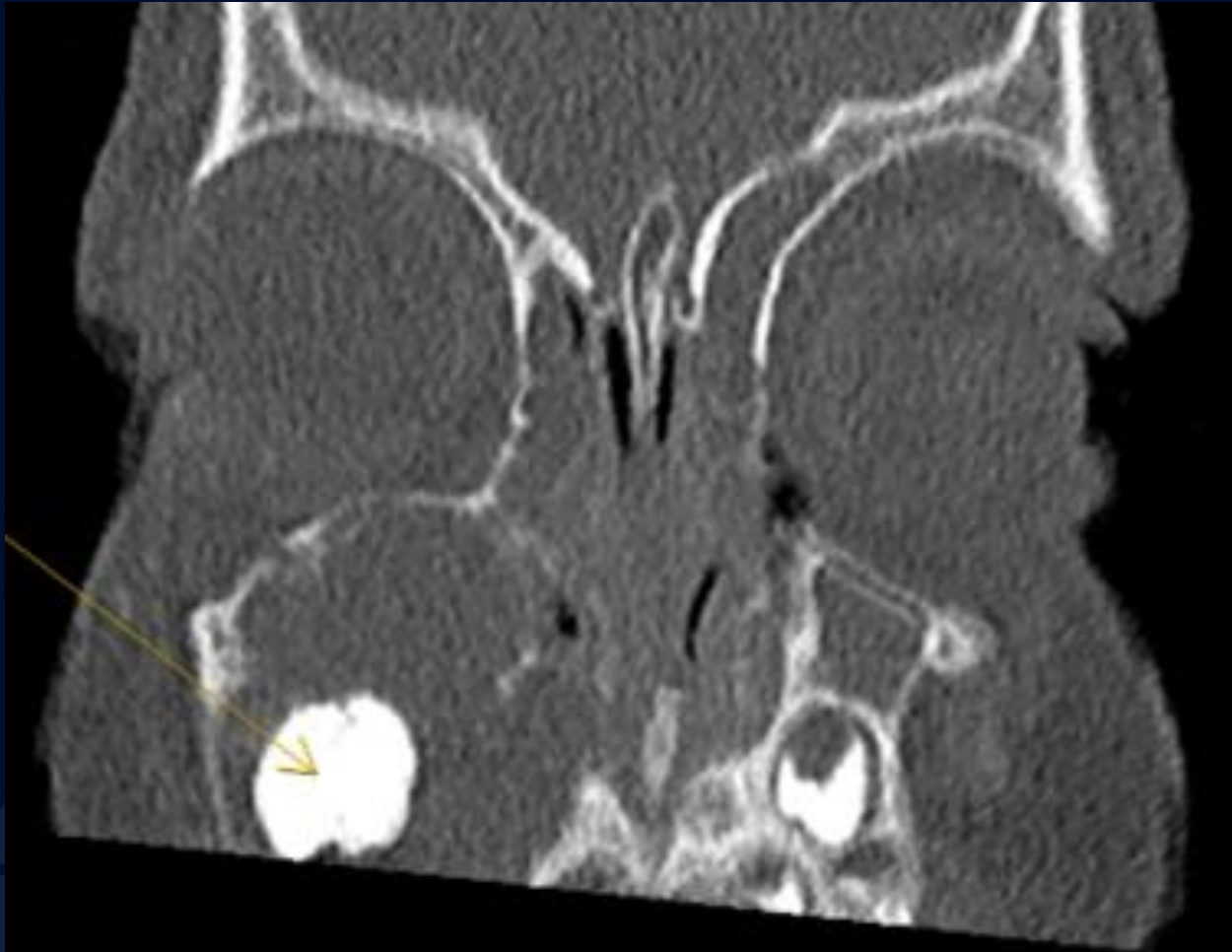
2-year-old male with 5-month
history of bony hard progressive
swelling of the right midface and
associated right eye proptosis

Kenneth MacCormac, DMD

Axial CT



Coronal CT



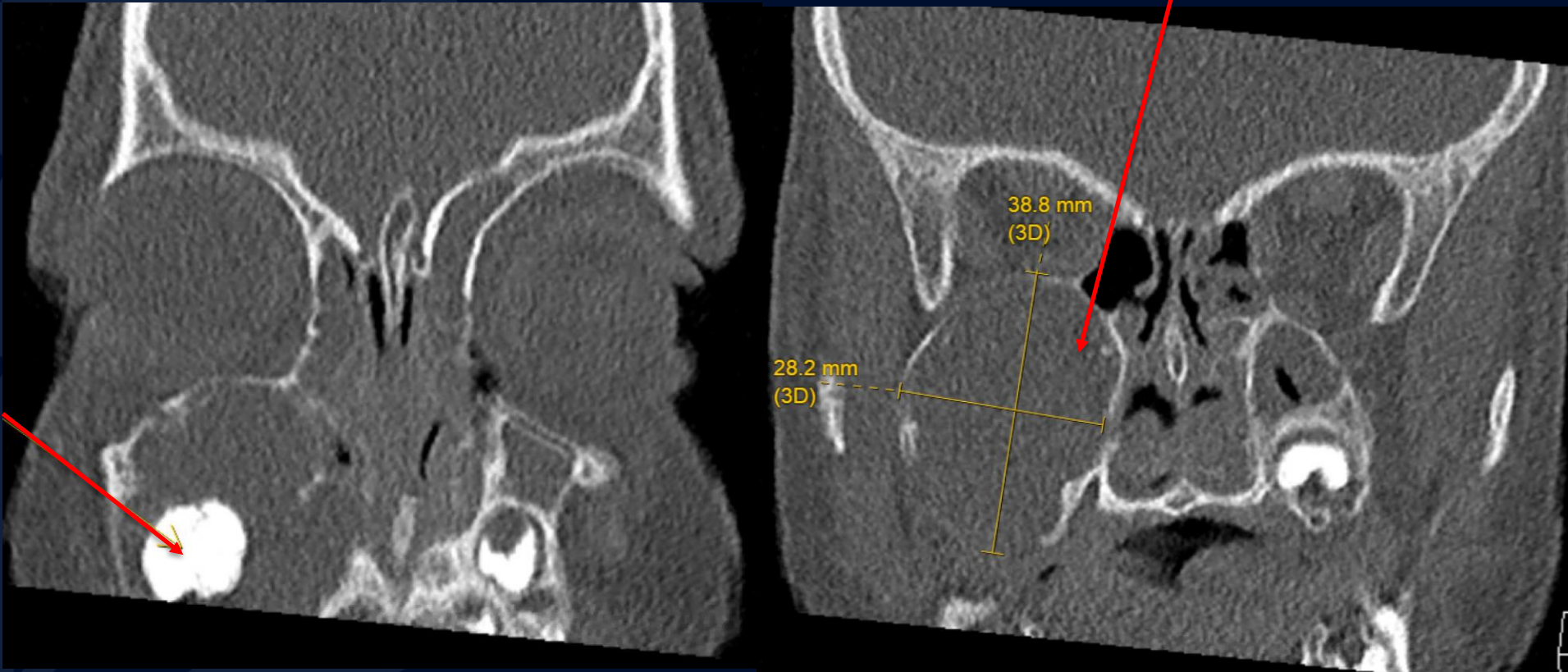
A large, stylized oak leaf graphic in a dark blue color, positioned on the left side of the slide. It features detailed vein patterns and a lobed edge.

?

Ameloblastoma Fibro-Odontoma

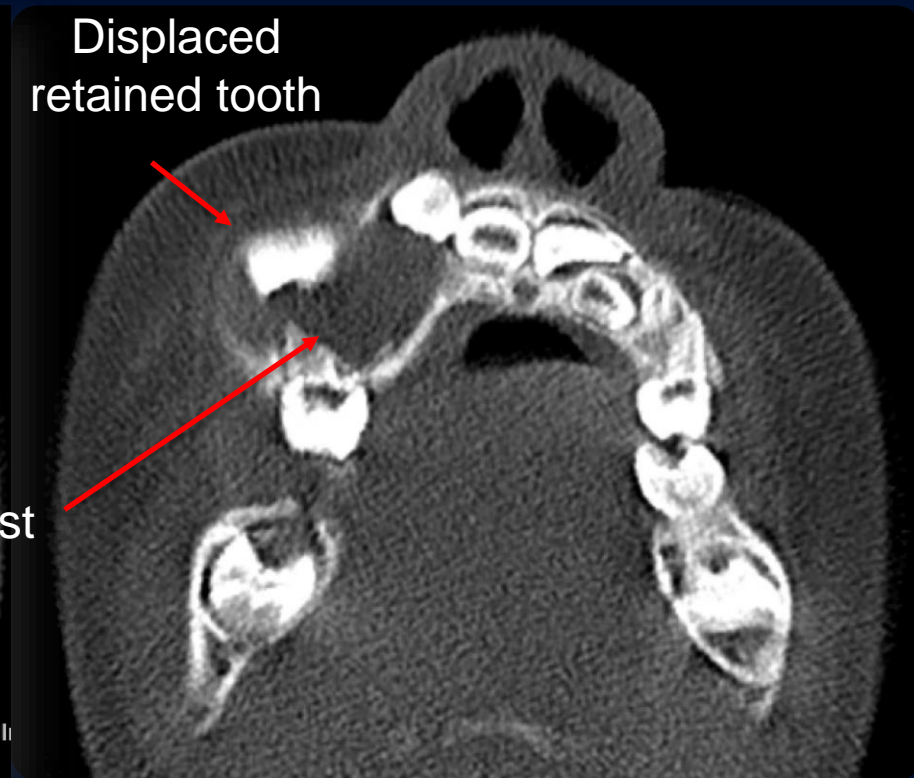
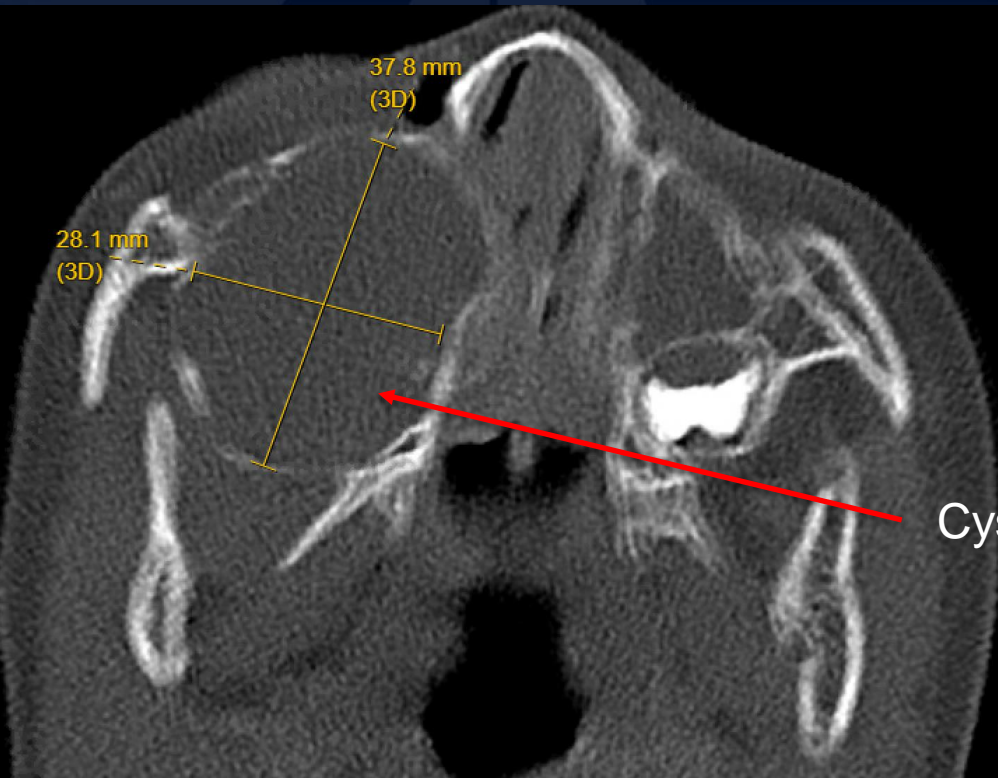
Coronal CT

Expansile cystic bone lesion



Irregularly developed tooth
within expansile bone cyst

Axial CT



Ameloblastic Fibro-Odontoma (AFO)

Benign Mixed Odontogenic Tumor

- Arises from the ectomesenchymal cells of developing teeth
- Reported cases of malignant transformation to a fibrosarcoma or odontogenic sarcoma
- Represent only 2% of all jaw tumors
- Most common in posterior mandible
- Most often arise in the second decade of life

Diagnosis

- AFOs are usually found when investigating failure of tooth eruption in the posterior mandible
- Ultimately biopsy is required for diagnosis as the radiographic features are common to several cysts/tumor of the jaws

Treatment

- Amenable to curettage

References

- Jeyaraj P. Management of Central Giant Cell Granulomas of the Jaws: An Unusual Case Report with Critical Appraisal of Existing Literature. *Ann Maxillofac Surg.* 2019 Jan-Jun;9(1):37-47. doi: 10.4103/ams.ams_232_18. PMID: 31293928; PMCID: PMC6585231.
- Surej Kumar LK, Manuel S, Khalam SA, Venugopal K, Sivakumar TT, Issac J (2014). "Ameloblastic fibro-odontoma". *International Journal of Surgery Case Reports.* 5 (12): 1142–1144. doi:10.1016/j.ijscr.2014.11.025. PMC 4276268. PMID 25437658.
- Howell RM, Burkes EJ (March 1977). "Malignant transformation of ameloblastic fibro-odontoma to ameloblastic fibrosarcoma". *Oral Surgery, Oral Medicine, and Oral Pathology.* 43 (3): 391–401. doi:10.1016/0030-4220(77)90326-7. PMID 265043.
- Herzog U, Putzke HP, Bienengräber V, Radke C (March 1991). "[The ameloblastic fibro-odontoma--an odontogenic mixed tumor progressing into an odontogenic sarcoma]". *Deutsche Zeitschrift für Mund-, Kiefer- und Gesichts-Chirurgie.* 15 (2): 90–93. PMID 1816940.