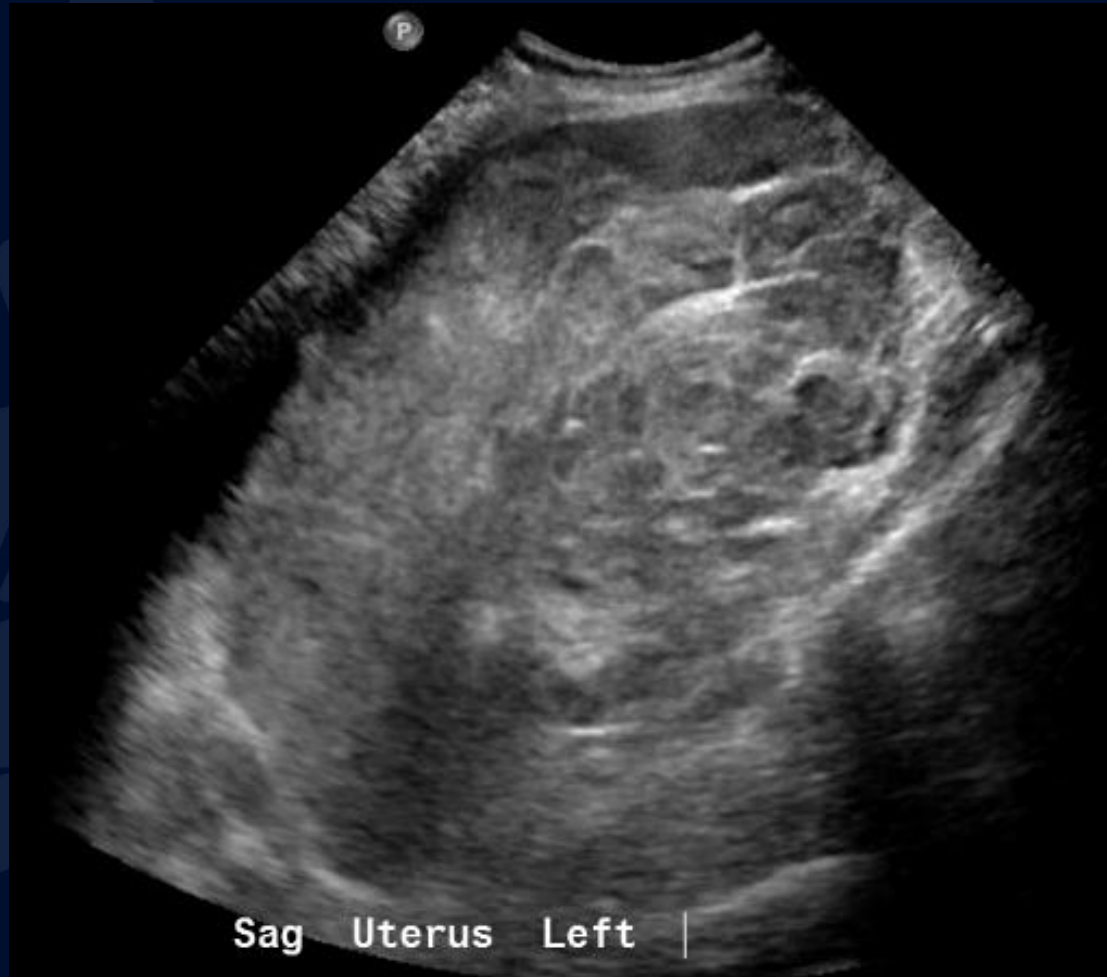

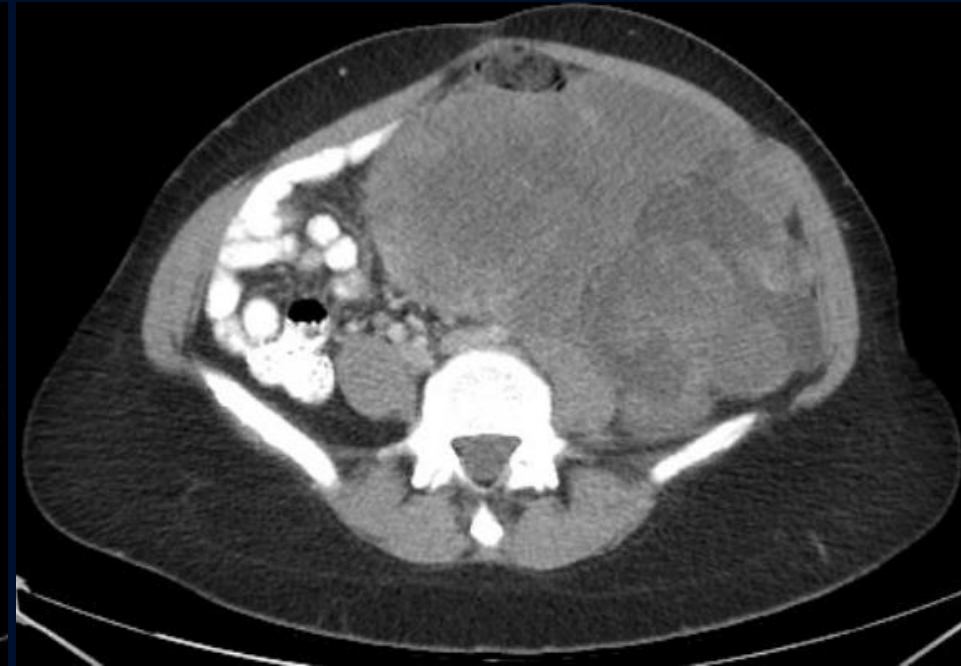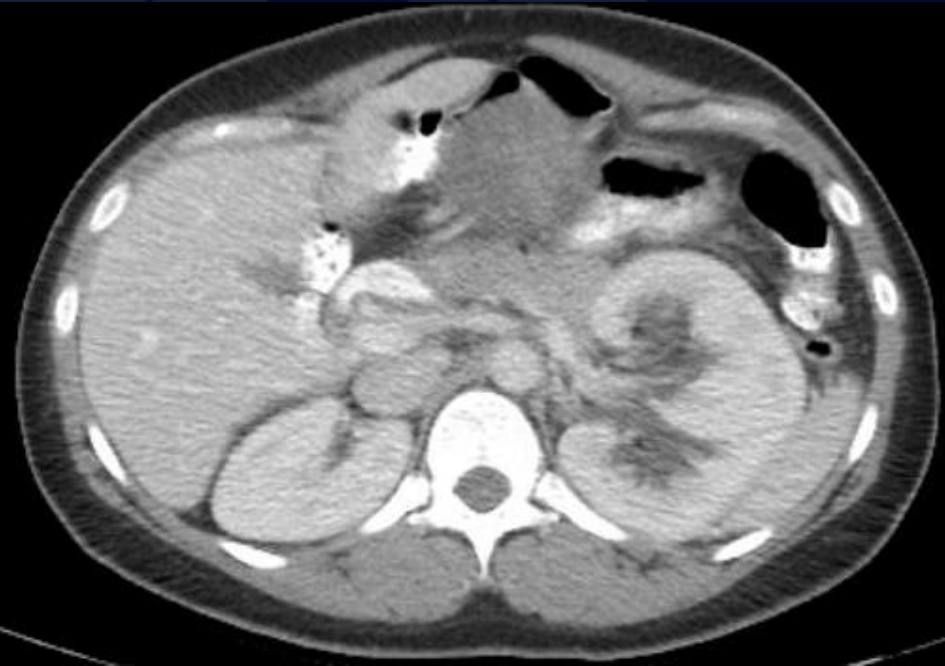33-year-old female with
progressive abdominal pain and
distension

Natalia Kosyakova, MS3

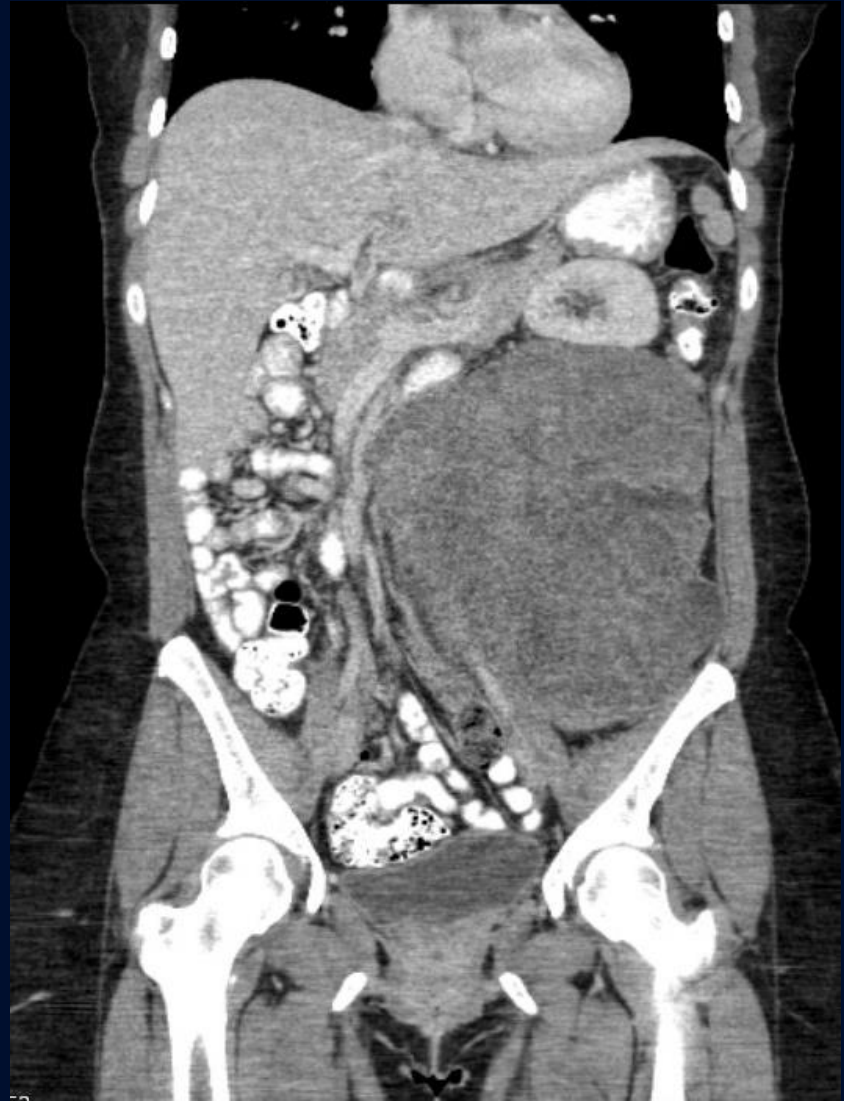
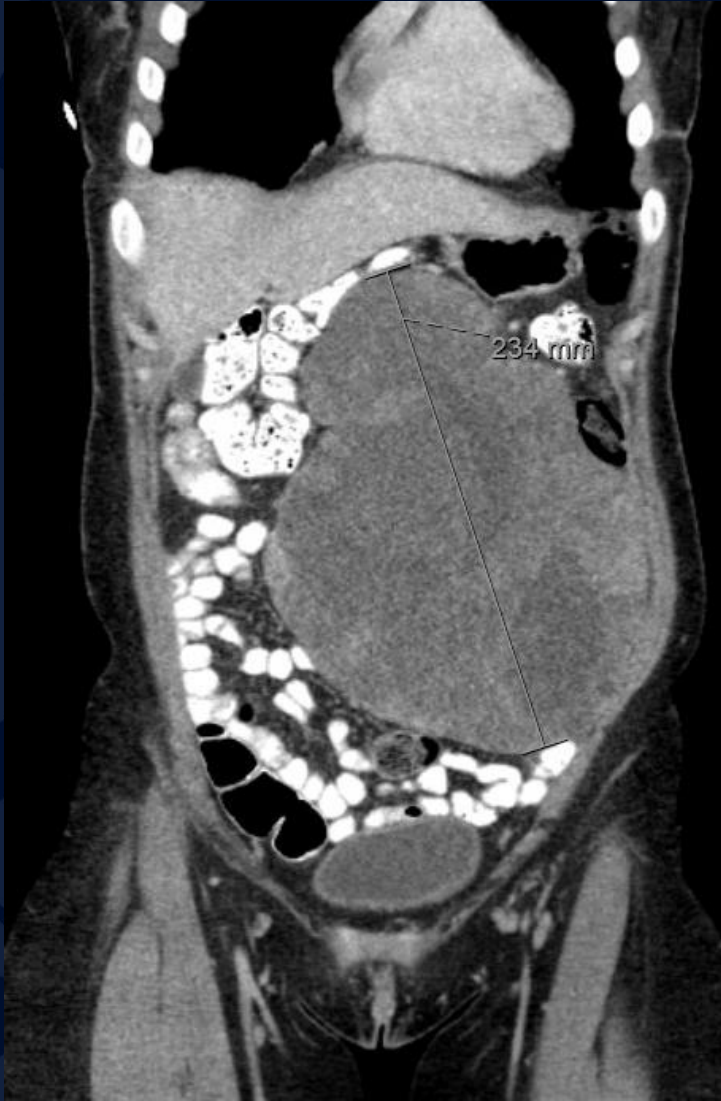Transabdominal Pelvic Ultrasound



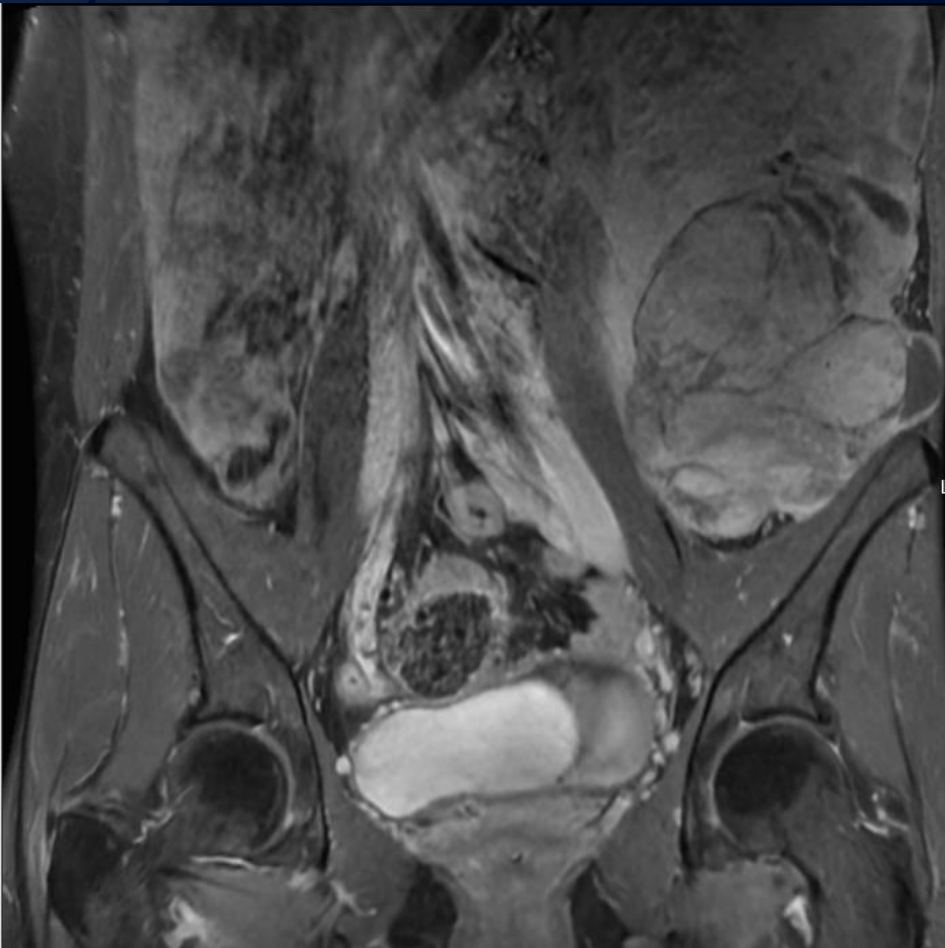CT IV Contrast



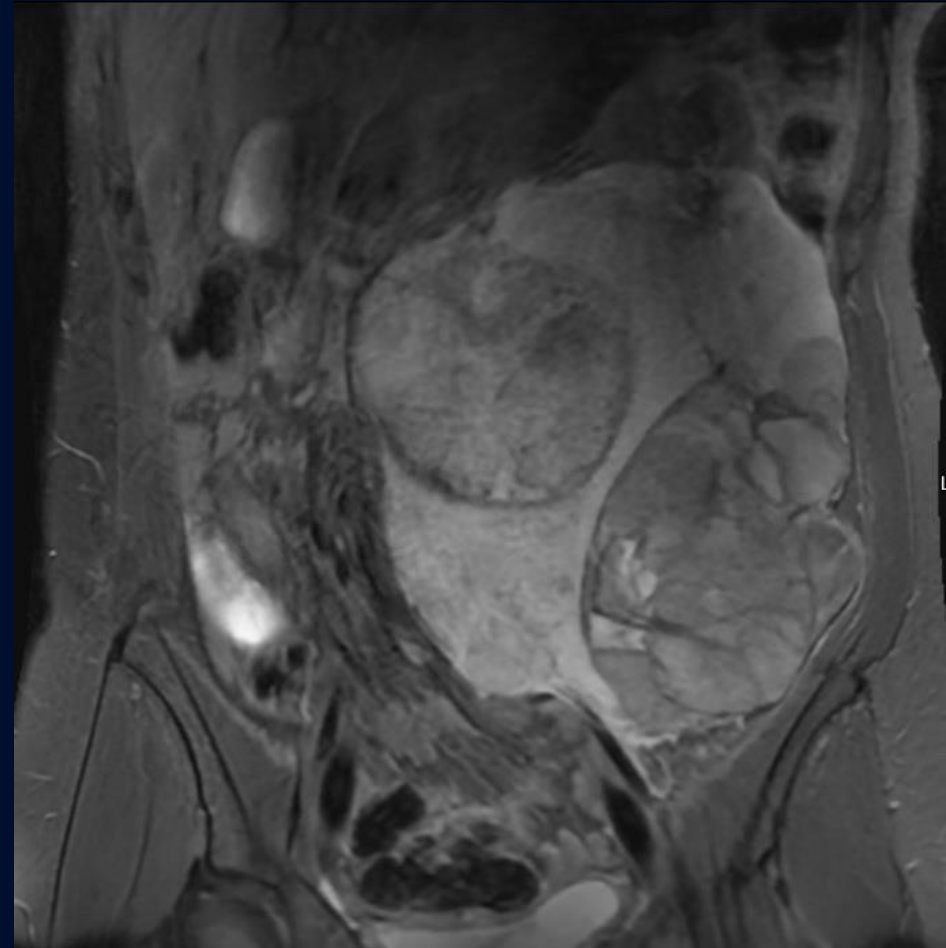
CT IV Contrast



T1 post-contrast



T2

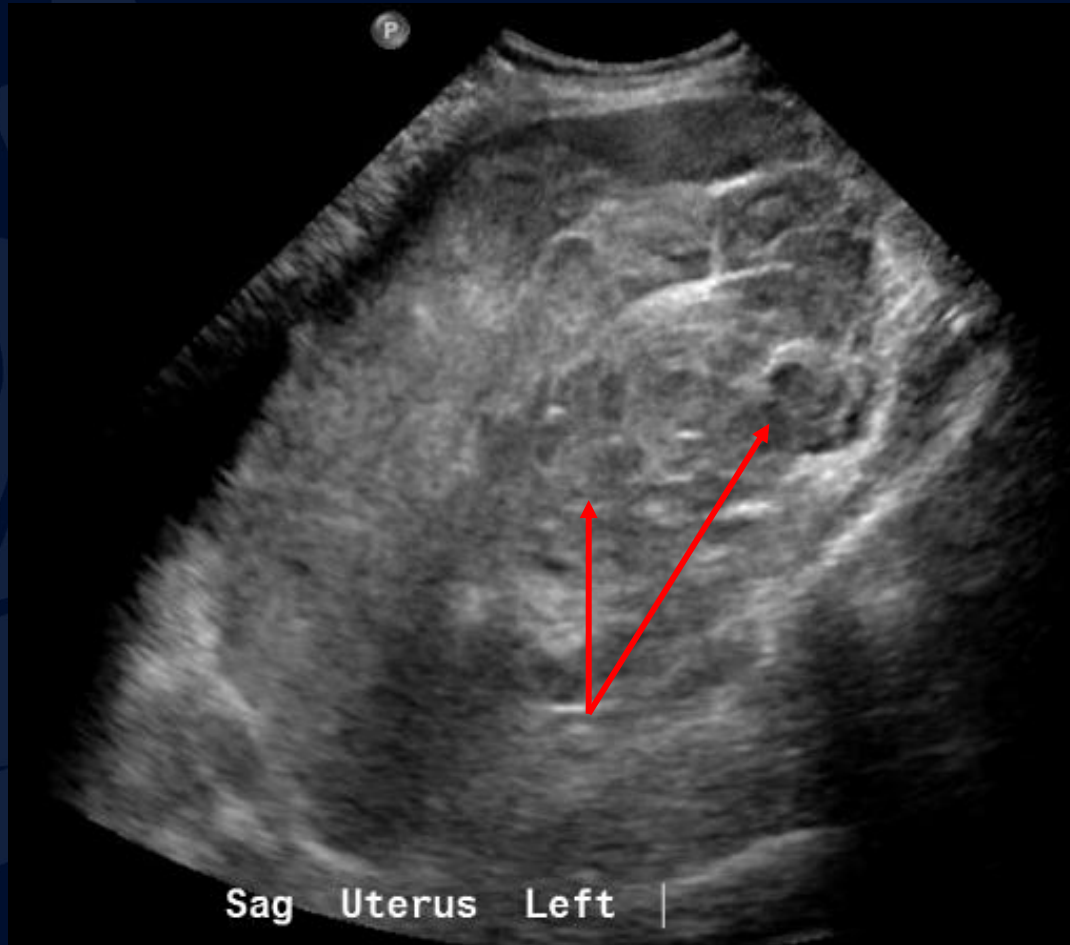


A large, stylized oak leaf graphic in a dark blue color, positioned on the left side of the slide. It features detailed vein patterns and a lobed edge.

?

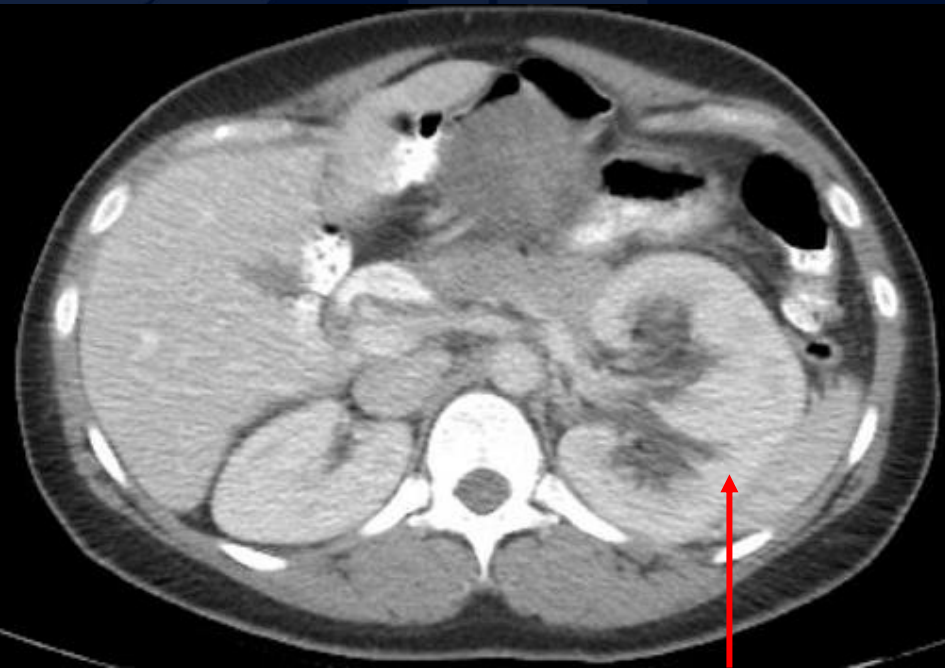Retroperitoneal Myxoid Liposarcoma

Transabdominal Pelvic Ultrasound

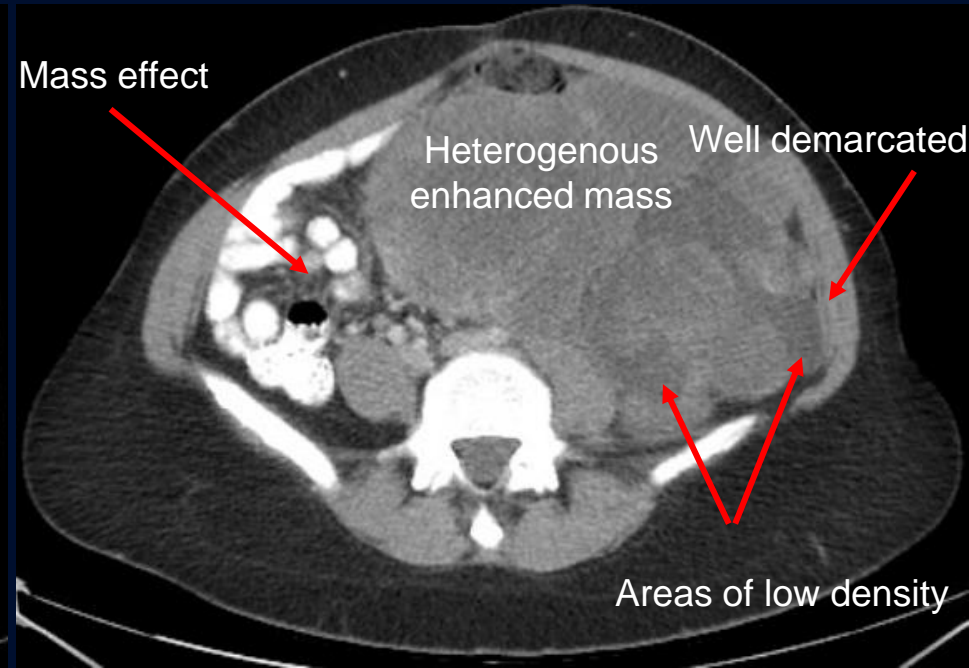


Heterogeneous predominantly hypoechoic masses

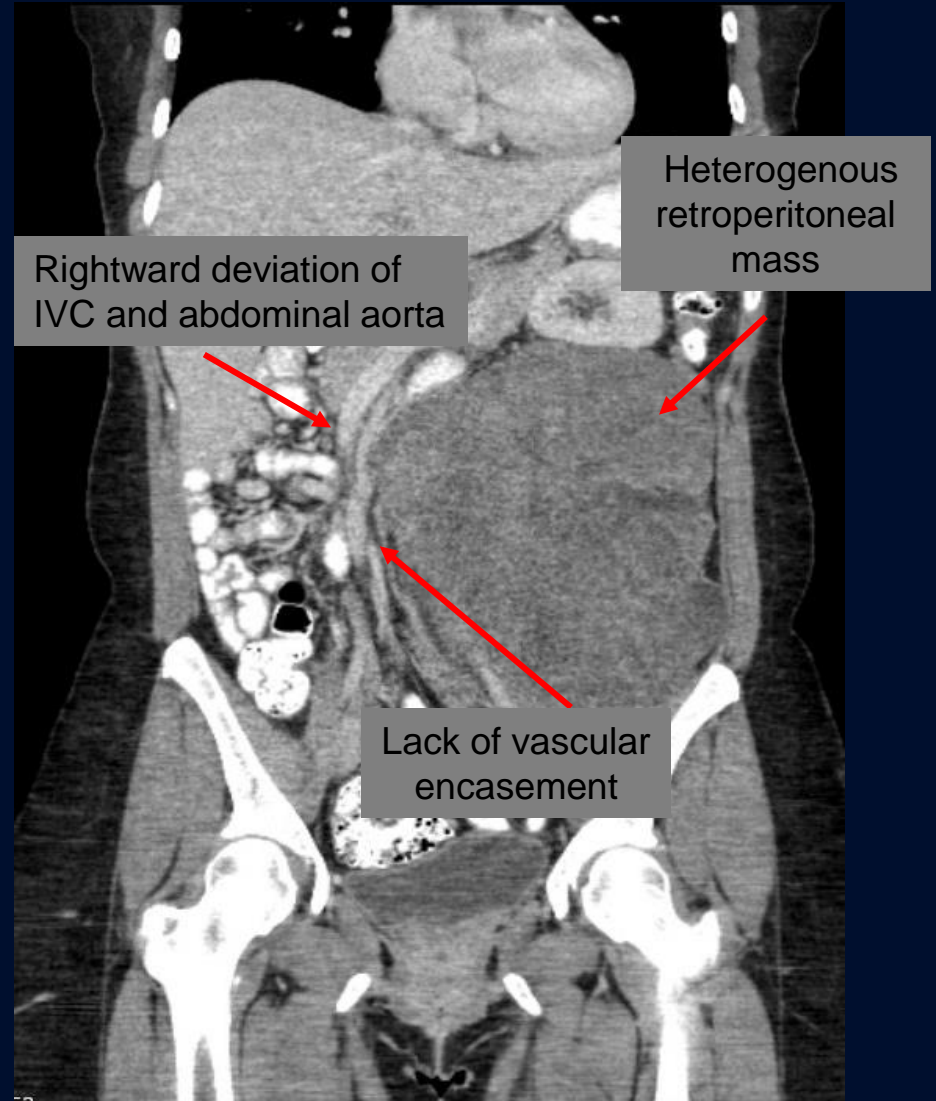
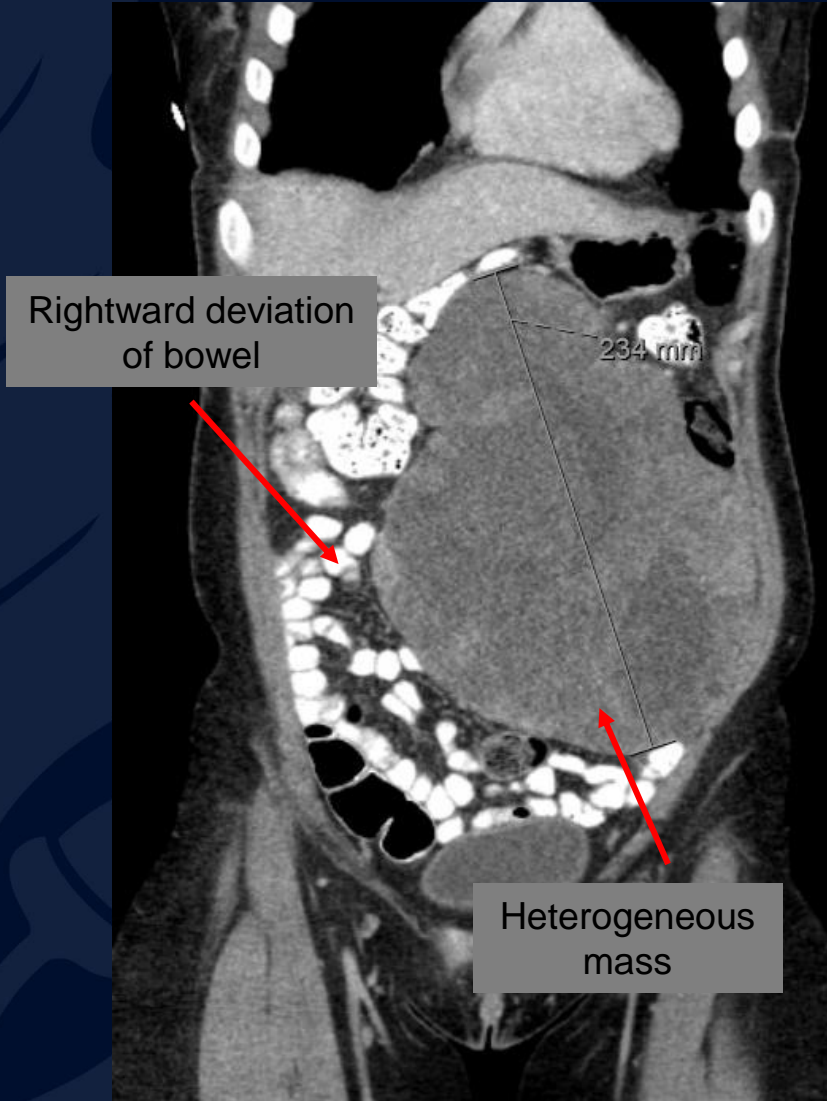
CT IV Contrast



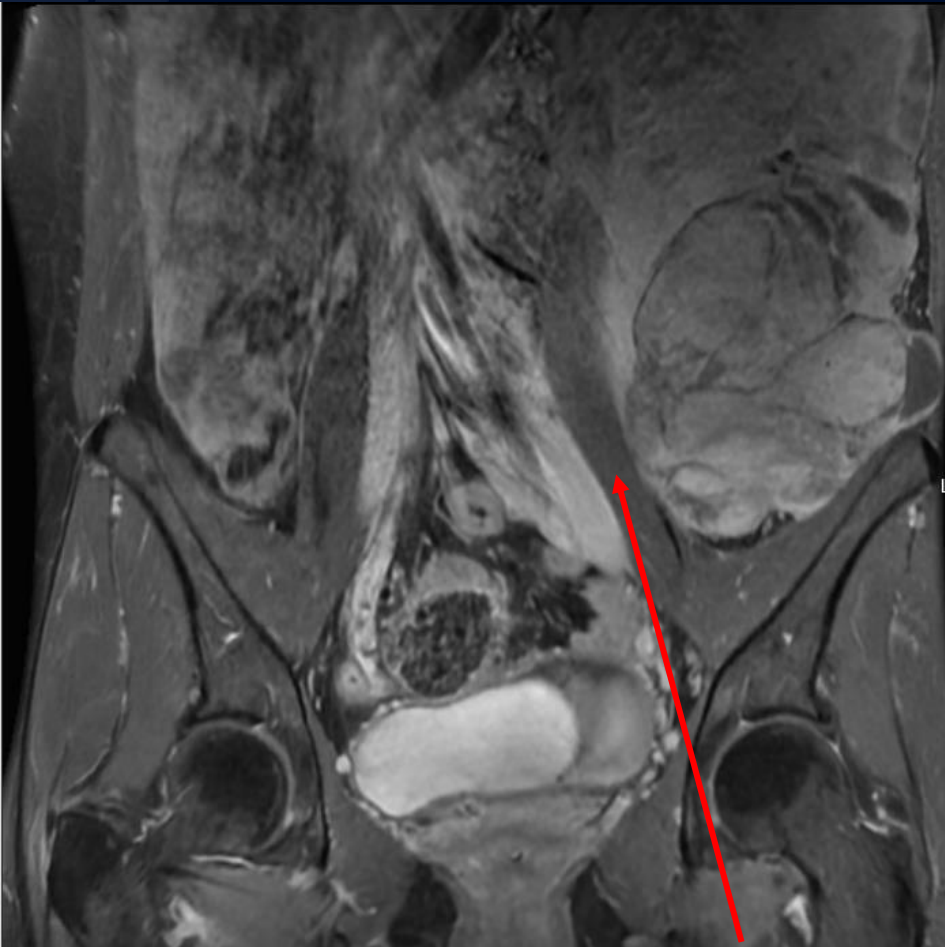Left renal enlargement, cortical thinning



CT IV Contrast

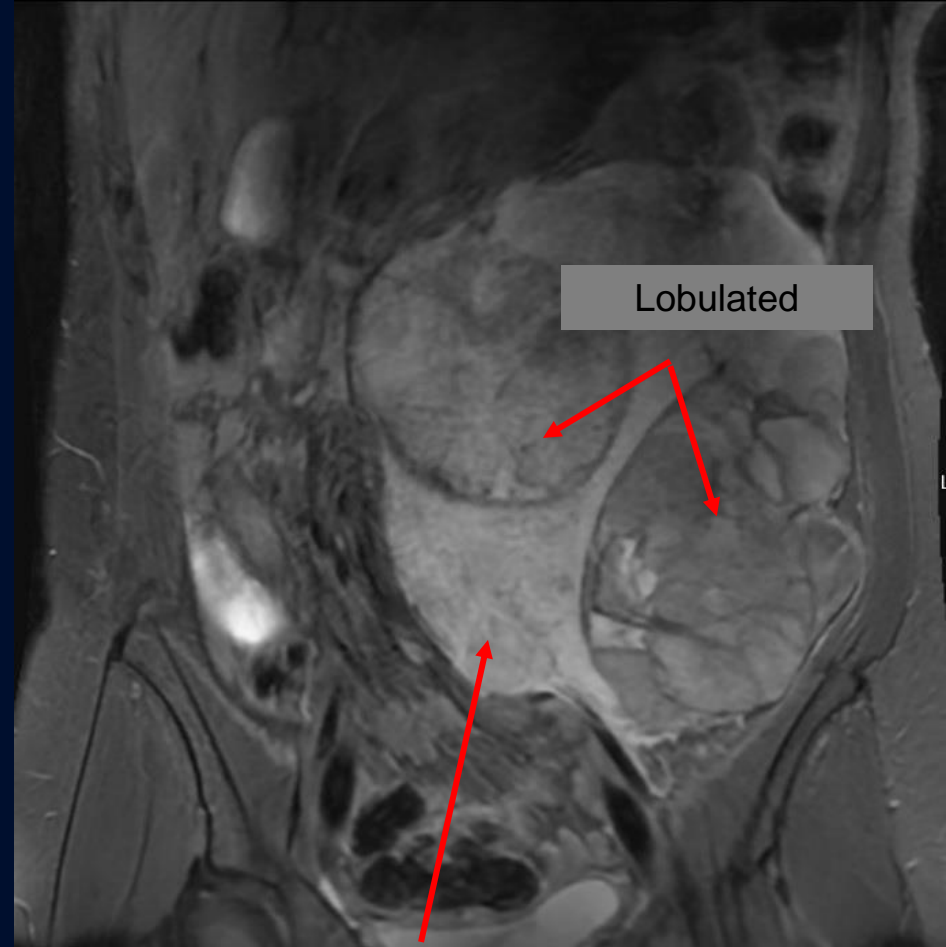


T1 post-contrast



Compression of left psoas muscle

T2



Hyperintense areas within
heterogenous mass

Retroperitoneal Myxoid Liposarcoma

- Rare, malignant heterogenous soft tissue tumor commonly classified based on histology with varying prognosis
 - Accounts for 15-20% of liposarcomas
 - Distant metastases develop in 30-60% with primary retroperitoneal tumors being rare
 - Metastases commonly to lung (83%), fascia (9%), lymph nodes (2.6%)
- Treatment
 - Wide surgical resection with adjuvant radiotherapy due to high grade liposarcoma
 - Outcomes: myxoid liposarcomas with >10% round cells have high likelihood of metastasis in the future

Imaging Findings

- CT
 - Heterogenous mass with enhancing soft tissue components
- MRI
 - T1
 - Hypointense mass with hyperintense lacy or linear foci (represent pockets of fat within tumor)
 - T2
 - Hyperintense mass due to myxoid matrix
 - Varying non-enhancing regions of mucinous material
 - Enhancing regions indicating high vascularity and cellularity

*Distinction with lipoma which appears isointense to subcutaneous fat on all sequences

References

- Abboud A, Masrouha K, Saliba M, et al. Extraskkeletal Ewing sarcoma: Diagnosis, management and prognosis. *Oncol Lett*. 2021;21(5):354.doi:10.3892/ol.2021.12615
- Choi JH, Ro JY. Retroperitoneal Sarcomas: An Update on the Diagnostic Pathology Approach. *Diagnostics (Basel)*. 2020;10(9):642. Published 2020 Aug 27. doi:10.3390/diagnostics10090642
- Loubignac F, Bourtoul C, Chapel F. Myxoid liposarcoma: a rare soft-tissue tumor with a misleading benign appearance. *World J Surg Oncol*. 2009;7:42. Published 2009 Apr 22. doi:10.1186/1477-7819-7-42
- Matthyssens LE, Creytens D, Ceelen WP. Retroperitoneal liposarcoma: current insights in diagnosis and treatment. *Front Surg*. 2015;2:4. Published 2015 Feb 10. doi:10.3389/fsurg.2015.00004
- Setsu N, Miyake M, Wakai S, et al. Primary Retroperitoneal Myxoid Liposarcomas. *Am J Surg Pathol*. 2016;40(9):1286-1290. doi:10.1097/PAS.0000000000000657
- van Vliet M, Kliffen M, Krestin GP, van Dijke CF. Soft tissue sarcomas at a glance: clinical, histological, and MR imaging features of malignant extremity soft tissue tumors. *Eur Radiol*. 2009;19(6):1499-1511. doi:10.1007/s00330-008-1292-3