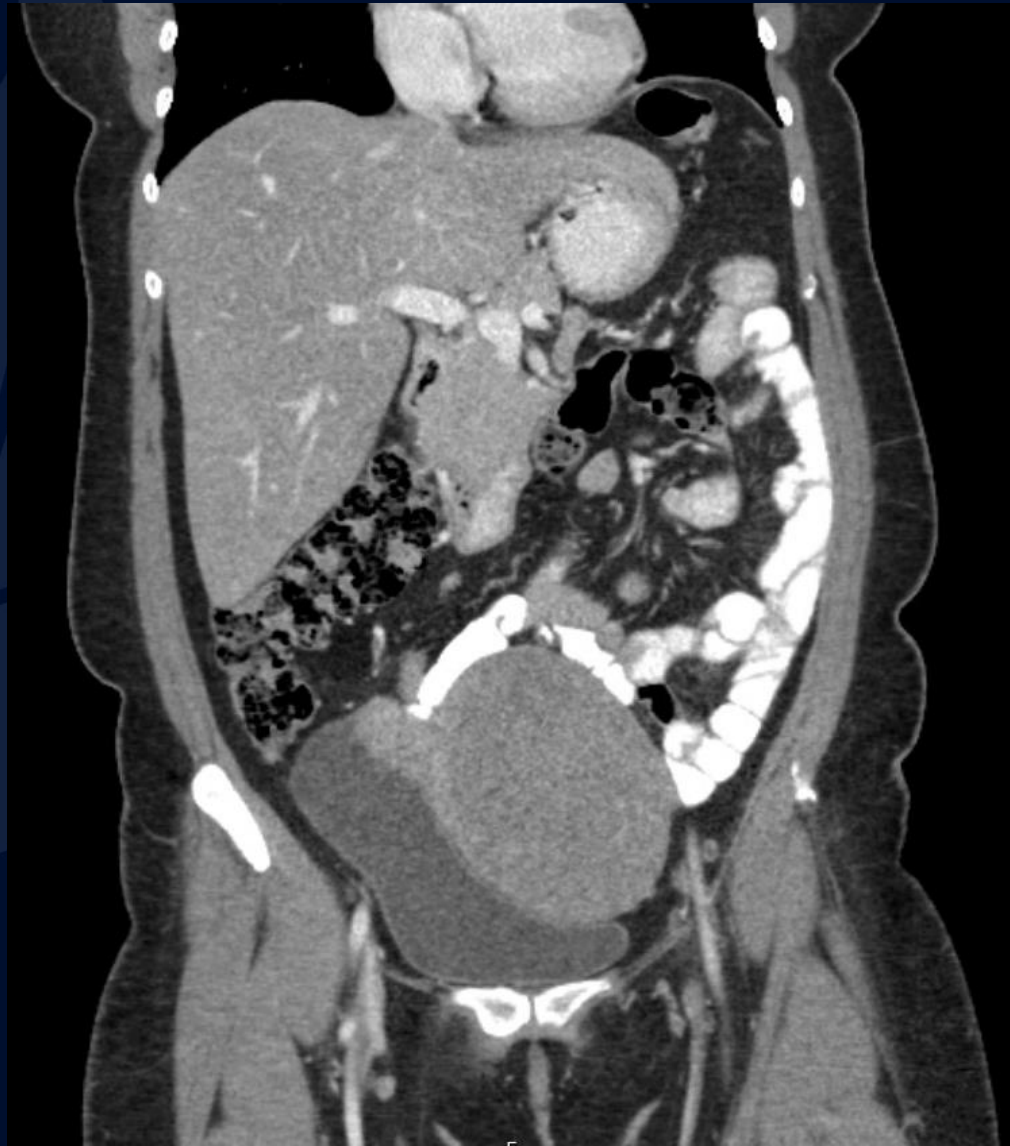

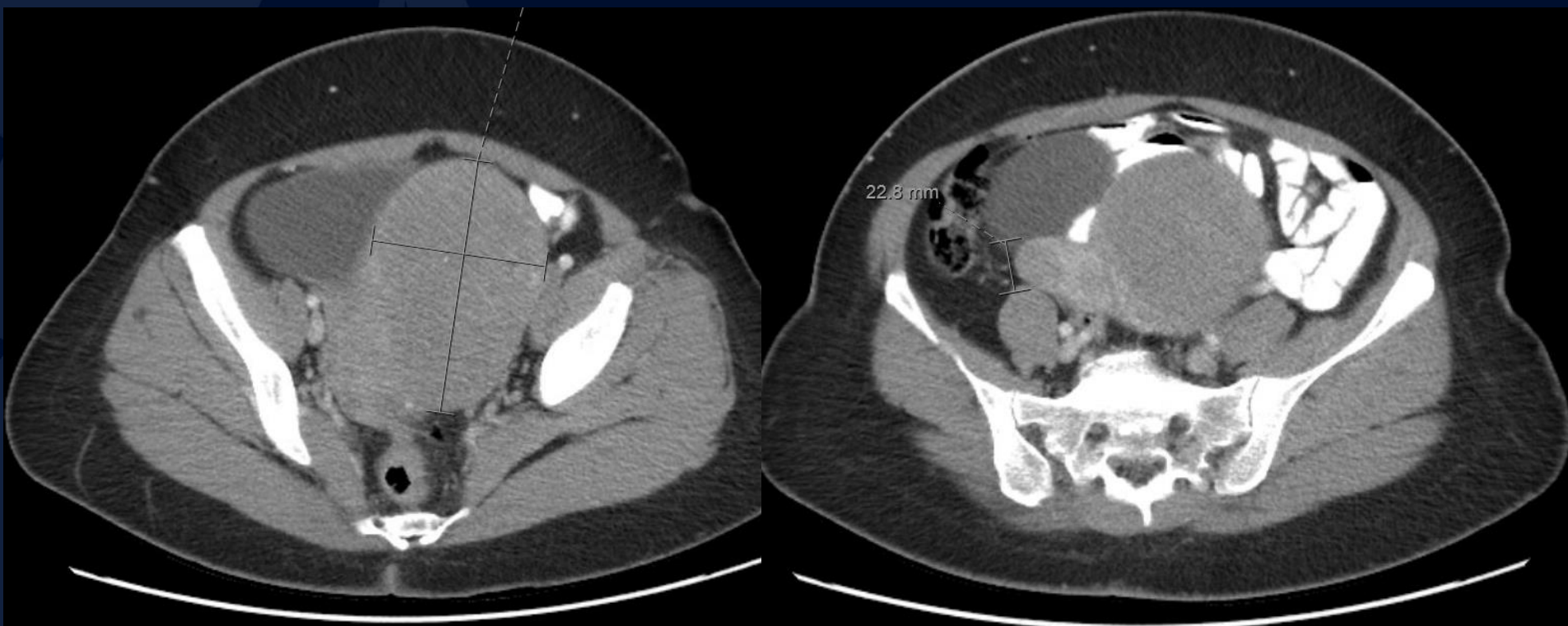
# 54-year-old female with history of endometriosis presenting with 2 weeks of left lower quadrant pain

Jennifer Casparino, MS3

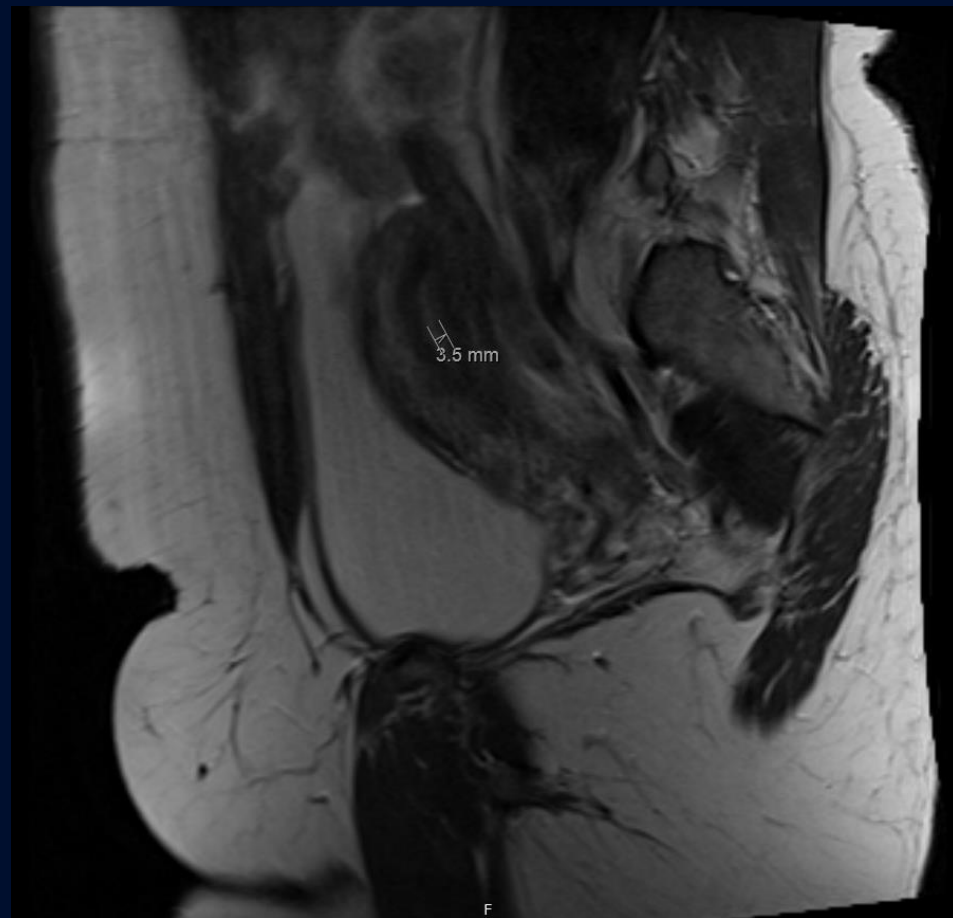
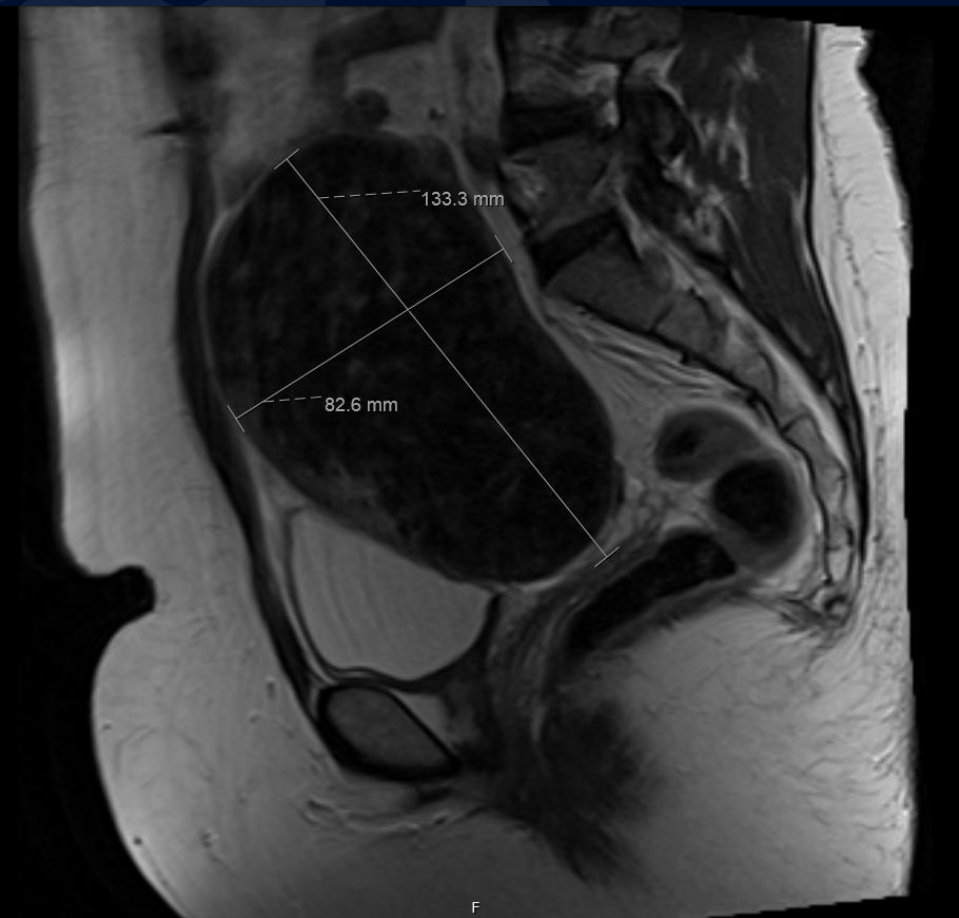
# CT IV Contrast



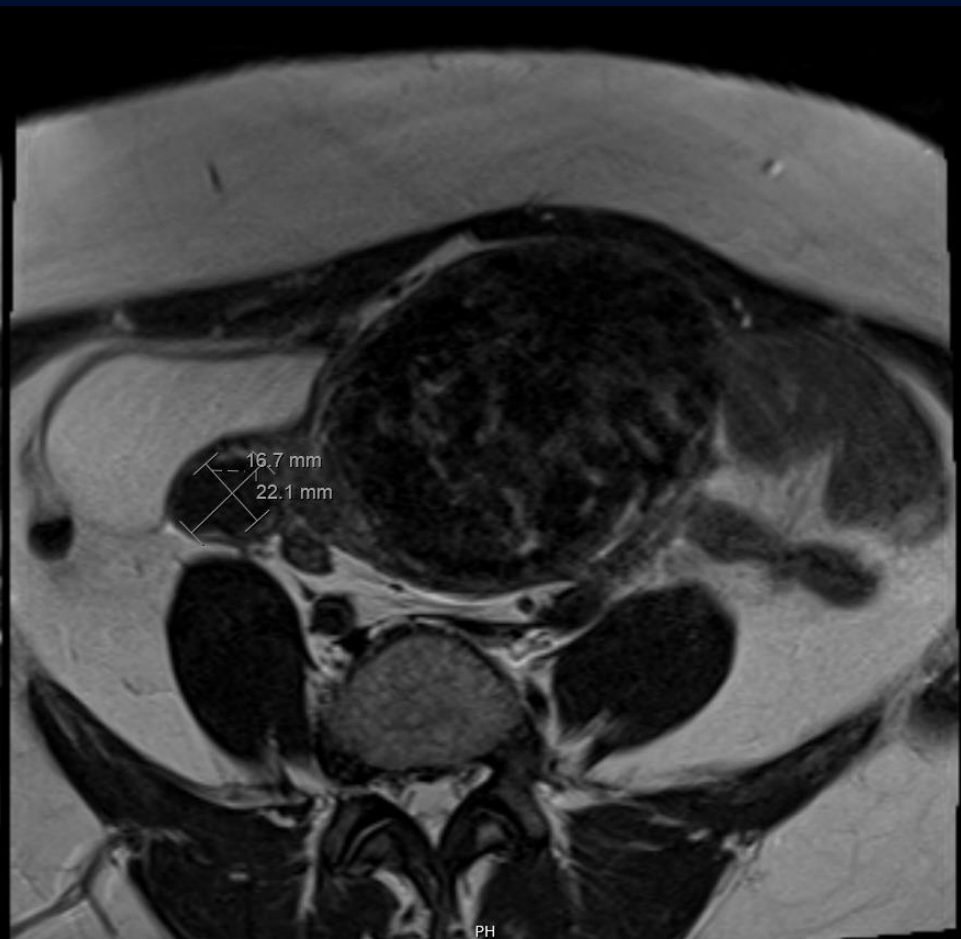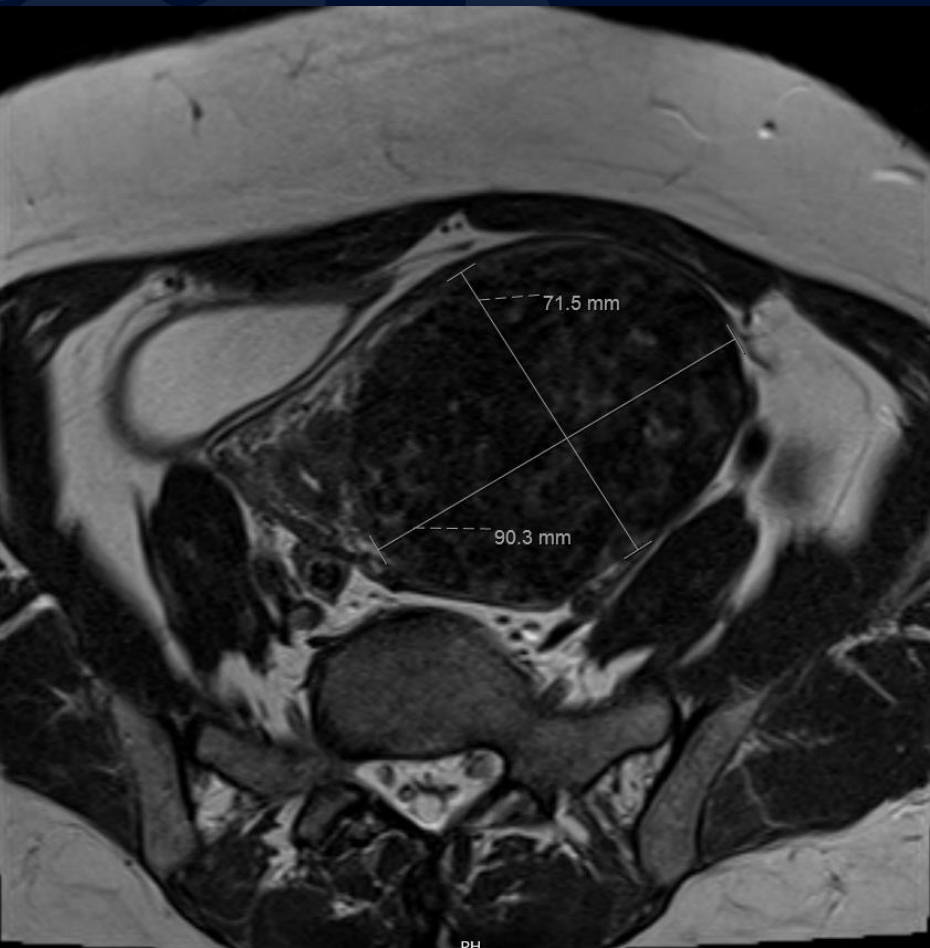
# CT IV Contrast



# T2 Sagittal



# T2 Axial





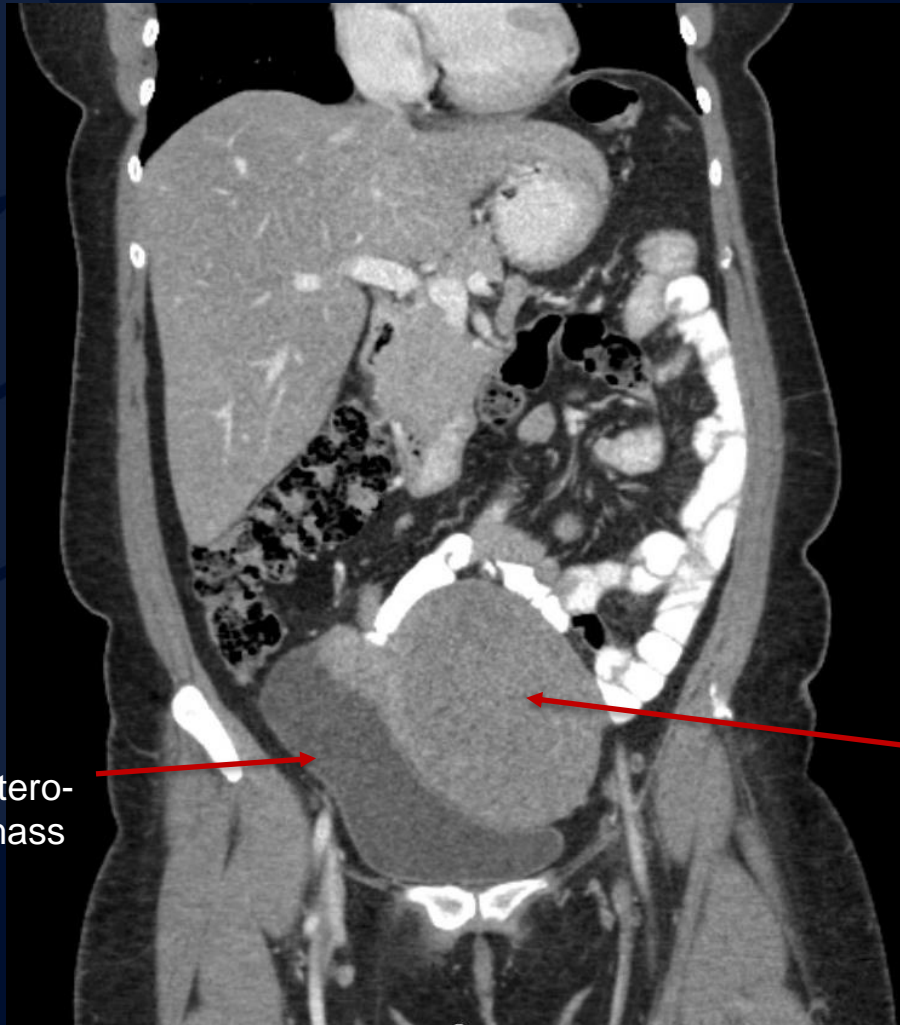


?

# Uterine Leiomyoma (Fibroid)

# CT IV Contrast

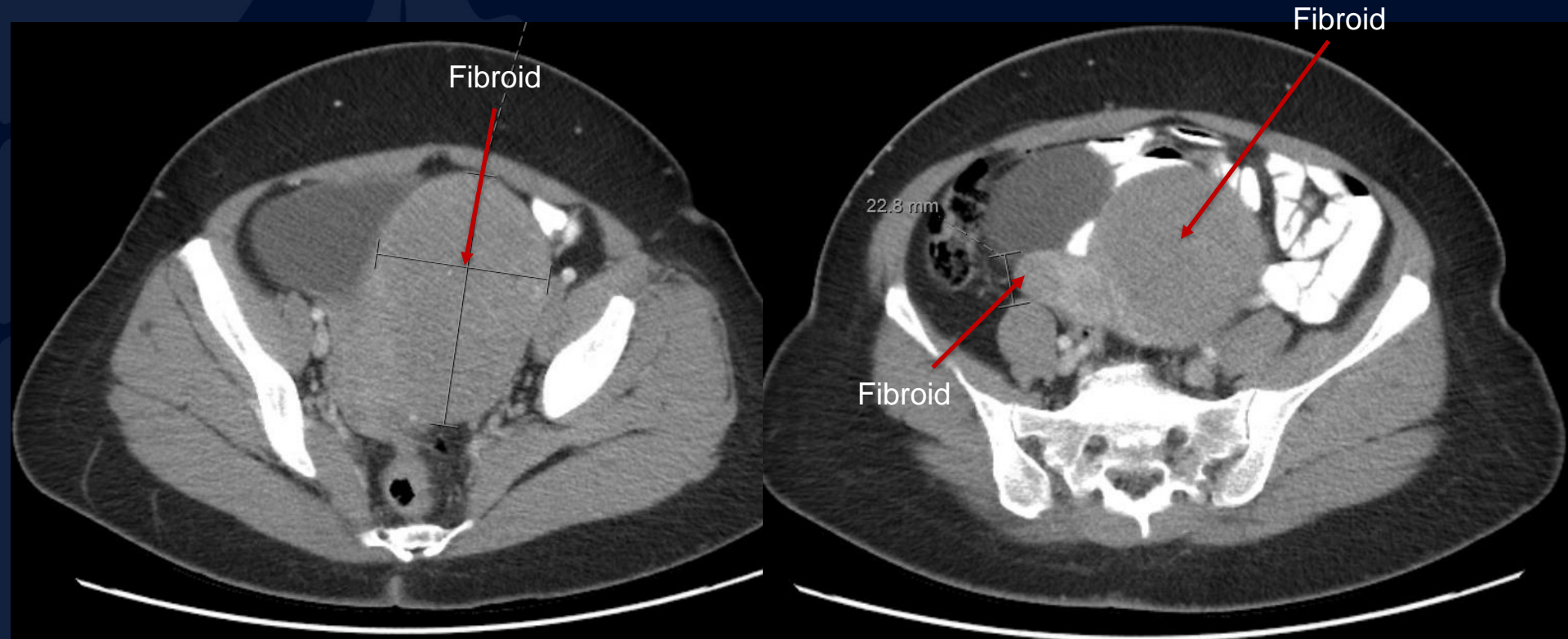
Bladder,  
displaced antero-  
laterally by mass



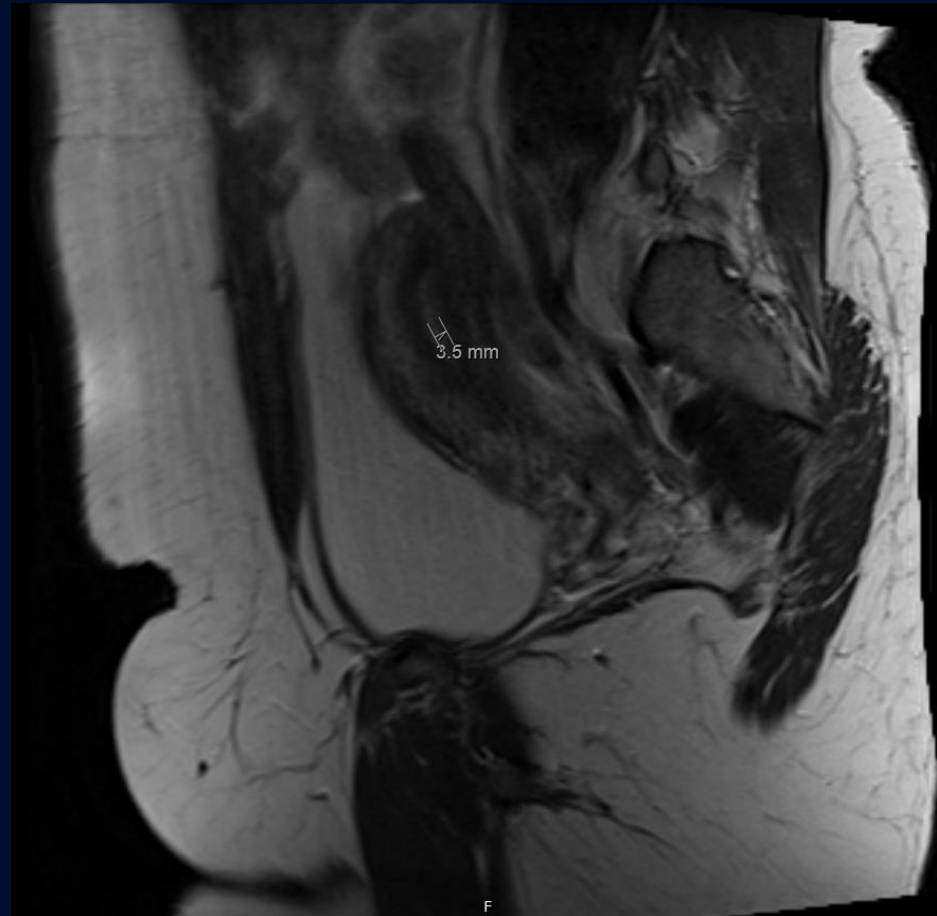
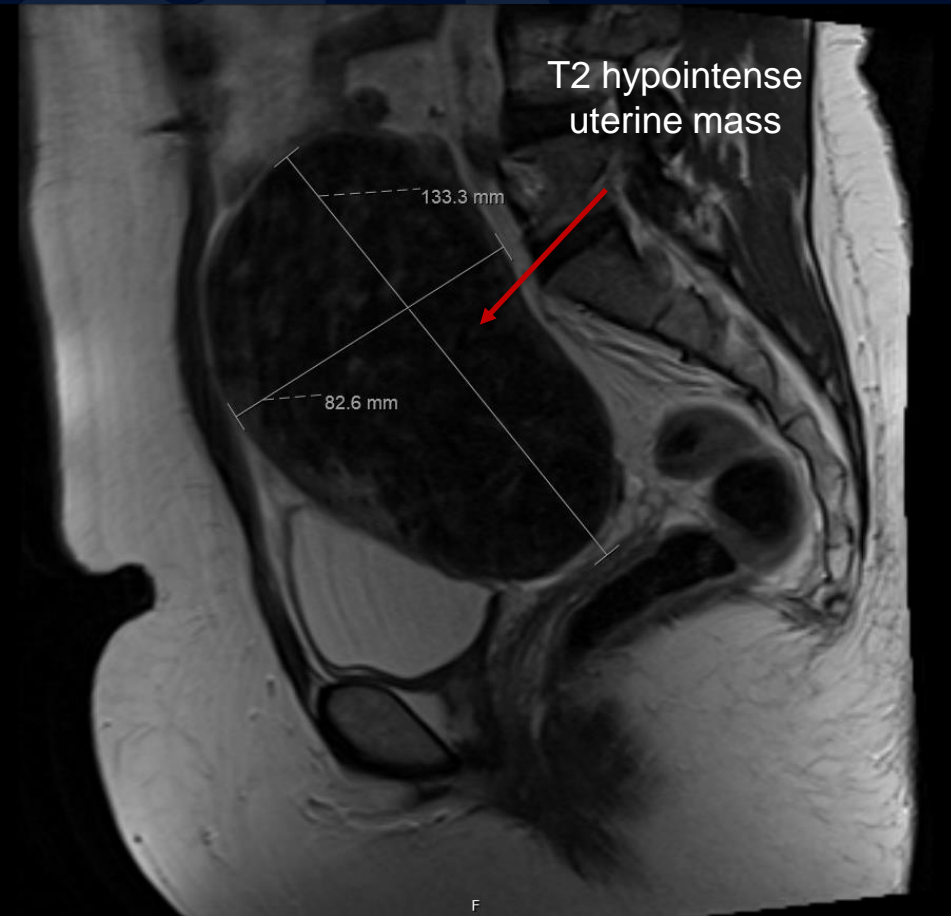
Leiomyoma,  
hypodense relative to  
normal uterus



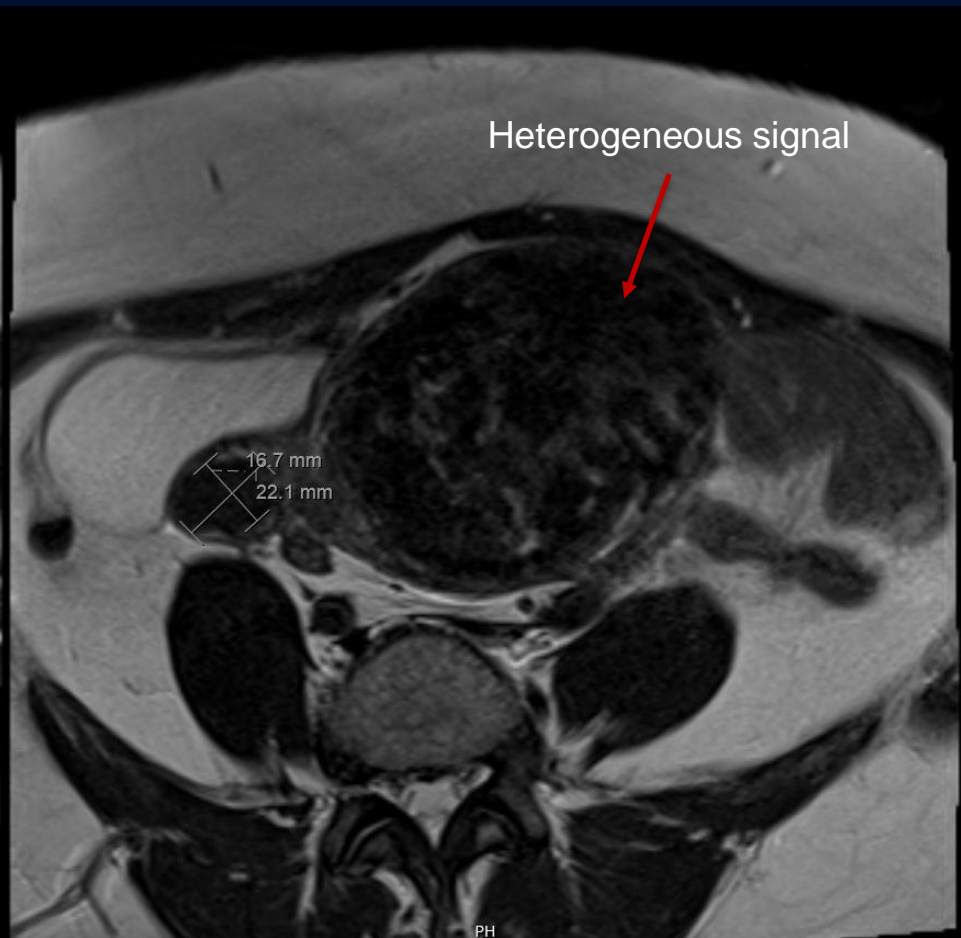
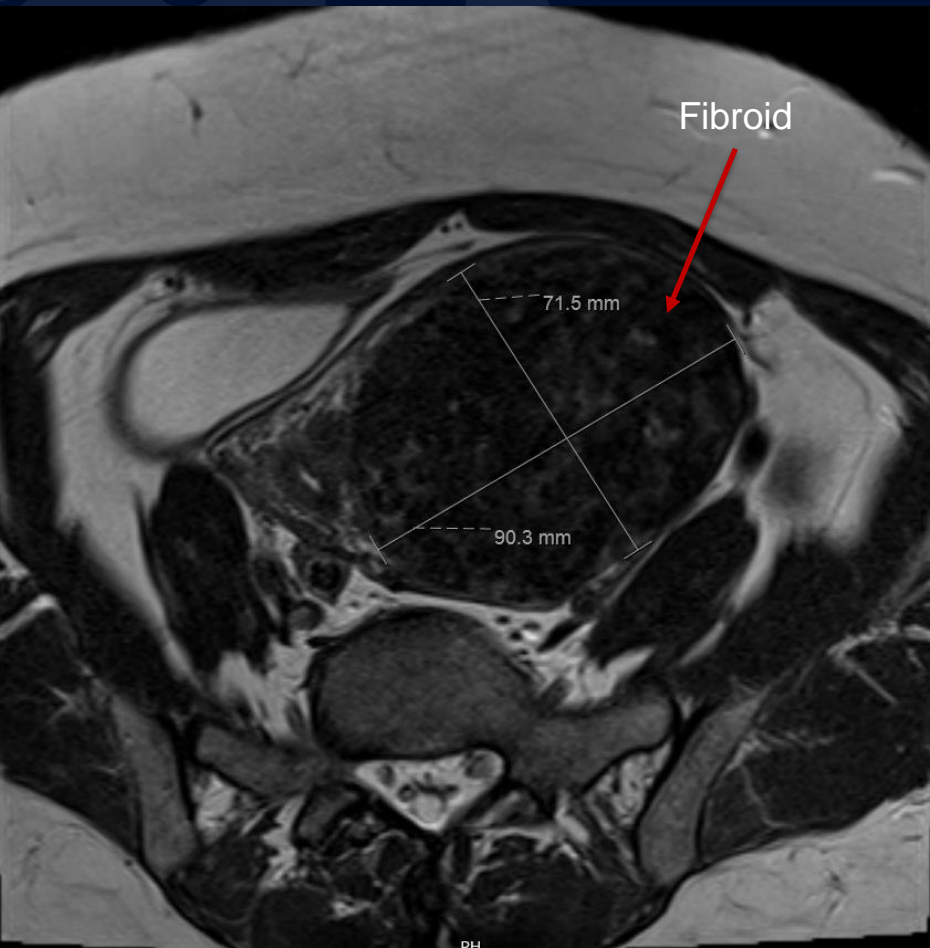
# CT IV Contrast



# T2 Sagittal



# T2 Axial



# Uterine Leiomyoma

Uterine leiomyoma (fibroid or myoma): benign monoclonal tumors arising from the myometrial smooth muscle cells and fibroblasts

- Most common pelvic neoplasm in females
- Arise in reproductive-aged females
- If symptomatic, present with abnormal uterine bleeding +/- pelvic pain
- May have negative reproductive effects such as infertility and adverse pregnancy outcomes
- Growth is responsive to estrogen and progesterone
- Described based on location in the uterus
  - Intramural, submucosal, subserosal, cervical, endocavitary

## Differential

- Leiomyosarcoma
- Lipoleiomyoma
- Focal adenomyosis
- Endometrial carcinoma
- Adnexal mass (if leiomyoma is pedunculated)
- Focal myometrial contraction aka Braxton Hicks contraction (if seen during pregnancy)

# Imaging Findings

## Ultrasound

- Bulky uterine enlargement with heterogeneous echotexture
- Circumscribed mass, hypoechoic to myometrium, poor posterior acoustic shadowing
- Peripheral vascularity

## CT

- Enlarged lobular uterus
- Fibroid attenuation is similar to uterus on unenhanced scan
- Variable enhancement with contrast
- +/- coarse, dense calcifications
- +/- heterogeneity if cystic degeneration or hemorrhage is present.

## MR

- Low T1/T2 signal
  - High T1 signal if hemorrhage
  - High T2 signal if cystic
- Variable enhancement, most often less enhancement than the surrounding myometrium
- After uterine artery embolization, decreased volume and enhancement is expected



# References

- Lane, Barton, and Henal Motiwala. "Leiomyoma | STATdx." *App.statdx.com*, [app.statdx.com/document/leiomyoma/5dfa6523-f294-4828-99e8-75892db544a0?term=Leiomyoma&searchType=documents&category=All](https://app.statdx.com/document/leiomyoma/5dfa6523-f294-4828-99e8-75892db544a0?term=Leiomyoma&searchType=documents&category=All). Accessed 9 Sept. 2023.
- Memarzadeh, S., & Berek, J. S. (2023, February 13). Uterine sarcoma: Classification, epidemiology, clinical manifestations, and diagnosis. UpToDate. Retrieved April 16, 2023, from <https://www.uptodate.com/home>
- Rha SE, Byun JY, Jung SE, Lee SL, Cho SM, Hwang SS, Lee HG, Namkoong SE, Lee JM. CT and MRI of uterine sarcomas and their mimickers. *AJR Am J Roentgenol*. 2003 Nov;181(5):1369-74. doi: 10.2214/ajr.181.5.1811369. PMID: 14573436.
- Stewart, E. A. (2022, July 1). Uterine fibroids (leiomyomas): Differentiating fibroids from uterine sarcomas. UpToDate. Retrieved April 16, 2023, from <https://www.uptodate.com/home>
- Stewart, E. A., & Laughlin-Tommaso, S. K. (2023, January 17). Uterine fibroids (leiomyomas): Epidemiology, clinical features, diagnosis, and natural history. UpToDate. Retrieved April 16, 2023, from <https://www.uptodate.com/home>
- Tamai K, Koyama T, Saga T, Morisawa N, Fujimoto K, Mikami Y, Togashi K. The utility of diffusion-weighted MR imaging for differentiating uterine sarcomas from benign leiomyomas. *Eur Radiol*. 2008 Apr;18(4):723-30. doi: 10.1007/s00330-007-0787-7. Epub 2007 Oct 10. PMID: 17929022.
- Troiano RN, Flynn SD, McCarthy S. Cystic adenomyosis of the uterus: MRI. *J Magn Reson Imaging*. 1998 Nov-Dec;8(6):1198-202. doi: 10.1002/jmri.1880080603. PMID: 9848728.
- Wilde S, Scott-Barrett S. Radiological appearances of uterine fibroids. *Indian J Radiol Imaging*. 2009 Jul-Sep;19(3):222-31. doi: 10.4103/0971-3026.54887. PMID: 19881092; PMCID: PMC2766886.