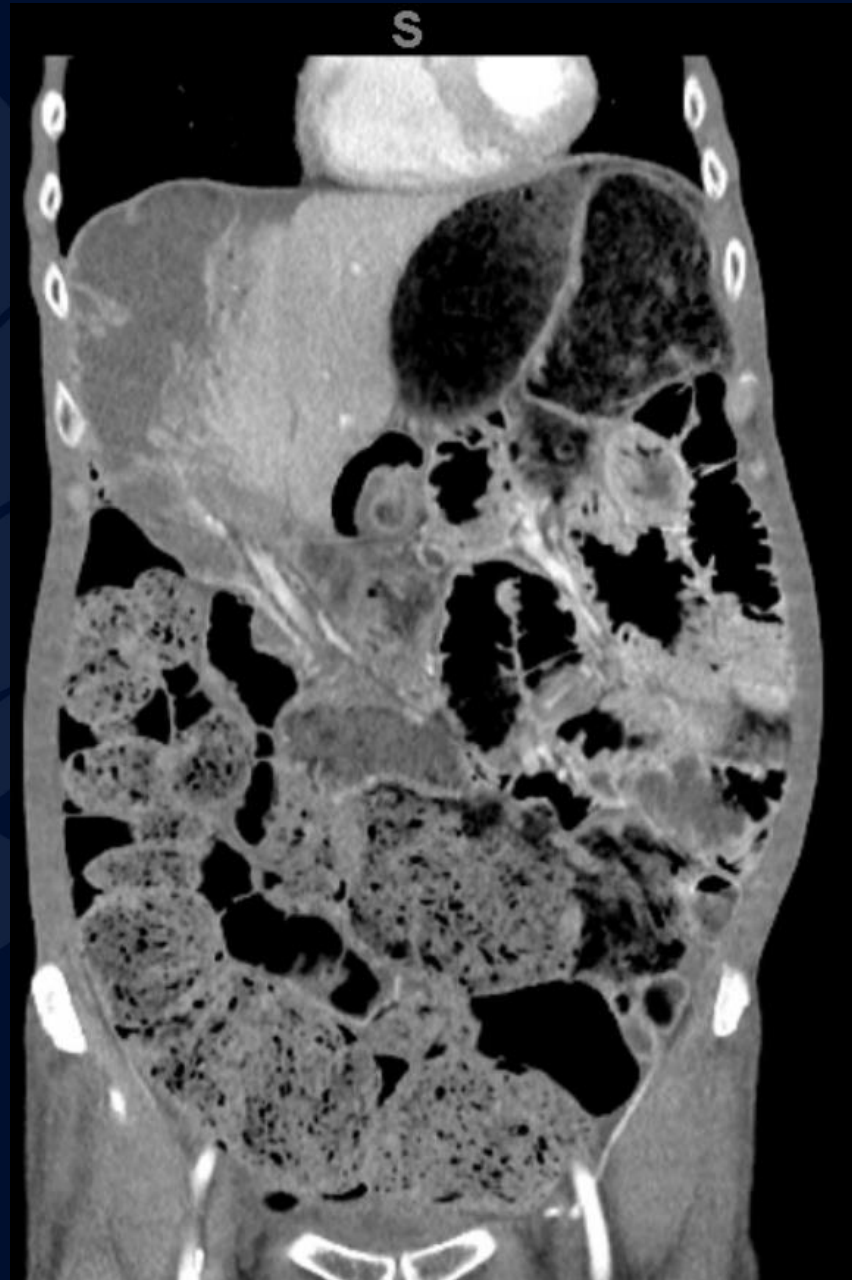


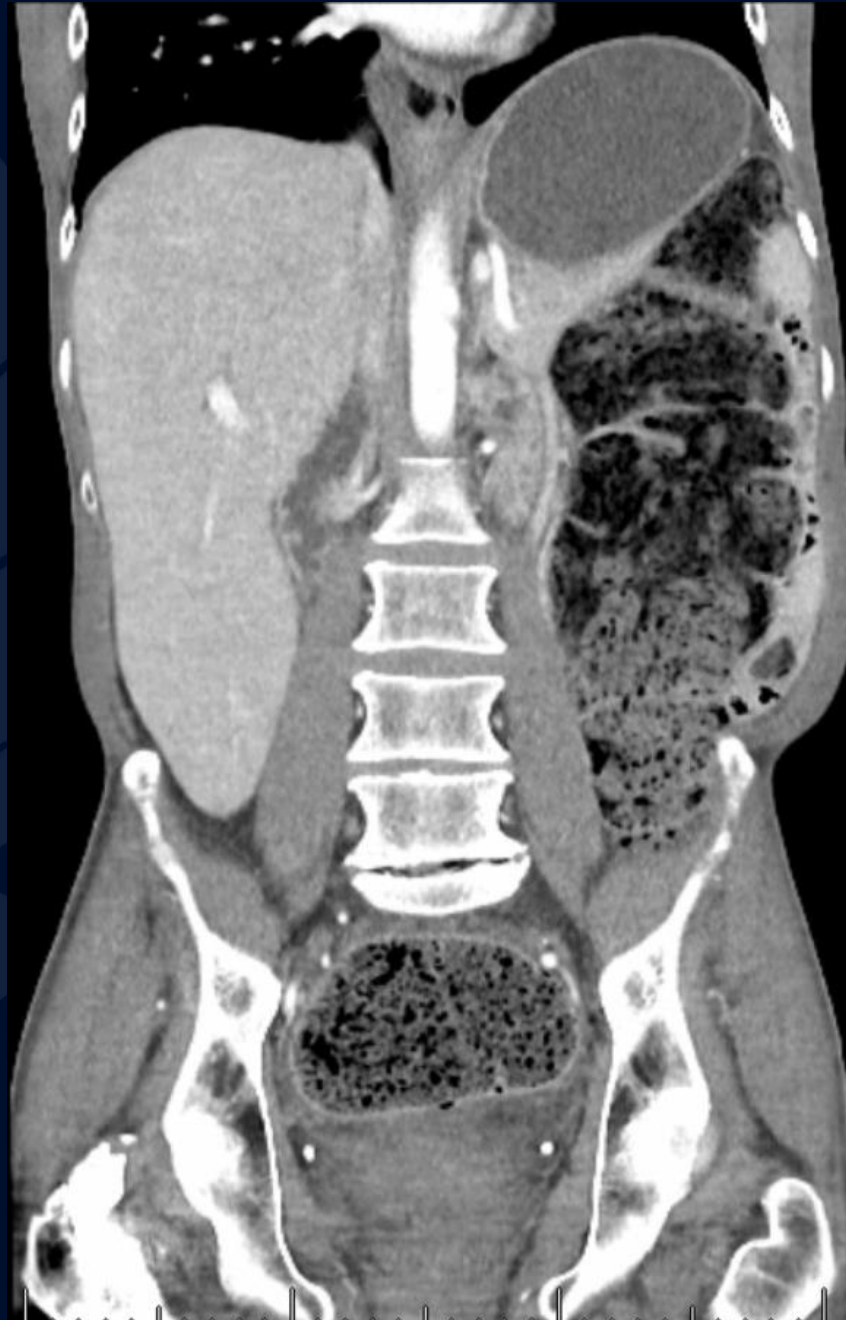66-year-old male presenting with
2-day history of severe
abdominal pain, nausea, vomiting
and dyspnea

Michael J. Taylor, MS3

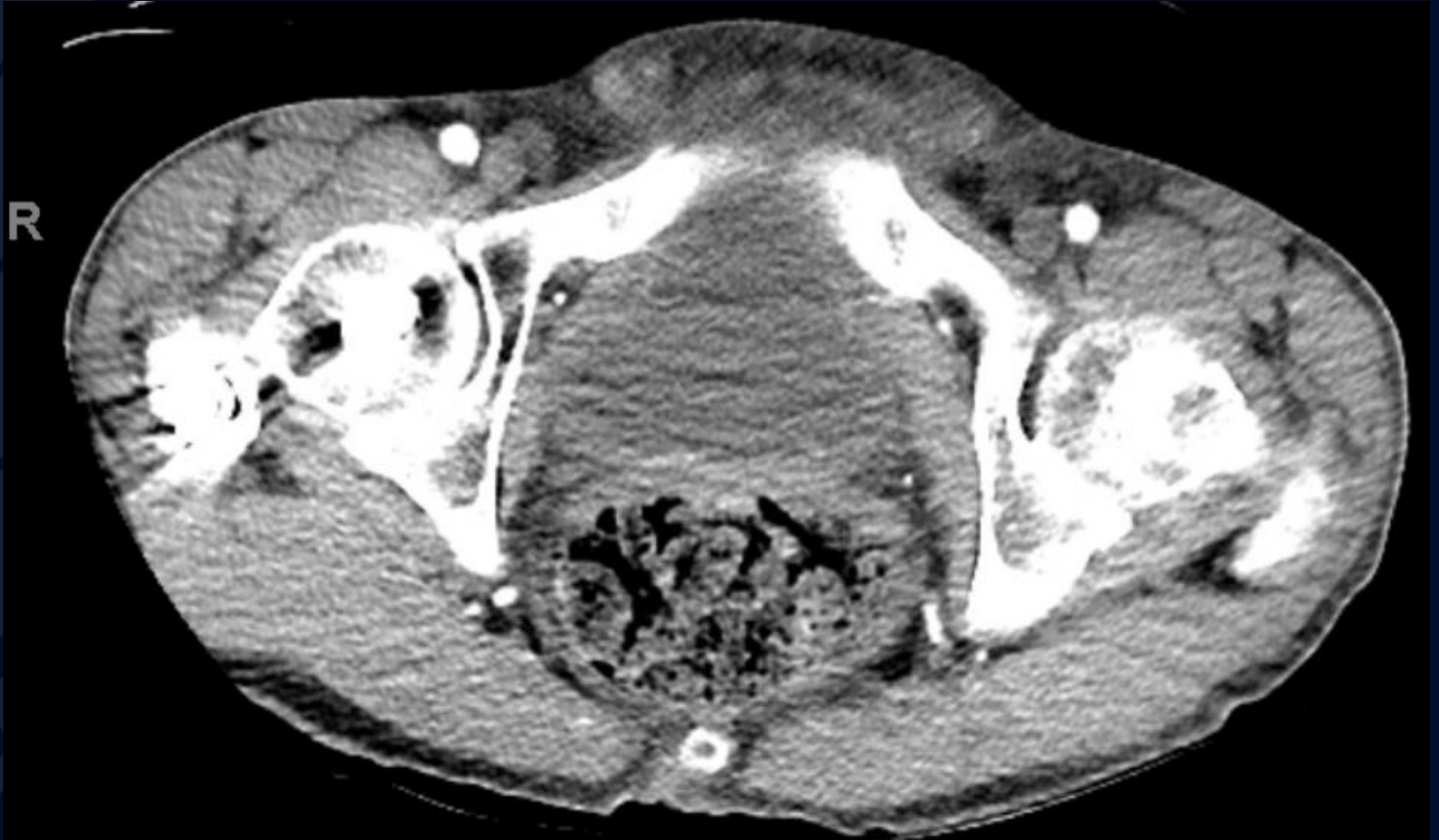CT IV Contrast



CT IV Contrast



CT IV Contrast



A large, stylized oak leaf graphic in a dark blue color, positioned on the left side of the slide. The leaf has a prominent central vein and several smaller veins branching off. The edges of the leaf are slightly wavy.

?

Stercoral Colitis

CT IV Contrast

Fluid filled
bowel at the
hepatic flexure



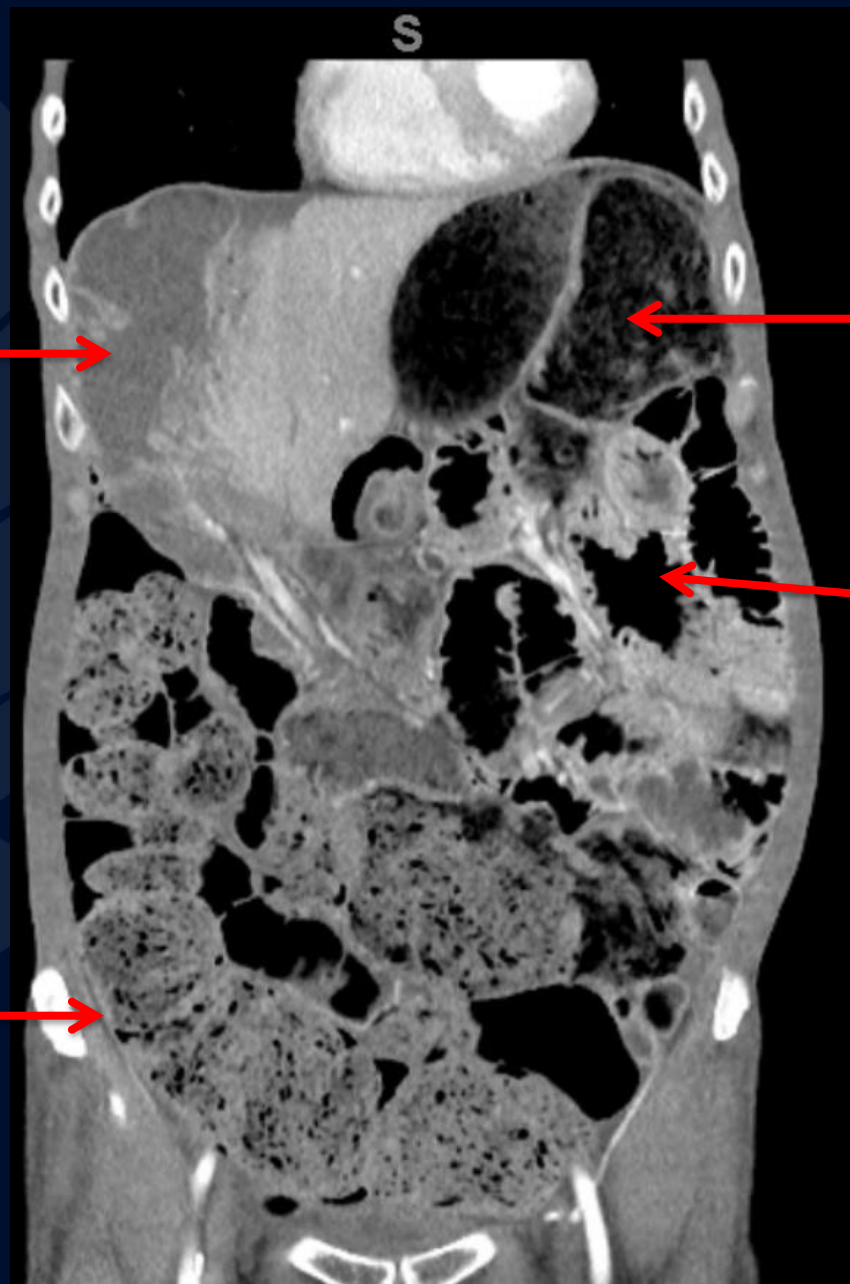
Dilated bowel
at the splenic
flexure



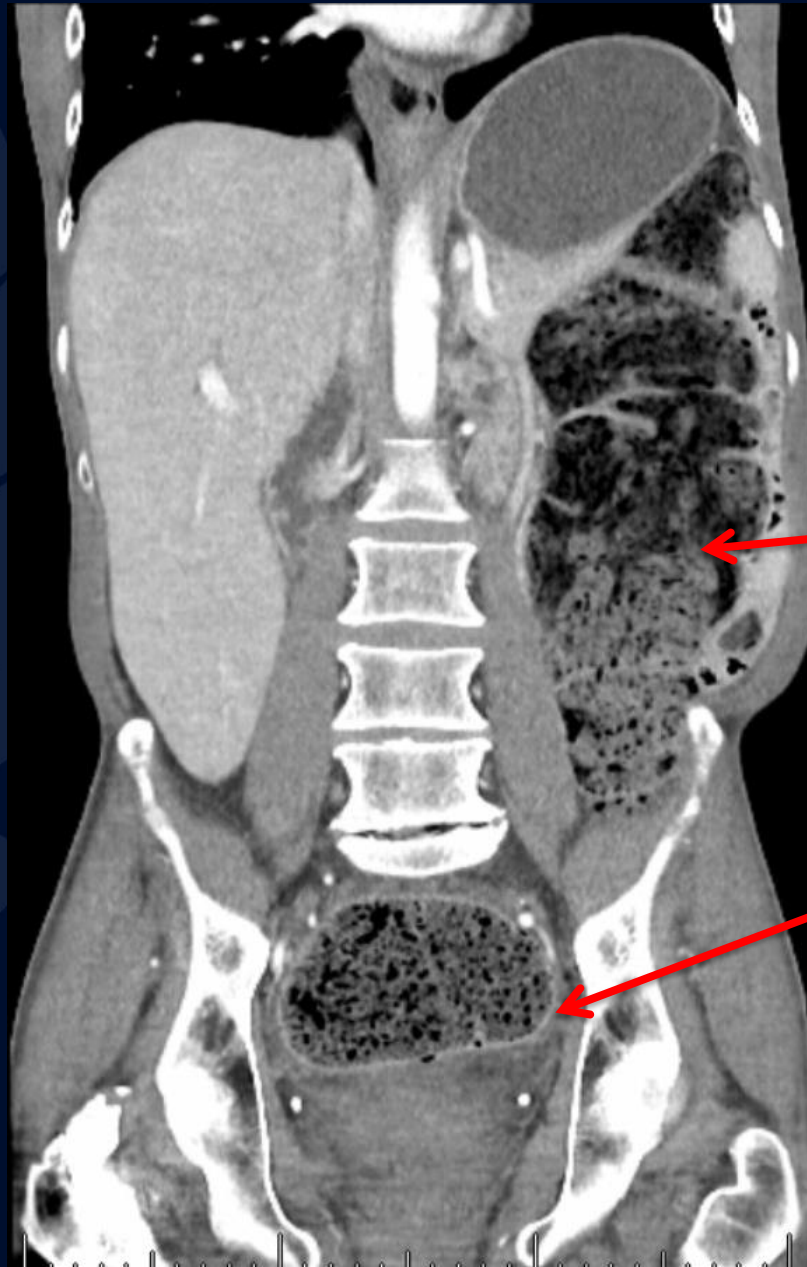Mildly dilated
small bowel



Stool-filled
ascending
colon



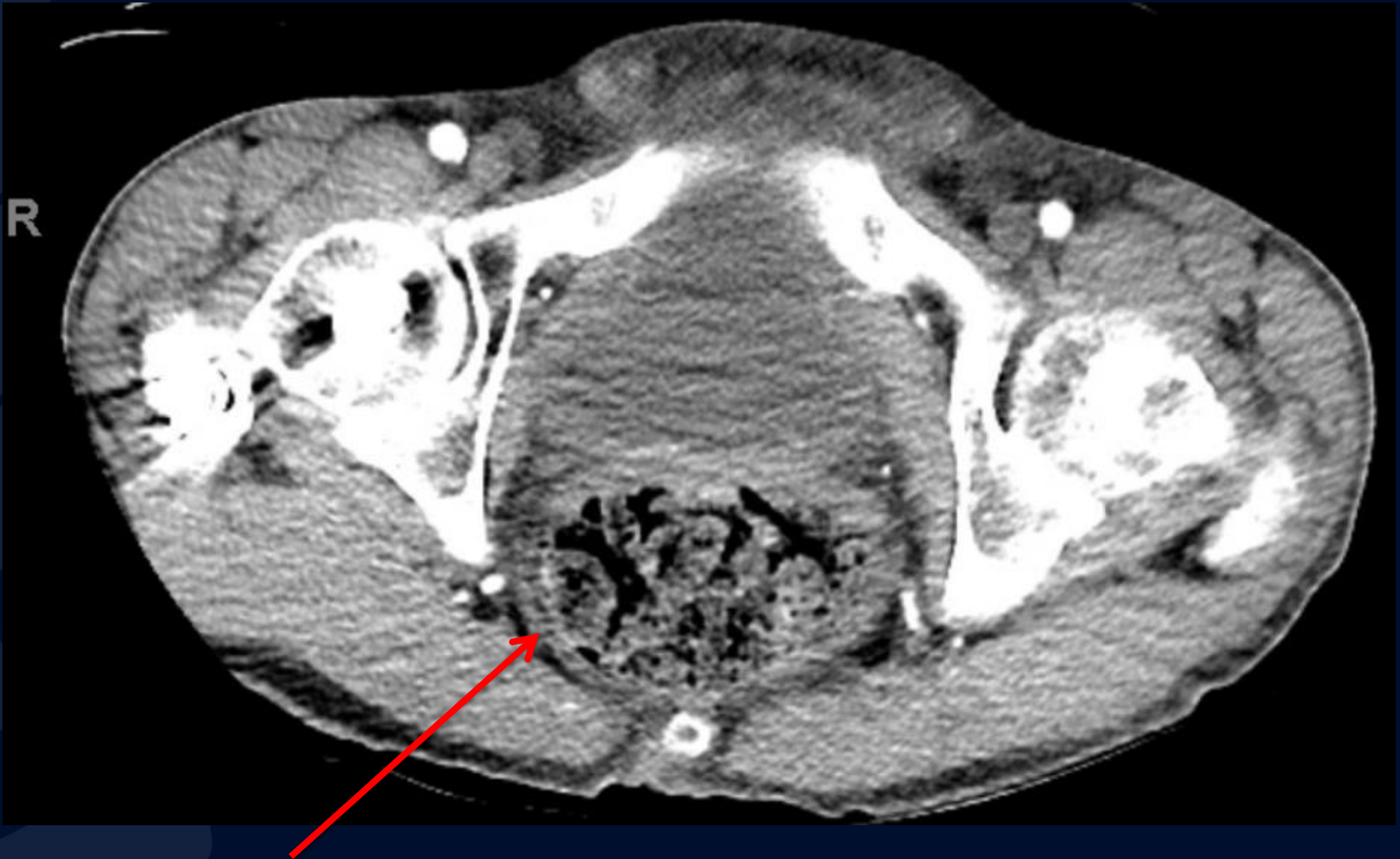
CT IV Contrast



Stool-filled
descending
colon

Rectosigmoid wall
enhancement

CT IV Contrast



Transmural rectal
wall thickening

Stercoral Colitis

- A rare, inflammatory form of colitis when impacted fecal material leads to colonic distention and fecaloma formation
- Colonic distention and \uparrow Intraluminal pressure can compromise vascular supply and lead to ischemic colitis
- Most often occurs in patient's with chronic constipation
 - Most at risk: elderly, psychiatric patients, dementia, chronic opioid use
- Diagnosis is often delayed because of comorbidities that interfere with prompt reporting of symptoms
- Management
 - Requires emergent management
 - Manual dis-impaction +/- endoscopically guided dis-impaction

Radiographic Features

Imaging is key to diagnosis

- Upright abdominal radiograph – helpful in ruling out free air
- Contrast enhanced abdominal CT

Key imaging features

- Fecal impaction
- Diffuse bowel dilation extending to stomach and lower esophagus.
- Focal thickening of rectosigmoid wall

References

- Post TW, ed. Etiology and evaluation of chronic constipation in adults. In: UpToDate. UpToDate; 2023.
- Kumar A, Mehta D. Chilaiditi Syndrome. In: StatPearls. StatPearls Publishing; 2023. Accessed April 2, 2023. <http://www.ncbi.nlm.nih.gov/books/NBK554565/>
- George J, Hotham R, Melton W, Chapple K. Clozapine-induced stercoral colitis: a surgical perspective. *BMJ Case Rep.* 2019;12(8):e227718. doi:10.1136/bcr-2018-227718
- Morano C, Sharman T. Stercoral Colitis. In: StatPearls. StatPearls Publishing; 2023. Accessed April 2, 2023. <http://www.ncbi.nlm.nih.gov/books/NBK560608/>
- Panneerselvam S, Carlson JJ, Lin D. Stercoral Colitis: When Constipation is an Emergency. *Am J Med Sci.* 2021;361(6):e61-e62. doi:10.1016/j.amjms.2020.11.013
- Shirazi A, Stubbs B, Gomez L, et al. Prevalence and Predictors of Clozapine-Associated Constipation: A Systematic Review and Meta-Analysis. *Int J Mol Sci.* 2016;17(6):863. doi:10.3390/ijms17060863
- Patel RS, Veluri N, Suchorab A, Shah K, Verma G. Clozapine-Induced Constipation: A Case Report and Review of Current Management Guidelines. *Cureus.* 13(5):e14846. doi:10.7759/cureus.14846
- Research C for DE and. FDA strengthens warning that untreated constipation caused by schizophrenia medicine clozapine (Clozaril) can lead to serious bowel problems. FDA. Published online January 14, 2022. Accessed April 2, 2023. <https://www.fda.gov/drugs/fda-drug-safety-podcasts/fda-strengthens-warning-untreated-constipation-caused-schizophrenia-medicine-clozapine-clozaril-can>