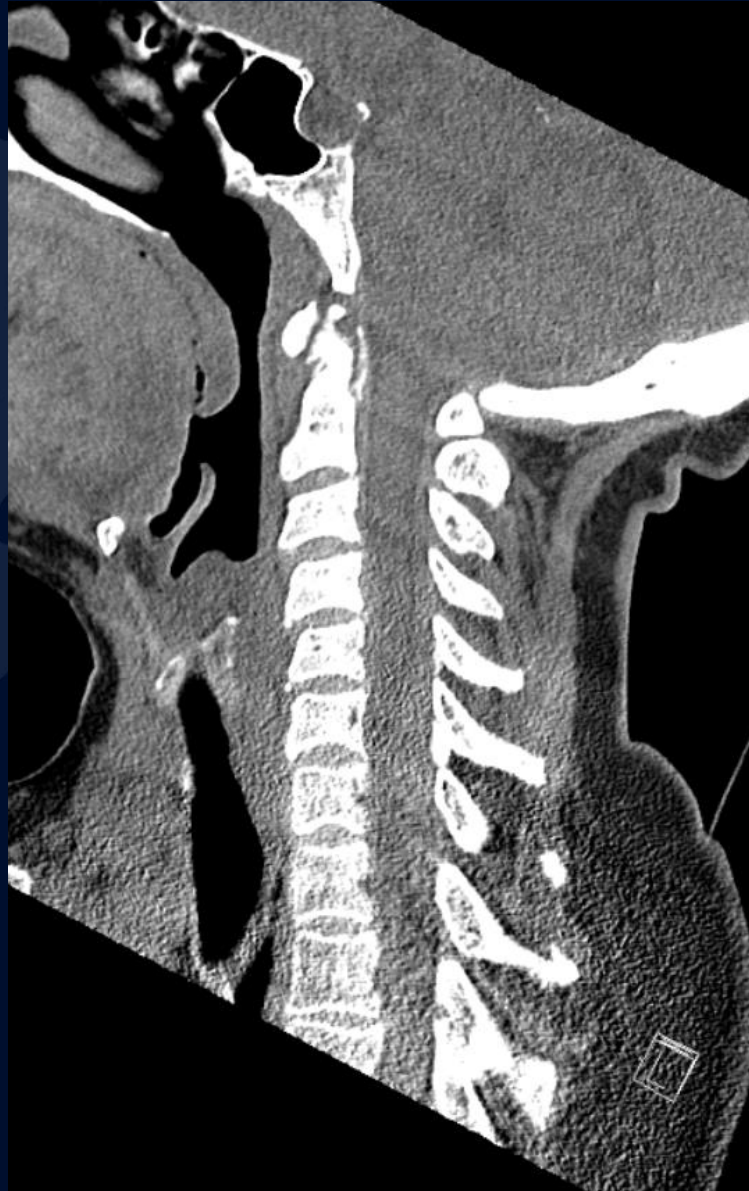

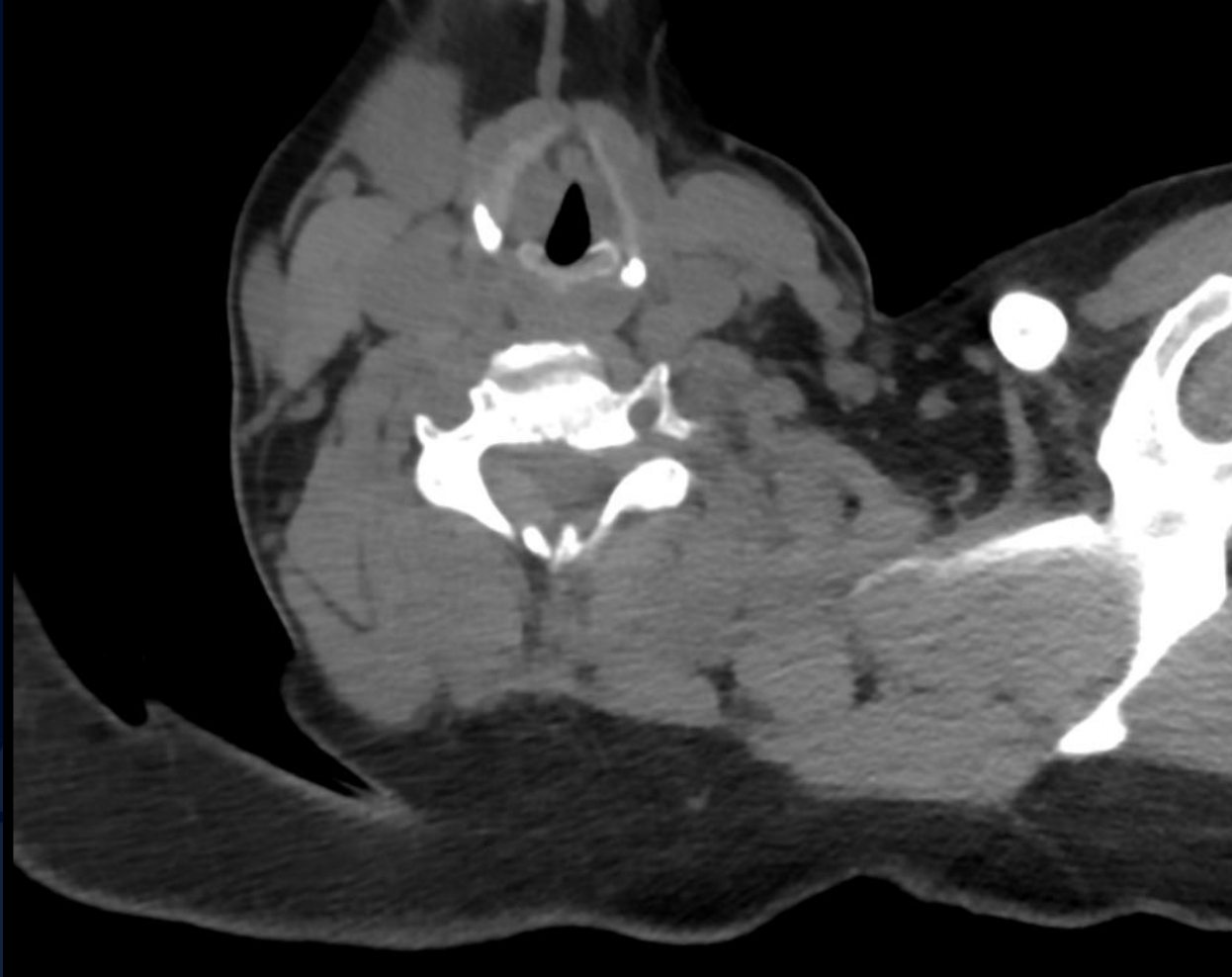
63-year-old female with
acute-on-chronic neck pain,
unilateral right arm paresthesias,
and bilateral leg weakness

Evan Risch, MS3

Non-contrast CT



Non-contrast CT

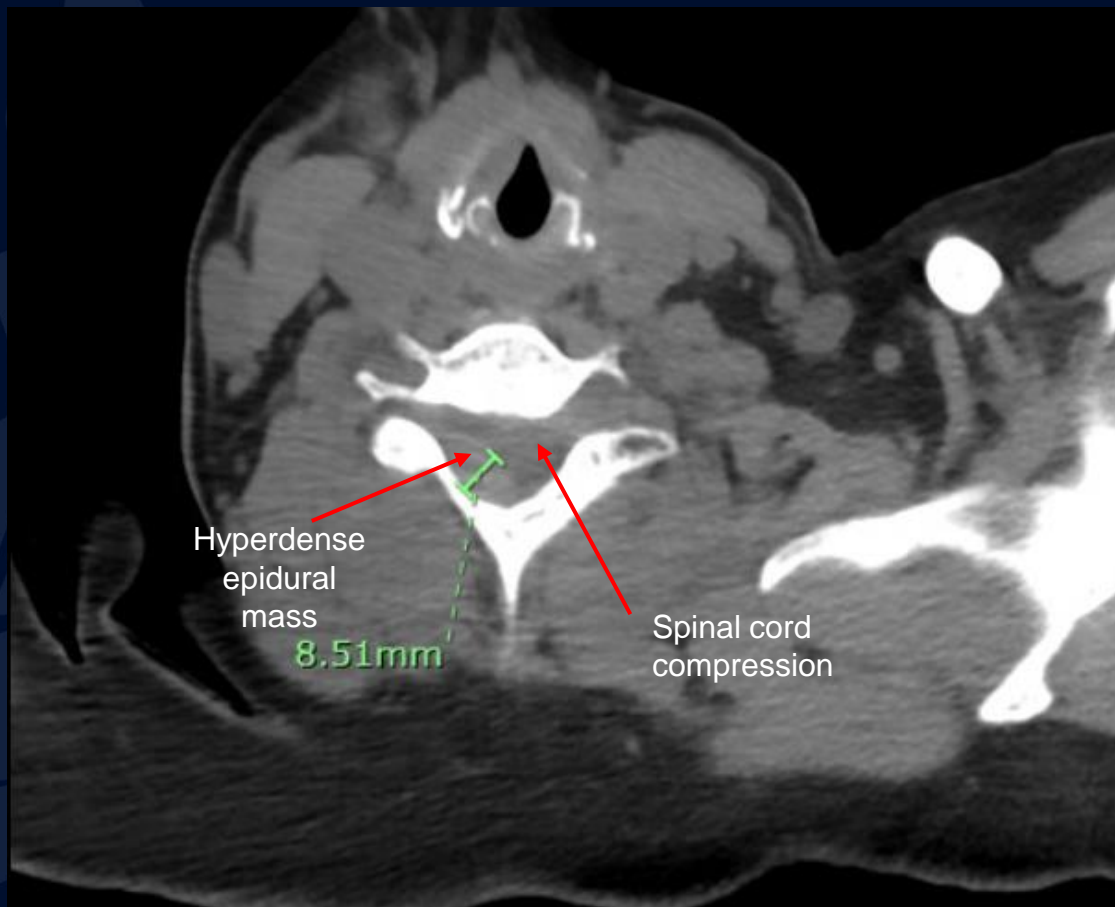




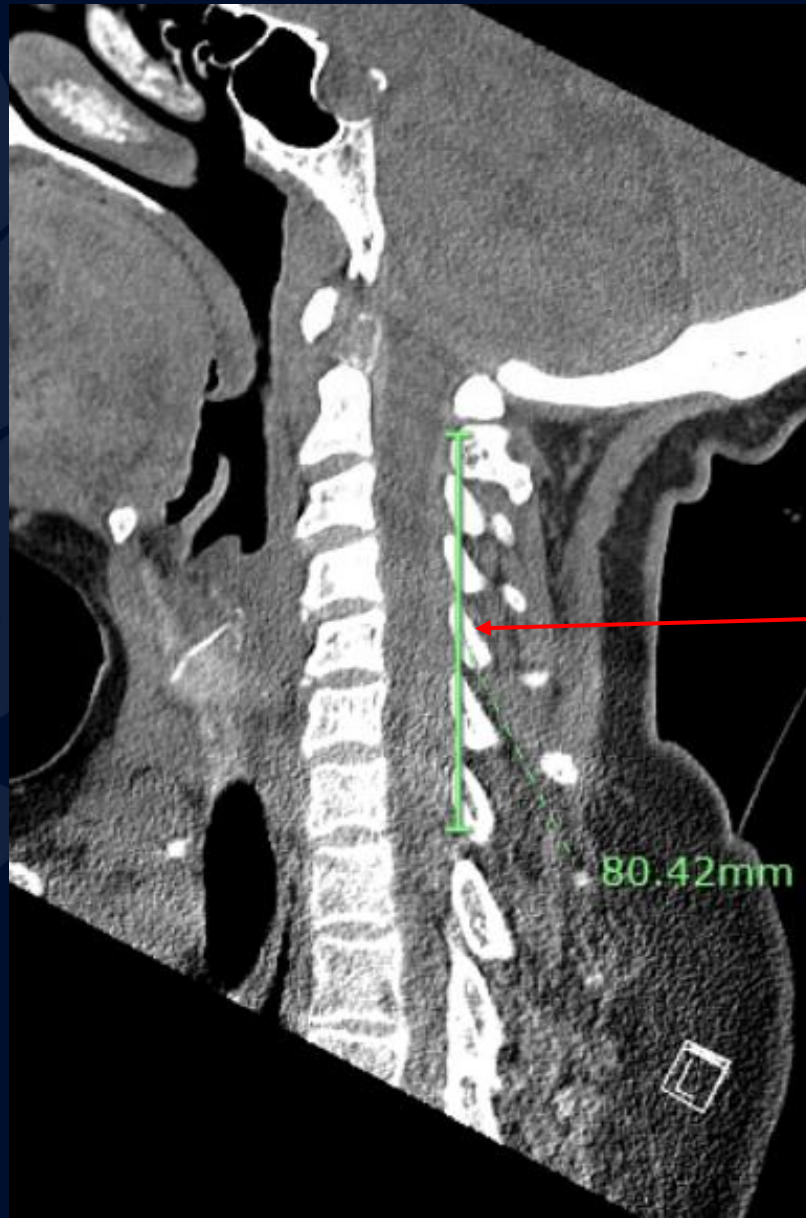
?

Spontaneous Spinal Epidural Hematoma

Non-contrast CT



Non-contrast CT



Hyperdense
epidural mass

Spontaneous Spinal Epidural Hematoma

Rare neurological emergency in which there is accumulation of hemorrhage between the dura and spine which is not caused by significant trauma or iatrogenic procedures; unclear etiology

Clinical Presentation

- Acute onset neck and back pain, progressive paraparesis, bladder and bowel dysfunction

Differential diagnosis

- Stroke or TIA
- Multiple sclerosis
- Cervical spondylopathy leading to radiculopathy
- Vertebral fracture

Imaging findings

- Increased attenuation within the epidural space
- +/- mass effect on the spinal cord
- Diagnosis requires absence of identifiable triggers, traumatic events or other direct causes

Treatment

- Surgical decompression and hematoma evacuation
- Conservative management for less severe cases

Imaging Findings

MRI

- Provides the most info regarding extent of hematoma and degree of cord compression
- Extradural multisegmented fluid collection

CT

- If MRI is unavailable or cannot be done quickly
- Hyperdense epidural mass; soft tissue window is essential
- Variable cord compression
- Sagittal reformation best evaluates for craniocaudal extent

Common sites

- C5-T1
- T10-L2

Sources of bleed

- Arterial (rapid)- meningeal branches of the ascending and deep cervical arteries
- Venous (slower)- vertebral venous plexus
 - More insidious onset of symptoms

References

- Salehpour F, Mirzaei F, Kazemzadeh M, et al. Spontaneous Epidural Hematoma of Cervical Spine. *Int J Spine Surg*. 2018 Mar 30;12(1):26-29. doi: 10.14444/5005. PMID: 30280079; PMCID: PMC6162037.
- Fukui MB, Swarnkar AS, Williams RL. Acute spontaneous spinal epidural hematomas. *AJNR Am J Neuroradiol*. 1999;20:1365–1372.
- Beatty RM, Winston KR. Spontaneous cervical epidural hematoma. A consideration of etiology. *J Neurosurg*. 1984 Jul;61(1):143-8. doi: 10.3171/jns.1984.61.1.0143. PMID: 6726389.
- Gopalkrishnan CV, Dhakoji A, Nair S. Spontaneous cervical epidural hematoma of idiopathic etiology: case report and review of literature. *J Spinal Cord Med*. 2012 Mar;35(2):113–7.
- Holtås S, Heiling M, Lönntoft M. Spontaneous spinal epidural hematoma: findings at MR imaging and clinical correlation. *Radiology*. 1996 May;199(2):409-13. doi: 10.1148/radiology.199.2.8668786. PMID: 8668786.
- Yan M, Peng D, Liu T, et al. Prognostic Factors and Treatments Efficacy in Spontaneous Spinal Epidural Hematoma: A Multicenter Retrospective Study. *Neurology*. 2022 Jun 17;10.1212/WNL.0000000000200844. doi: 10.1212/WNL.0000000000200844. Epub ahead of print. PMID: 35715197.
- Scheil F, Larkamp U, Mutharoglu U. Das spontane spinale epidurale Hämatom [Spontaneous spinal epidural hematoma]. *Neurochirurgia (Stuttg)*. 1990 Oct;33 Suppl 1:45-9. German. doi: 10.1055/s-2008-1053597. PMID: 2293048.
- Liu Z, Jiao Q, Xu J, et al. Spontaneous spinal epidural hematoma: analysis of 23 cases. *Surg Neurol*. 2008;69:253–260. discussion 260.
- Groen RJ. Non-operative treatment of spontaneous spinal epidural hematomas: a review of the literature and a comparison with operative cases. *Acta Neurochir (Wien)*. 2004 Feb;146(2):103-10. doi: 10.1007/s00701-003-0160-9. Epub 2003 Dec 5. PMID: 14963742.
- Williams O, Levin J, Stern M. Nontraumatic Disorders of the Spinal Cord. In: Brust JM. editors. *CURRENT Diagnosis & Treatment: Neurology*. 3rd ed. McGraw Hill; 2019. C2022 [cited 2022 Aug 02]. Available from: <https://accessmedicine-mhmedical-com.online.uchc.edu/content.aspx?bookid=2567§ionid=207232847>

References, cont.

- Zuo B, Zhang Y, Zhang J, et al. Spontaneous Spinal Epidural Hematoma: A Case Report. *Case Rep Orthop Res* 2018;;:27-34. doi: 10.1159/000490067
- Solheim O, Jorgensen JV, Nygaard OP. Lumbar epidural hematoma after chiropractic manipulation for lower-back pain: case report. *Neurosurgery*. 2007 Jul;61(1):E170-1; discussion E171. doi: 10.1227/01.neu.0000279740.61048.e2. PMID: 17621008.
- Maurizio D, Daniele M, Alessandro P, et al. Acute spinal epidural hematoma after acupuncture: personal case and literature review. *World Neurosurg*. 2017;102:695.e11–695.e14. doi: 10.1016/j.wneu.2017.03.125.
- Gaffney P, Guthrie JA. Spontaneous spinal epidural haematoma: an unusual cause of neck pain. *J Accid Emerg Med*. 2000 May;17(3):229-30. doi: 10.1136/emj.17.3.229. PMID: 10819396; PMCID: PMC1725371.
- Deger SM, Emmez H, Bahadirli K, et al. A spontaneous spinal epidural hematoma in a hemodialysis patient: a rare entity. *Intern Med* 2009;48:2115-2118.
- Groen RJ, van Alphen HA. Operative treatment of spontaneous spinal epidural hematomas: a study of the factors determining postoperative outcome. *Neurosurgery*. 1996 Sep;39(3):494-508; discussion 508-9. doi: 10.1097/00006123-199609000-00012. PMID: 8875479.
- Raasck K, Habis AA, Aoude A, et al. Spontaneous spinal epidural hematoma management: a case series and literature review. *Spinal Cord Ser Cases*. 2017 Feb 2;3:16043. doi: 10.1038/scsandc.2016.43. PMID: 28382214; PMCID: PMC5289268.
- Shin JJ, Kuh SU, Cho YE. Surgical management of spontaneous spinal epidural hematoma. *Eur Spine J*. 2006 Jun;15(6):998-1004. doi: 10.1007/s00586-005-0965-8. Epub 2006 Apr 25. PMID: 16758110; PMCID: PMC3489451.
- Bakker NA, Veeger NJ, Vergeer RA, et al. Prognosis after spinal cord and cauda compression in spontaneous spinal epidural hematomas. *Neurology*. 2015 May