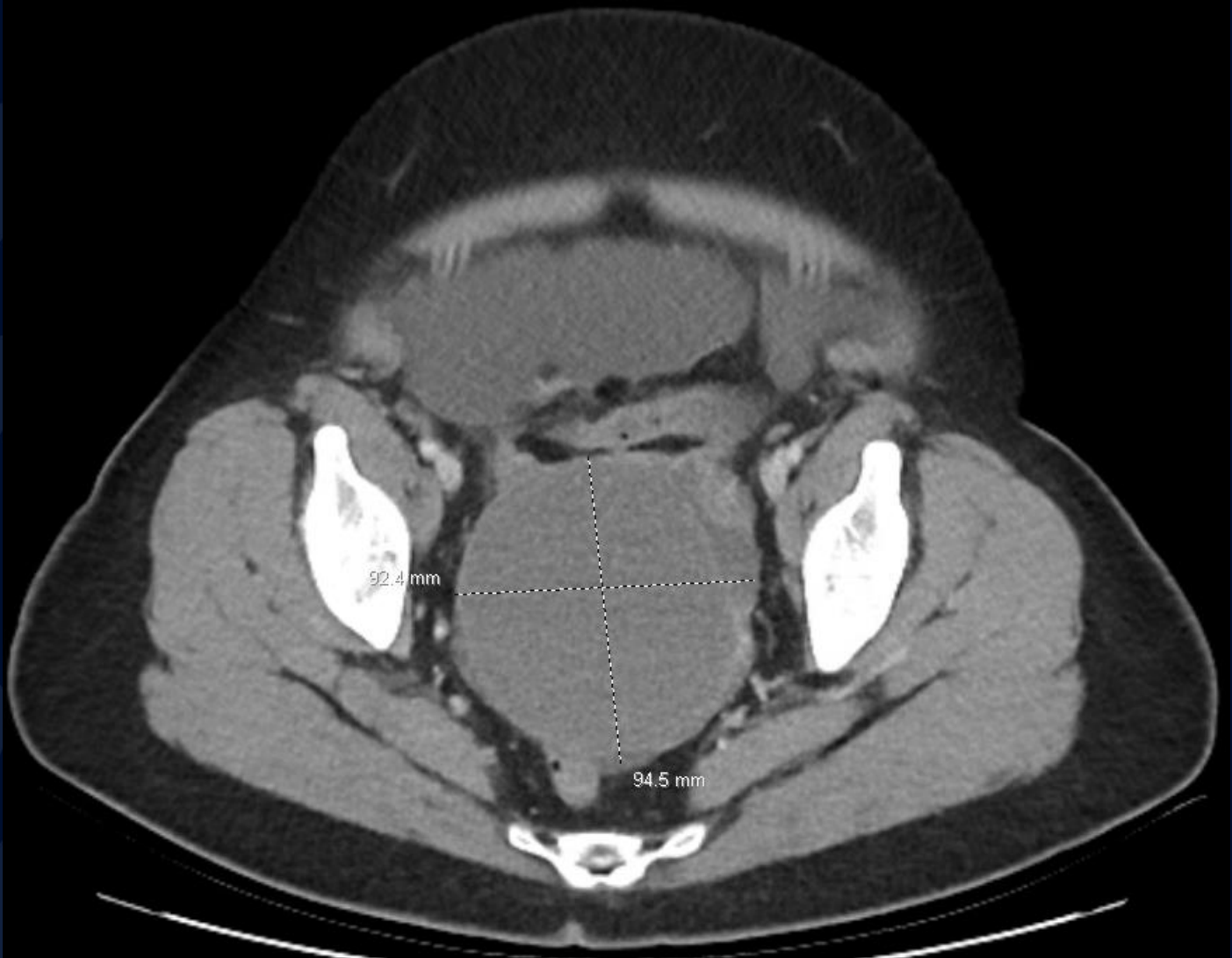


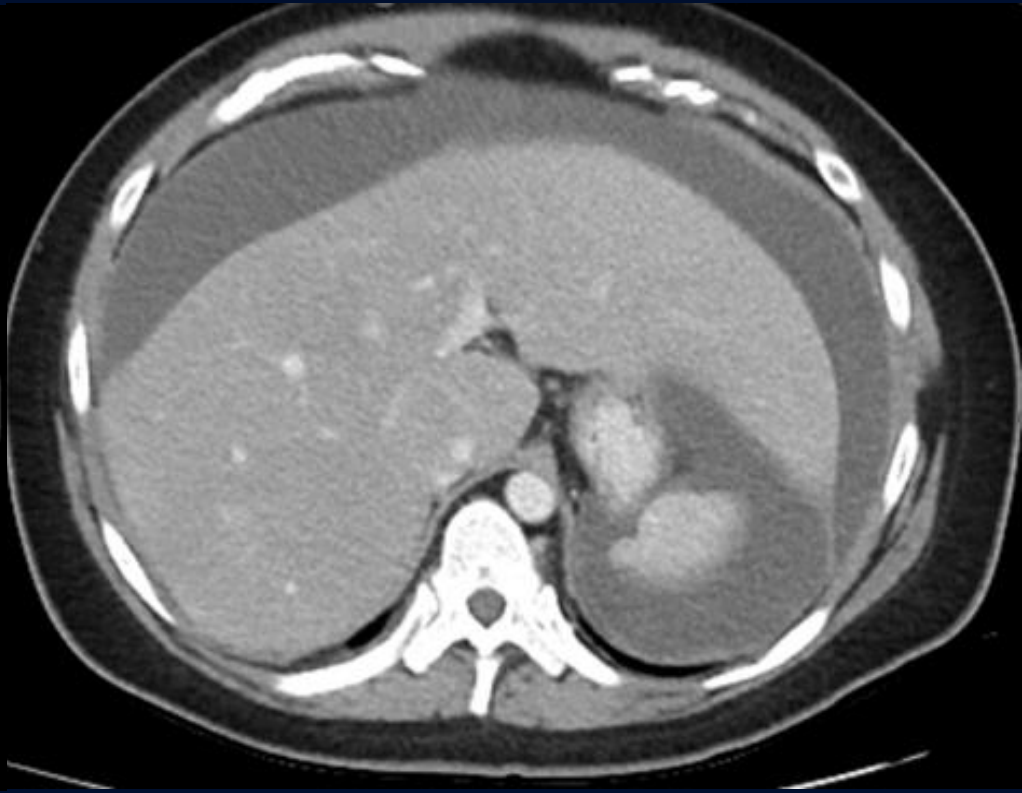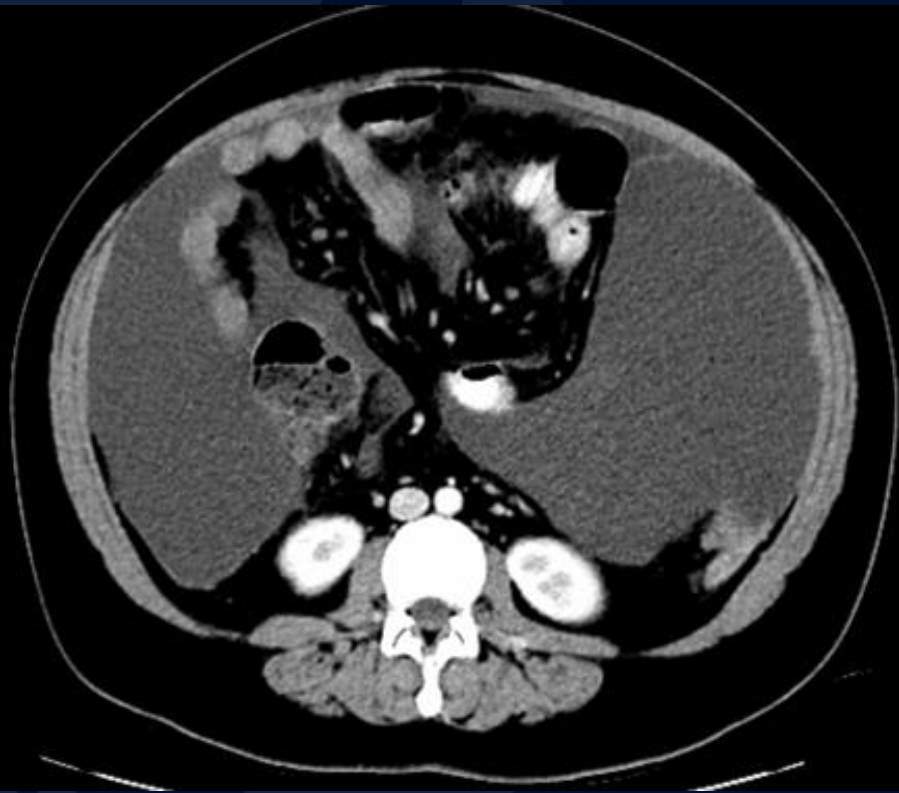
28-year-old female with fatigue, weight gain and abdominal pain

Kyle Murphy, MS3

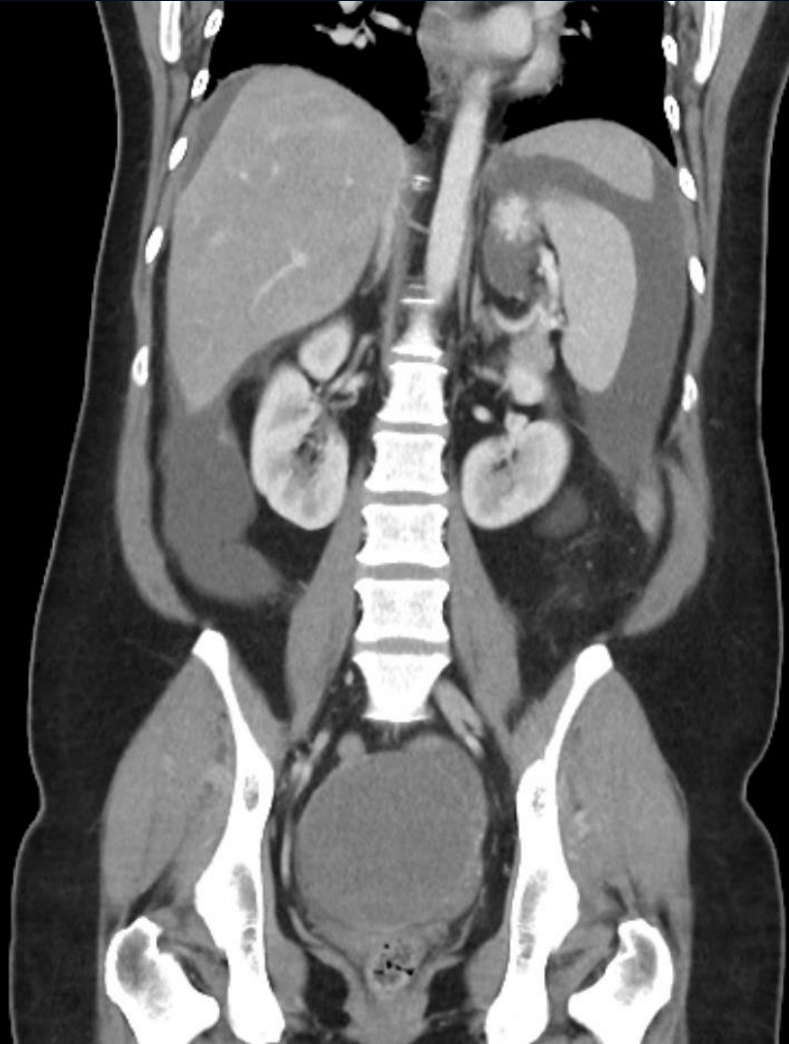
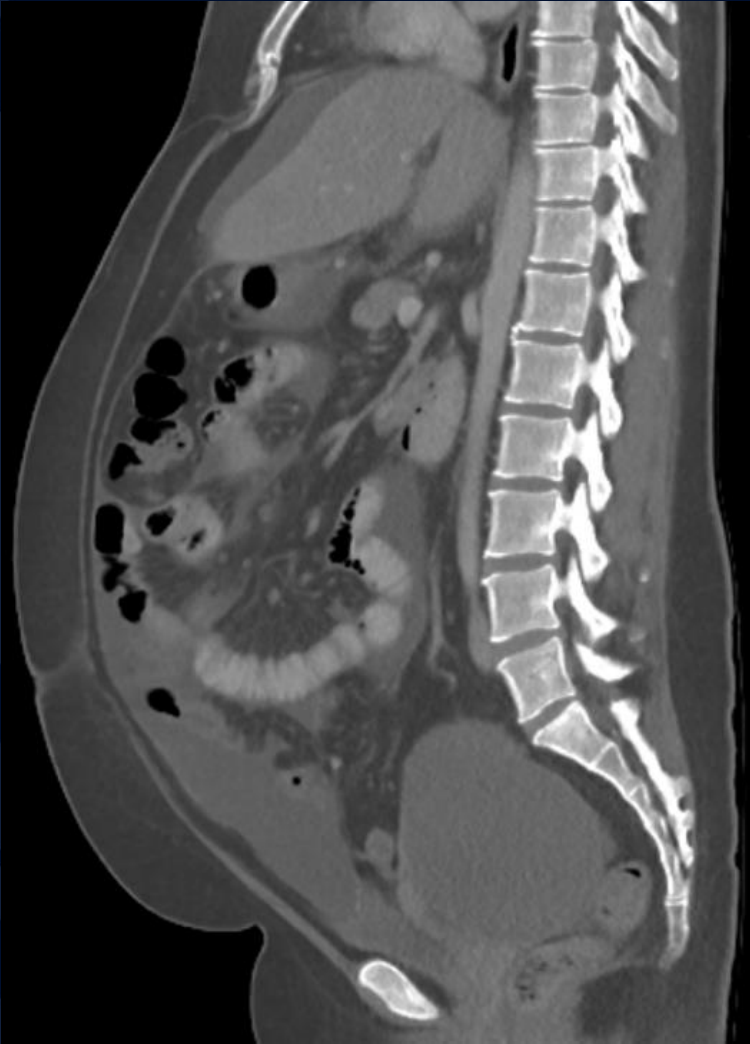
CT IV Contrast



CT IV Contrast



CT IV Contrast

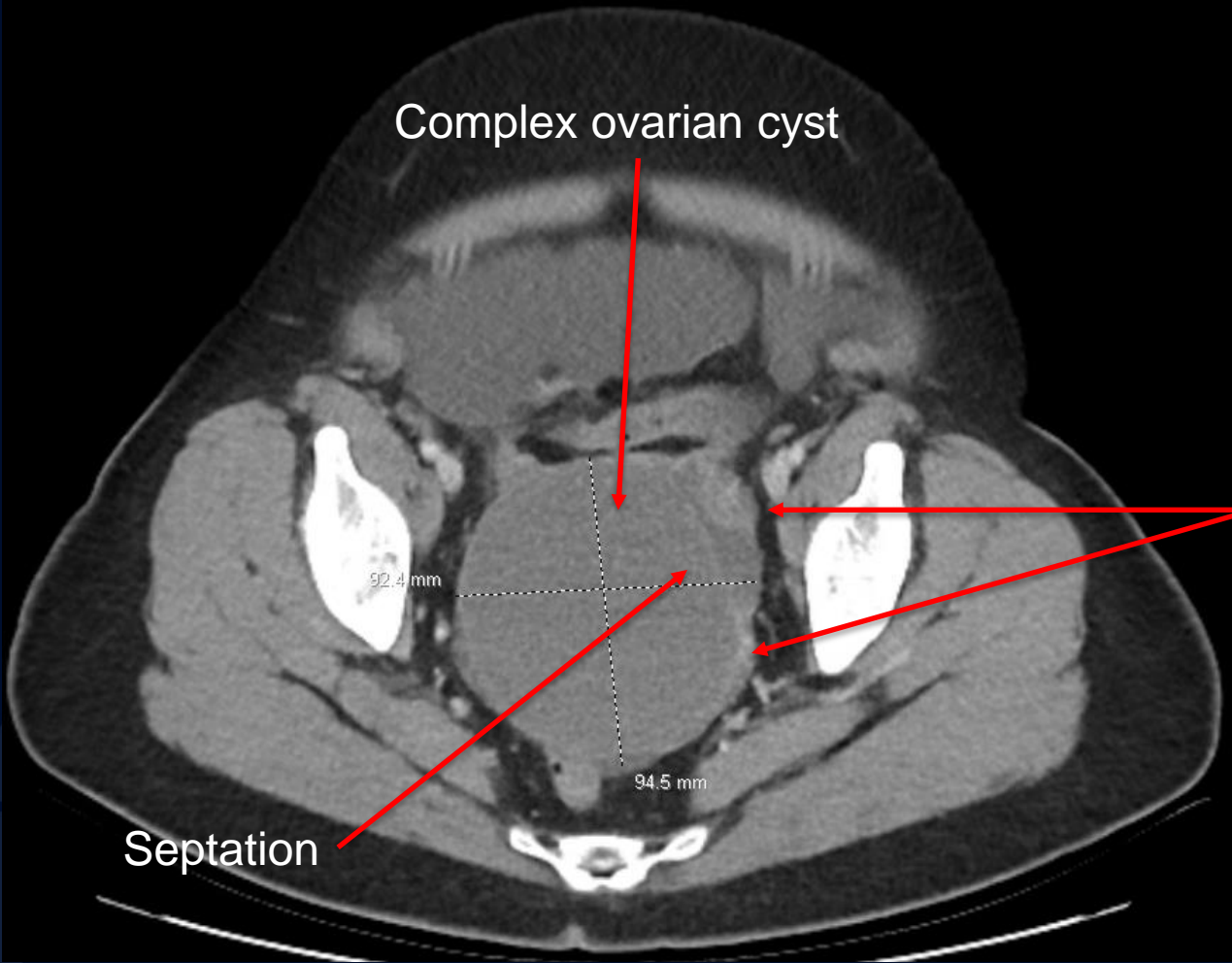


A large, stylized oak leaf graphic in a dark blue color, positioned on the left side of the slide. It features detailed vein patterns and a lobed edge.

?

Low-grade Serous Carcinoma (LGSC)

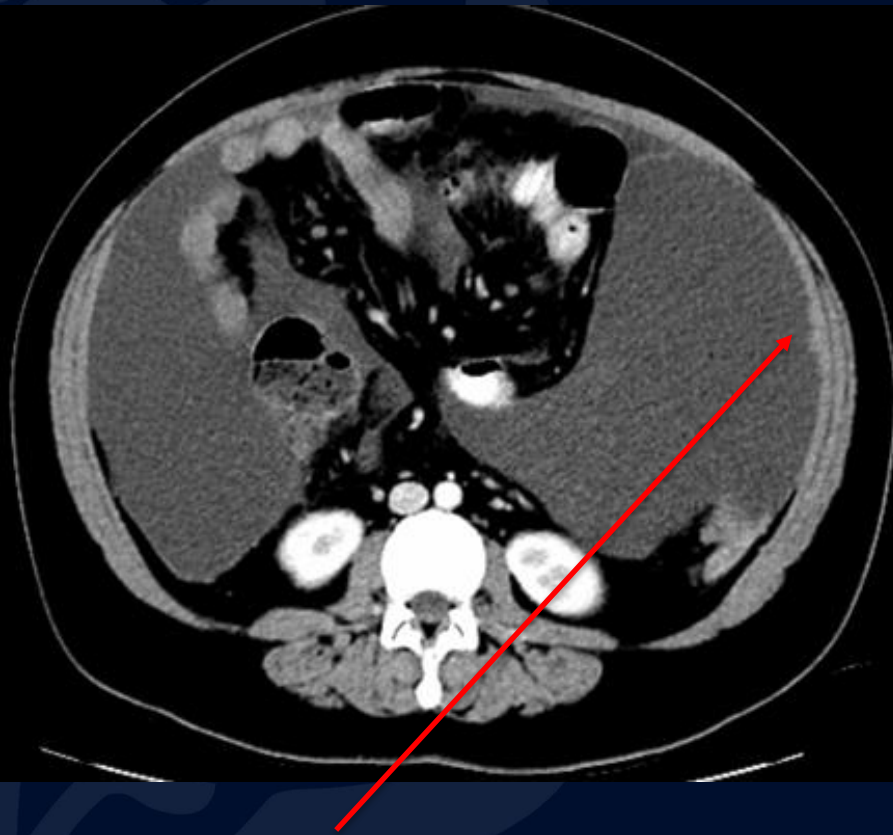
CT IV Contrast



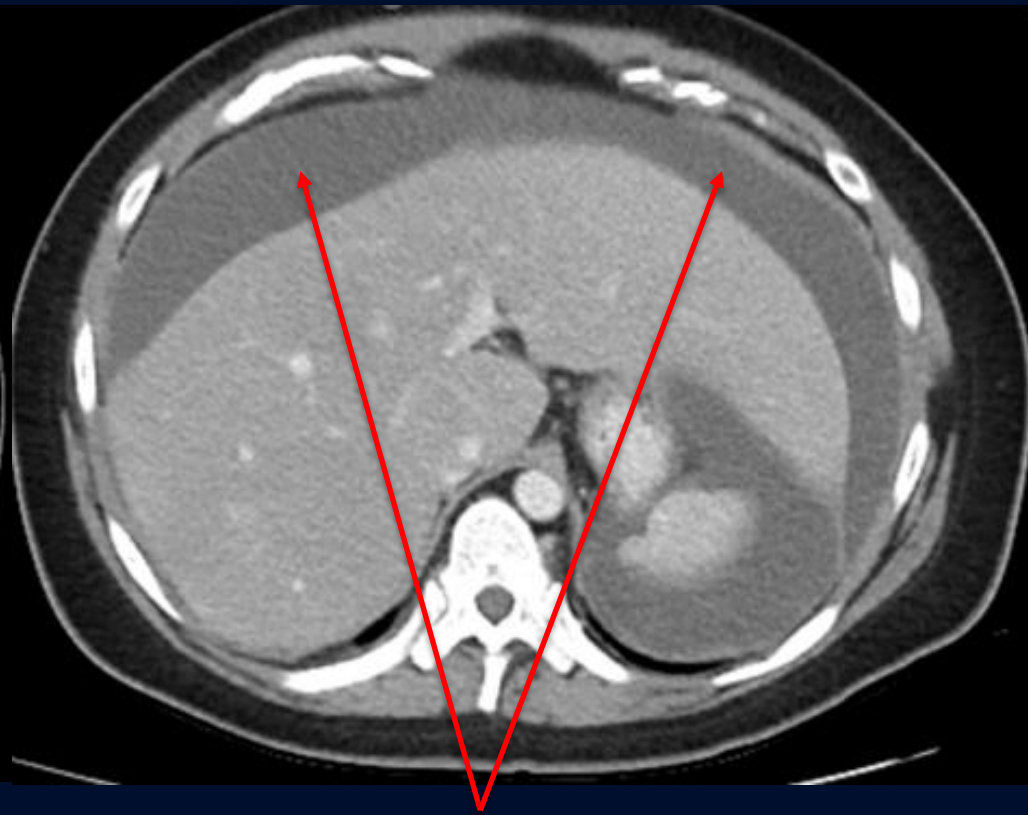Peripheral solid component

Septation

CT IV Contrast

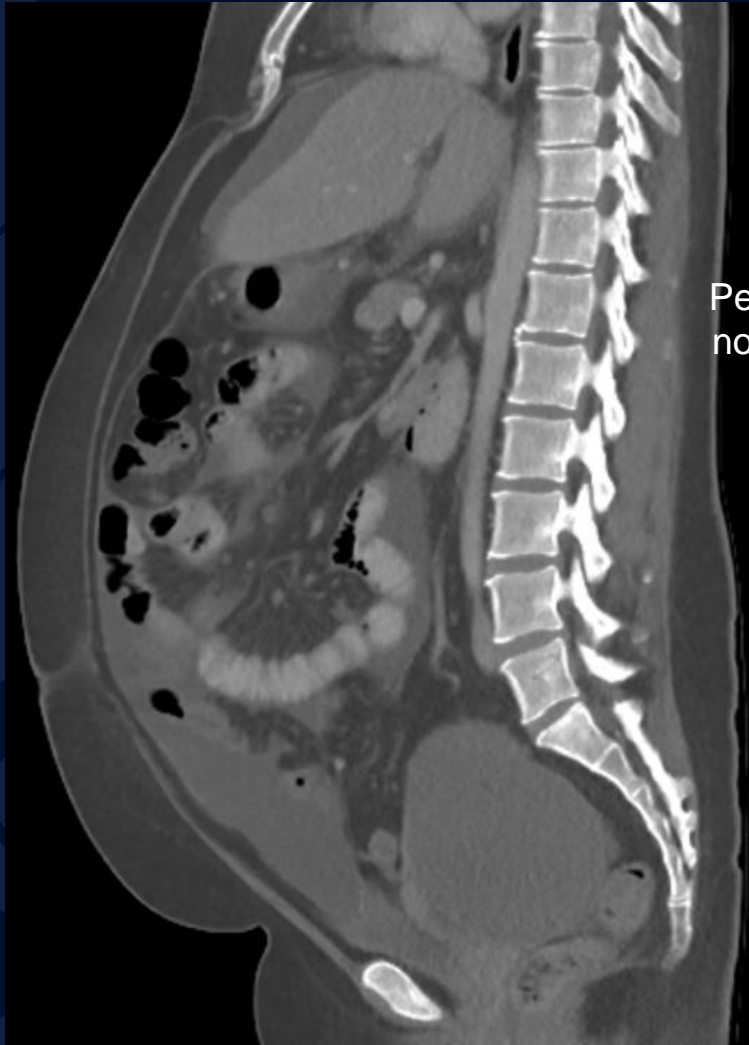

Peritoneal nodularity

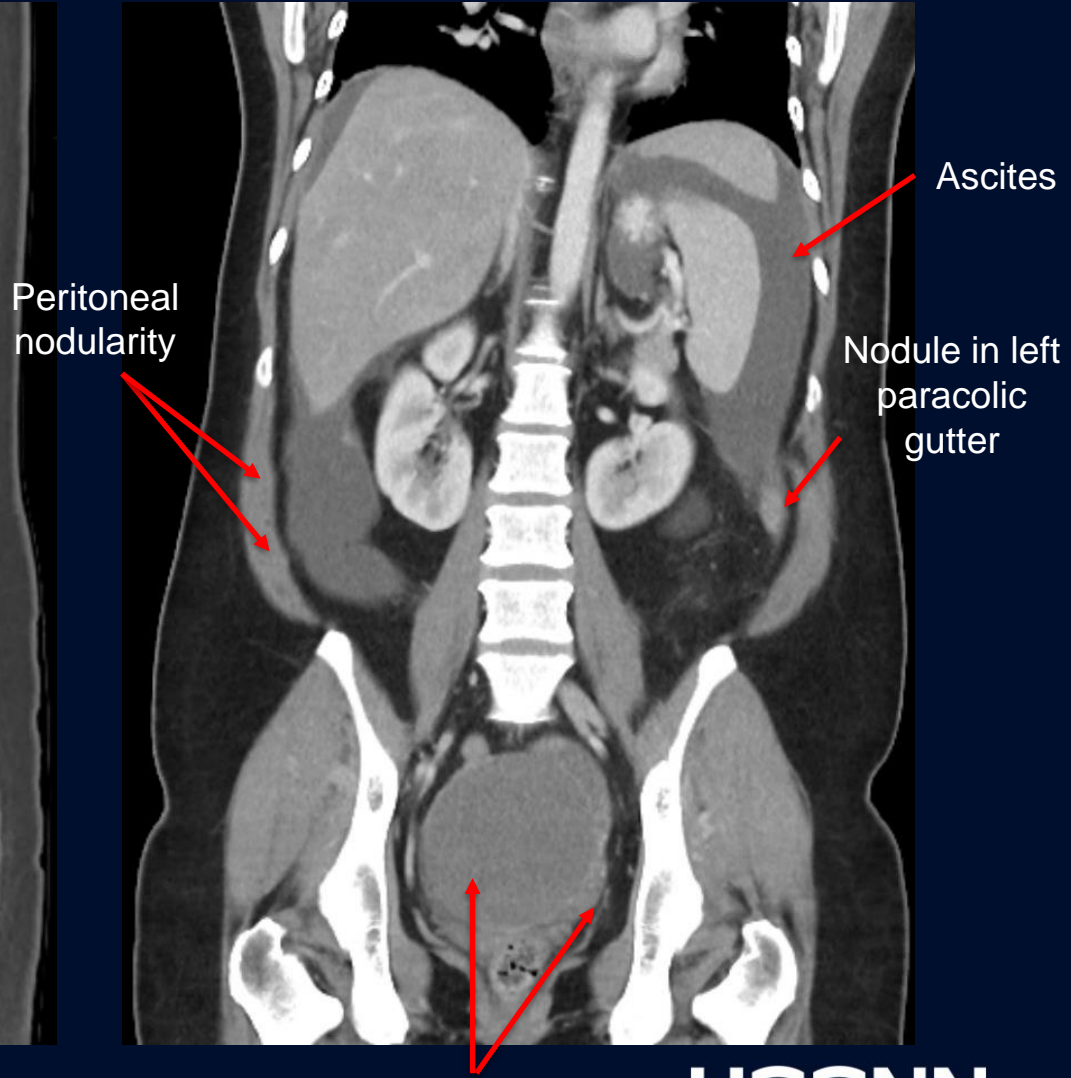


Ascites

CT Sagittal Pre-contrast



CT Coronal Post-contrast



Peritoneal nodularity

Ascites

Nodule in left paracolic gutter

Predominantly cystic ovarian mass with peripheral solid component

Low-grade Serous Carcinoma

Malignant ovarian epithelial tumor which shows destructive invasion, mild to moderate cytologic atypia, and relatively low proliferative activity

- Predominantly cystic with septations and papillary solid components.
- Bilateral in majority of cases
- LGSC accounts for 2% of all epithelial ovarian cancers and 4.7% of serous ovarian carcinoma
- Most commonly affects women at a younger age than high grade serous carcinoma; median age of diagnosis 43-47
- Rarely associated with BRCA mutations or strong family history of breast / ovarian cancer

Treatment

- Complete staging laparotomy and tumor debulking (cytoreduction)
 - Includes hysterectomy with bilateral salpingo-oophorectomy, pelvic and paraaortic node biopsies, omentectomy, peritoneal biopsies and washings
 - More conservative surgery may be done alternatively in women of reproductive age with stage I disease
- Chemotherapy after cytoreductive surgery
- Neoadjuvant chemotherapy before cytoreduction surgery in patients with unresectable disease
 - Includes bulky disease in difficult-to-reach areas (porta hepatitis, lesser sac, roof of mesentery), extensive surrounding organ or sidewall invasion, or stage IV disease

Imaging Findings

In general, one cannot definitively distinguish serous from mucinous neoplasms based solely on imaging features.

- Typically smaller than mucinous tumors on presentation
- Often unilocular and homogenous
- Often bilateral
- Commonly have microcalcifications (psammoma bodies) seen on histology vs mucinous which may have intramural calcifications

Features that suggest a malignant versus benign cystic neoplasm include:

- Large size
- Thick irregular walls and septa
- Papillary projections
- Large soft tissue component
- Ascites
- Evidence of invasive spread or adenopathy

References

- Slomovitz, B., Gourley, C., Carey, M. S., Malpica, A., Shih, I. M., Huntsman, D., Fader, A. N., Grisham, R. N., Schlumbrecht, M., Sun, C. C., Ludemann, J., Cooney, G. A., Coleman, R., Sood, A. K., Mahdi, H., Wong, K. K., Covens, A., O'Malley, D. M., Lecuru, F., Cobb, L. P., Gershenson, D. M. (2020). Low-grade serous ovarian cancer: State of the science. *Gynecologic oncology*, 156(3), 715–725.
- Hauptmann S, Friedrich K, Redline R, Avril S. Ovarian borderline tumors in the 2014 WHO classification: evolving concepts and diagnostic criteria. *Virchows Arch*. 2017 Feb;470(2):125-142.
- Saida, T., Tanaka, Y.O., Matsumoto, K. et al. Revised FIGO staging system for cancer of the ovary, fallopian tube, and peritoneum: important implications for radiologists. *Jpn J Radiol* 34, 117–124 (2016)
- <https://www.aafp.org/pubs/afp/issues/2009/1015/p815.html>
- <https://radiopaedia.org/articles/ovarian-serous-tumours?lang=us>