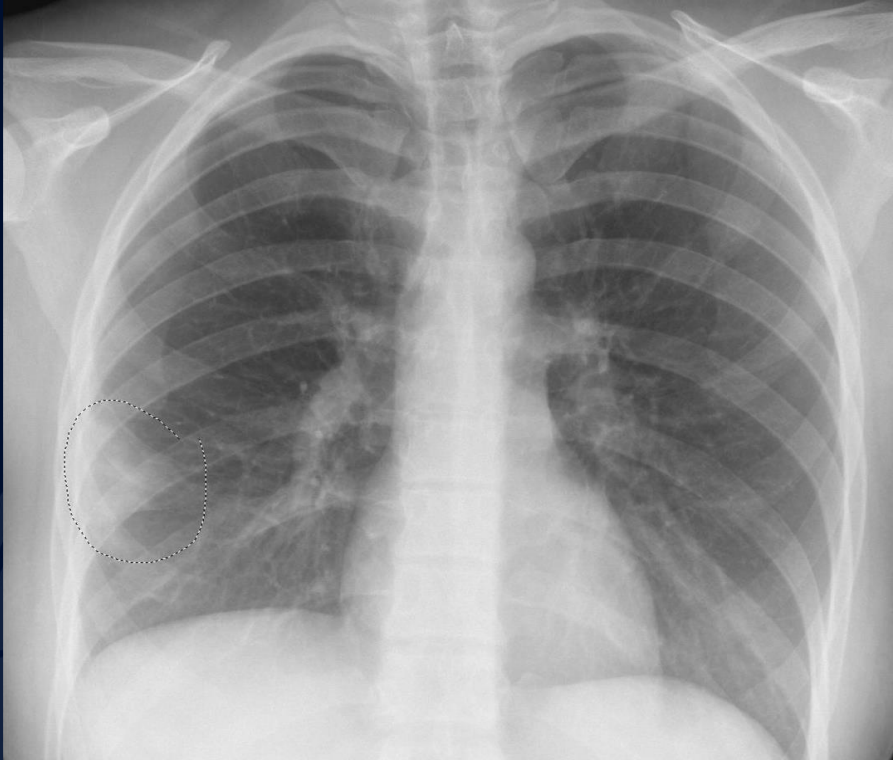

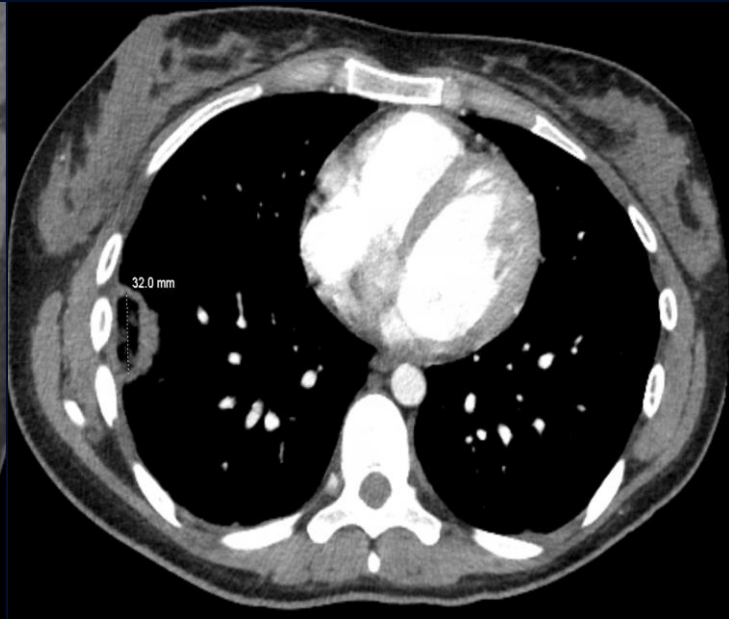
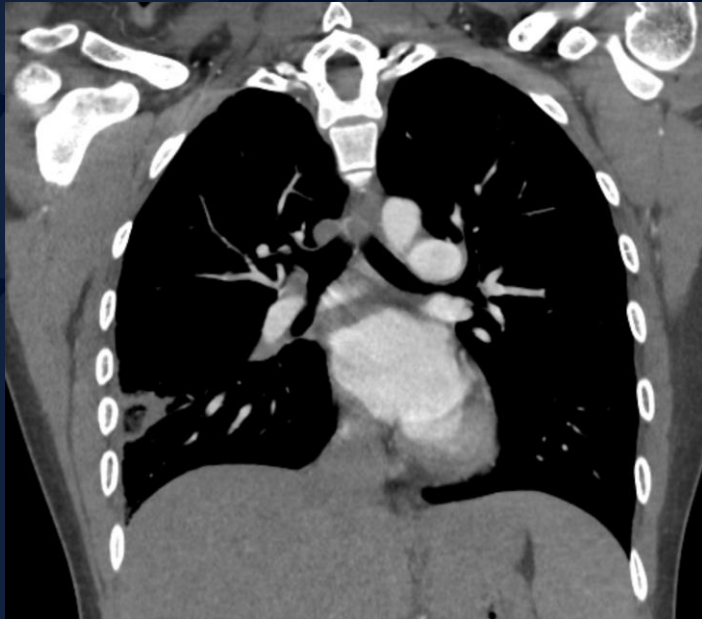
20-year-old female s/p mitral valve replacement presenting with 10-day history of fever, sore throat, and pleuritic chest pain

Nehal Navali, MS3

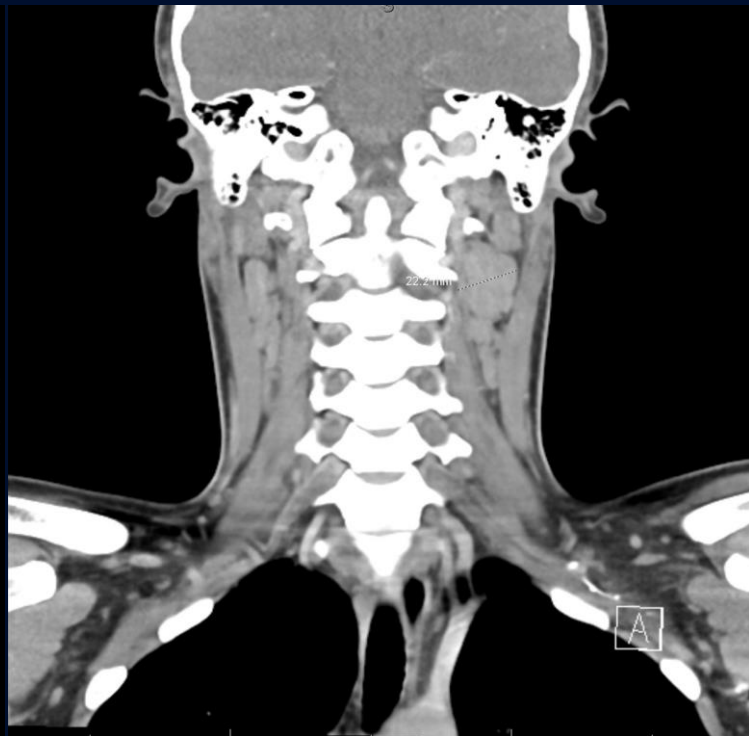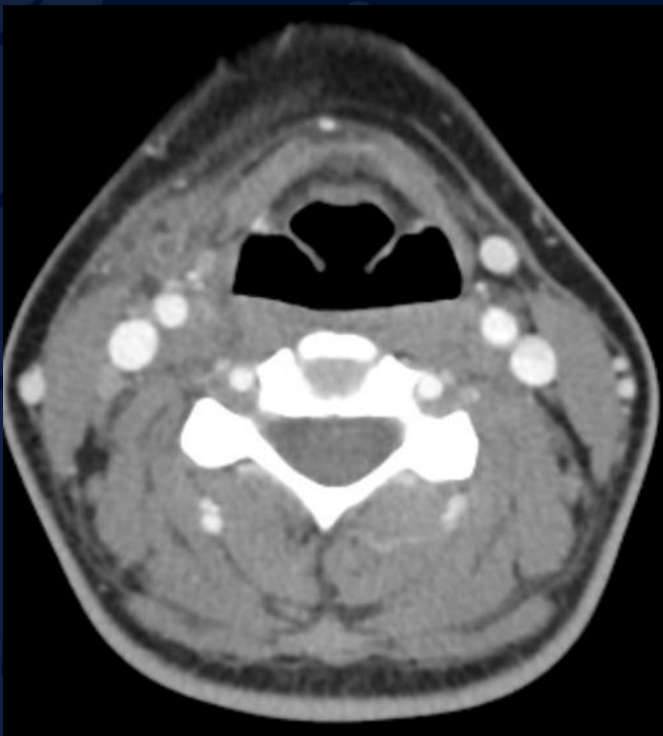
# Radiograph



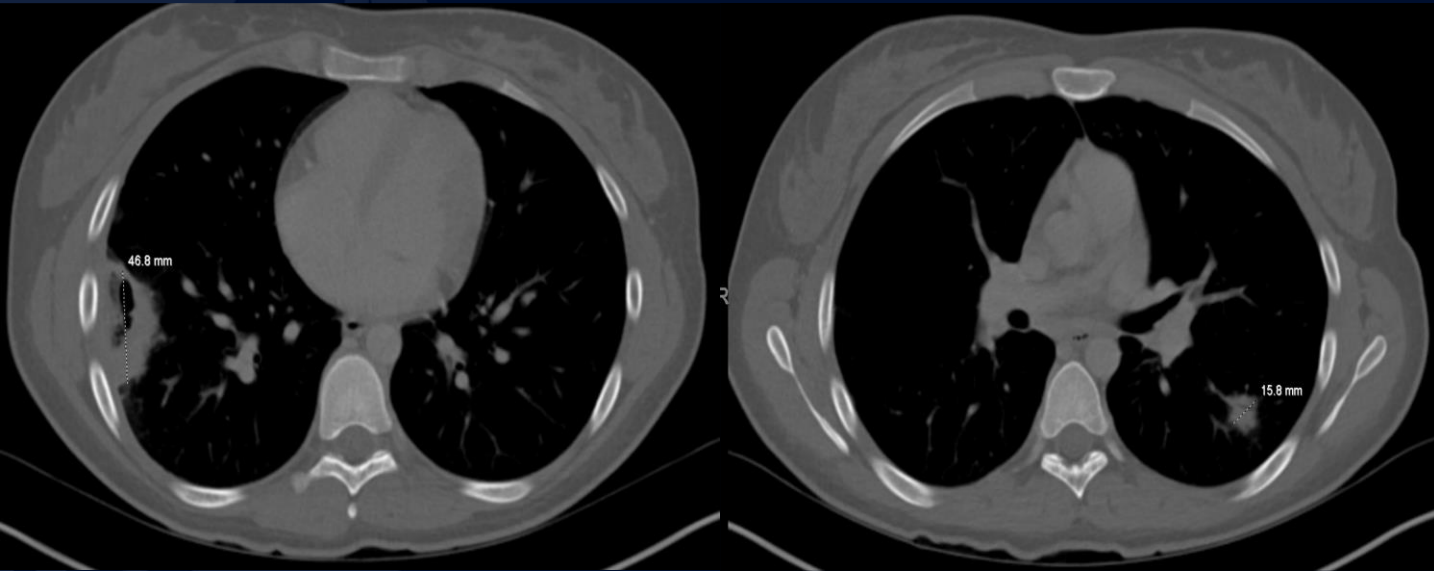
# CT IV Contrast



# CT IV Contrast



# Follow-up CT (3 days later)



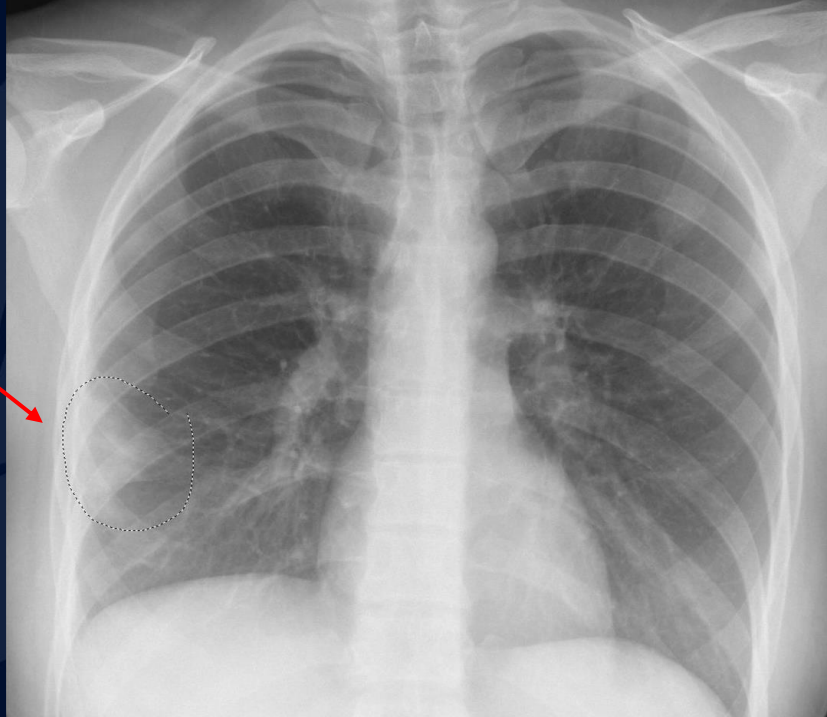A large, stylized oak leaf graphic in a dark blue color, positioned on the left side of the slide.

?

# Lemierre Syndrome

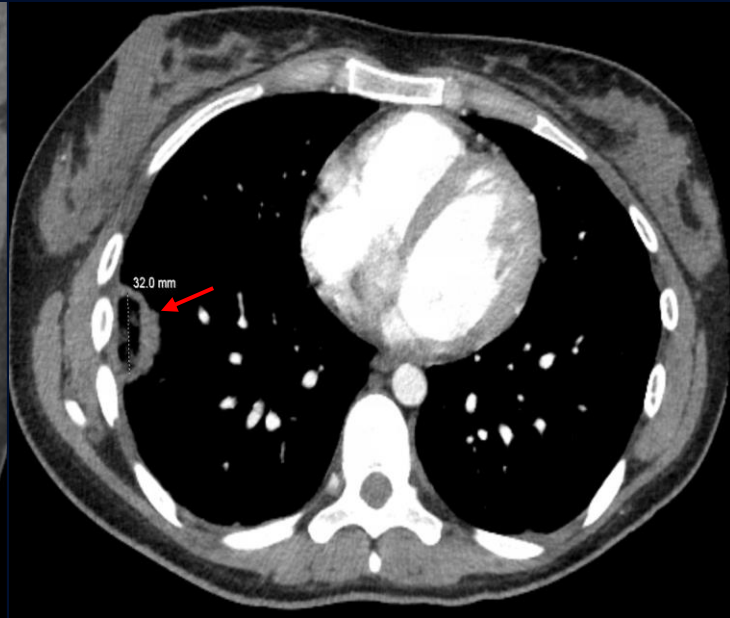
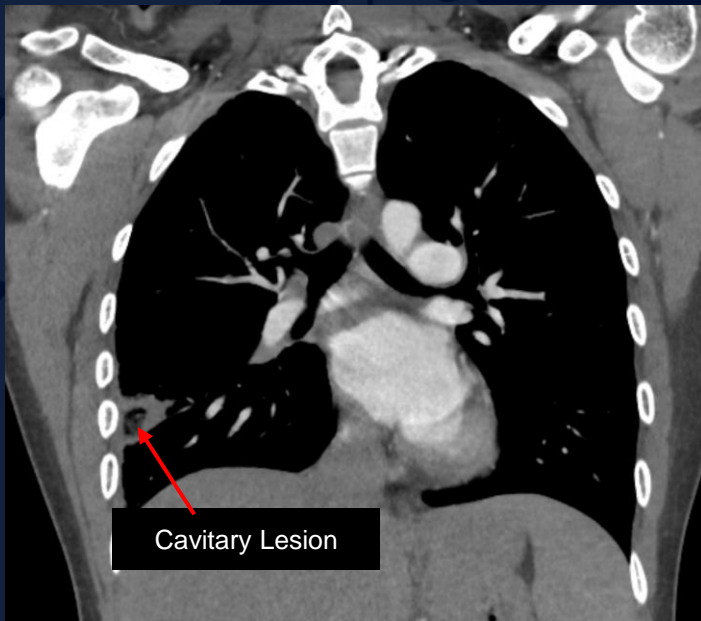
# Radiograph

Right lower lobe  
airspace opacity



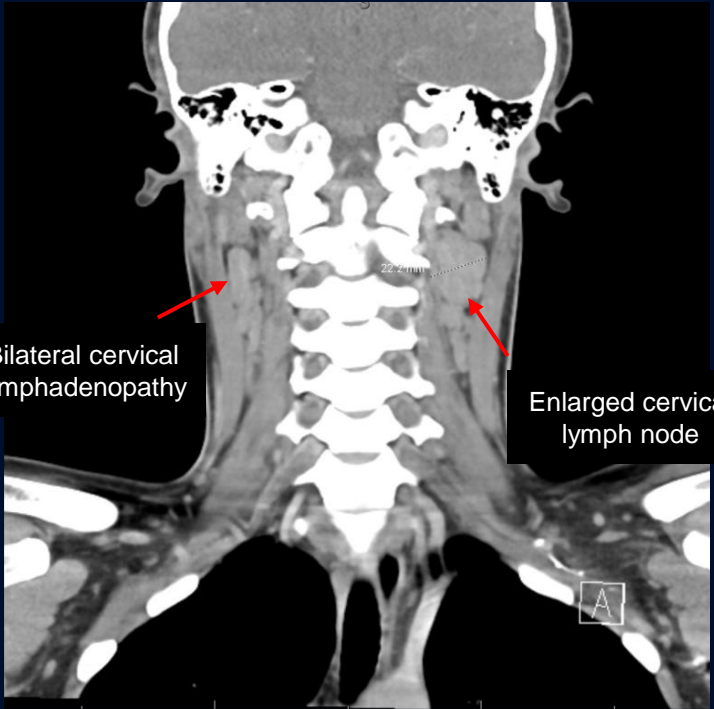
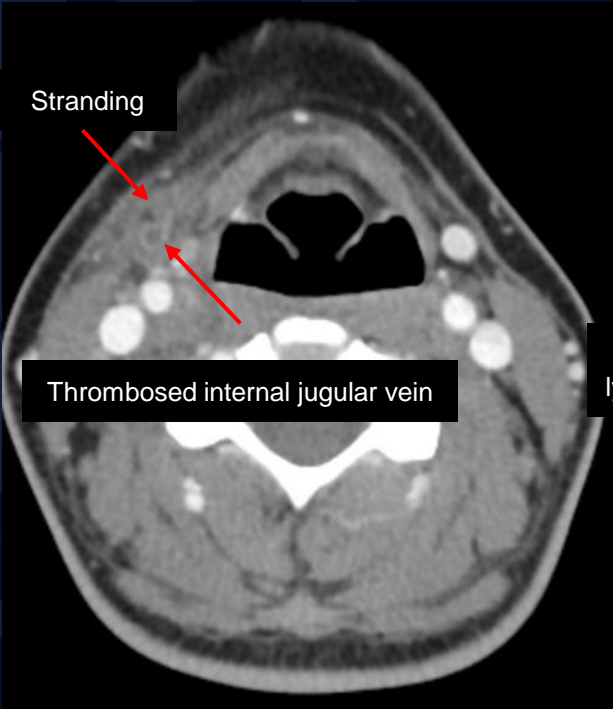


# CT IV Contrast

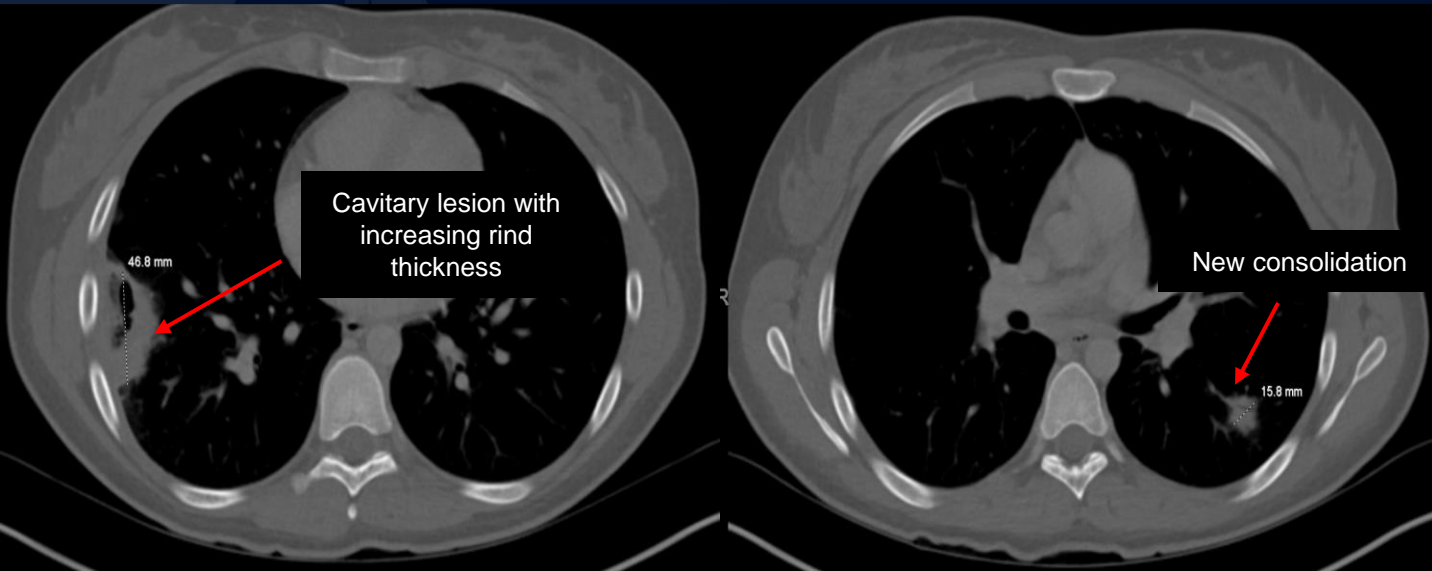

Septic emboli

# CT IV Contrast



# Follow-up CT (3 days later)



Septic emboli

# Lemierre Syndrome

Lemierre's Syndrome refers to thrombophlebitis of the internal jugular veins with distant metastatic anaerobic septicemia in the setting of initial bacterial oropharyngeal infection such as pharyngitis/tonsillitis into the lateral pharyngeal spaces of the neck. Most often caused by *Fusobacterium necrophorum*.

- Presentation

- Develops 4-5 days after an episode of acute pharyngitis
- Trismus, pain, neck swelling
- Chest pain and dyspnea (pulmonary septic emboli)
- Joint pain, swelling, redness (septic joint)
- Encephalopathy (intracranial involvement)

## Differential diagnosis

- Right-sided endocarditis
- Cervical Lymphadenitis
- Malignancy
- Organizing Pneumonia

## Treatment

- Antibiotics
- Anticoagulation- Limited data on efficacy and not typically used
- Drainage or debridement

# Imaging Findings

## Ultrasound

- Fast screening for venous thrombosis

## CT

- Tonsil fullness, edema, less commonly abscess
- Ipsilateral vein thrombosis, usually internal jugular but other small tributaries may be involved
- Inflammatory changes in the neck
- Metastatic seeding
  - Pulmonary nodules (80%); pulmonary septic emboli classically cavitate
  - Septic joint (15%)

## MRI

- Evaluate for intracranial and orbital complications such as meningitis, abscess, cavernous sinus thrombosis
- Consider MRV for cerebral vein thrombosis

# References

Johannesen KM, Bodtger U. Lemierre's syndrome: current perspectives on diagnosis and management. *Infect Drug Resist.* 2016 Sep 14;9:221-227. doi: 10.2147/IDR.S95050. PMID: 27695351; PMCID: PMC5028102.

Lee WS, Jean SS, Chen FL, Hsieh SM, Hsueh PR. Lemierre's syndrome: A forgotten and re-emerging infection. *Journal of Microbiology, Immunology and Infection.* 2020;53(4):513-517. doi:<https://doi.org/10.1016/j.jmii.2020.03.027>

[https://www.uptodate-com.online.uchc.edu/contents/lemierre-syndrome-septic-thrombophlebitis-of-the-internal-jugular-vein?search=lemierre%20syndrome&source=search\\_result&selectedTitle=1~29&usage\\_type=default&display\\_rank=1#H4255990126](https://www.uptodate-com.online.uchc.edu/contents/lemierre-syndrome-septic-thrombophlebitis-of-the-internal-jugular-vein?search=lemierre%20syndrome&source=search_result&selectedTitle=1~29&usage_type=default&display_rank=1#H4255990126)

<https://radiopaedia.org/articles/lemierre-syndrome?lang=us>