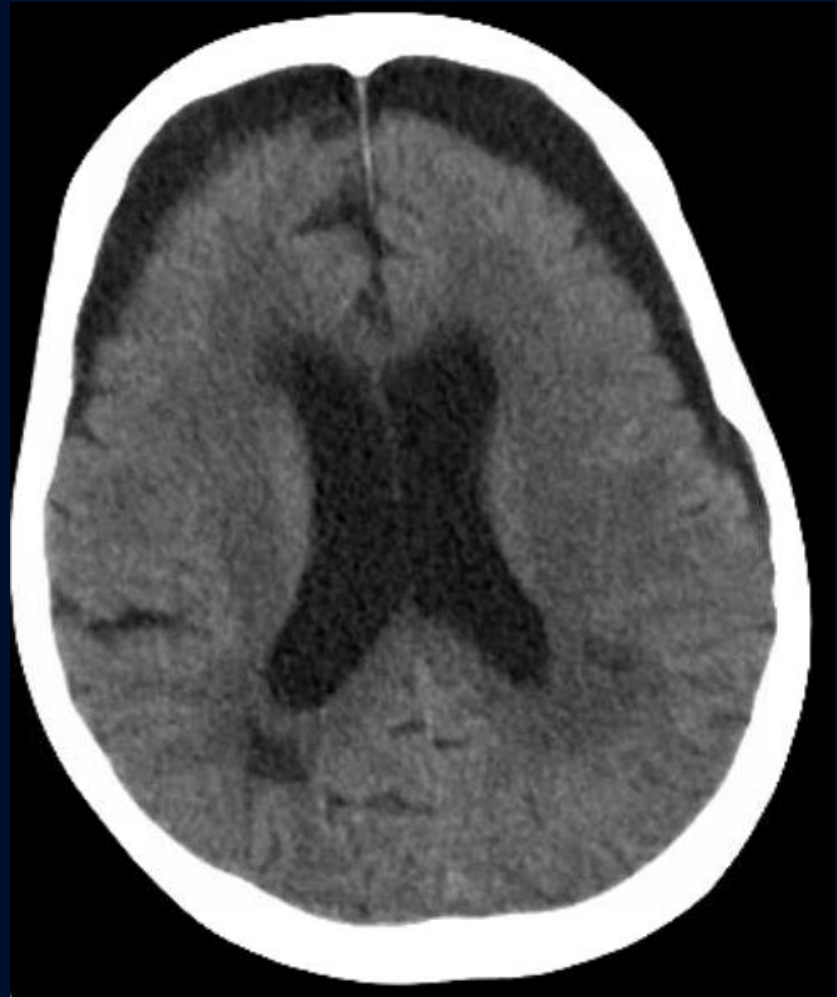
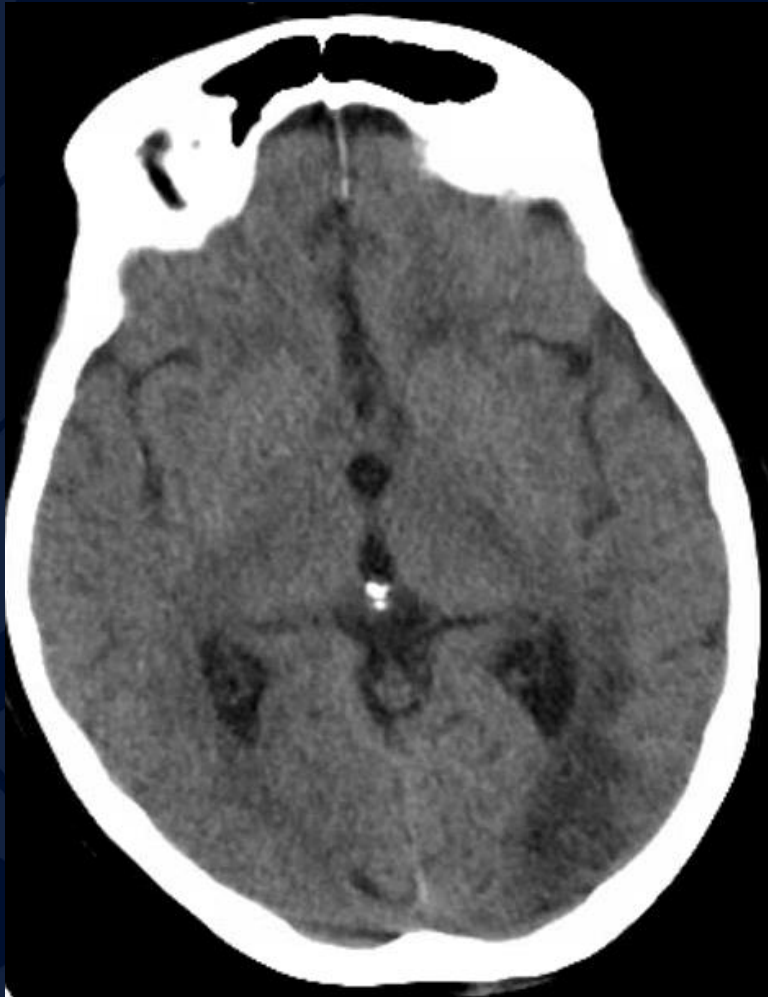
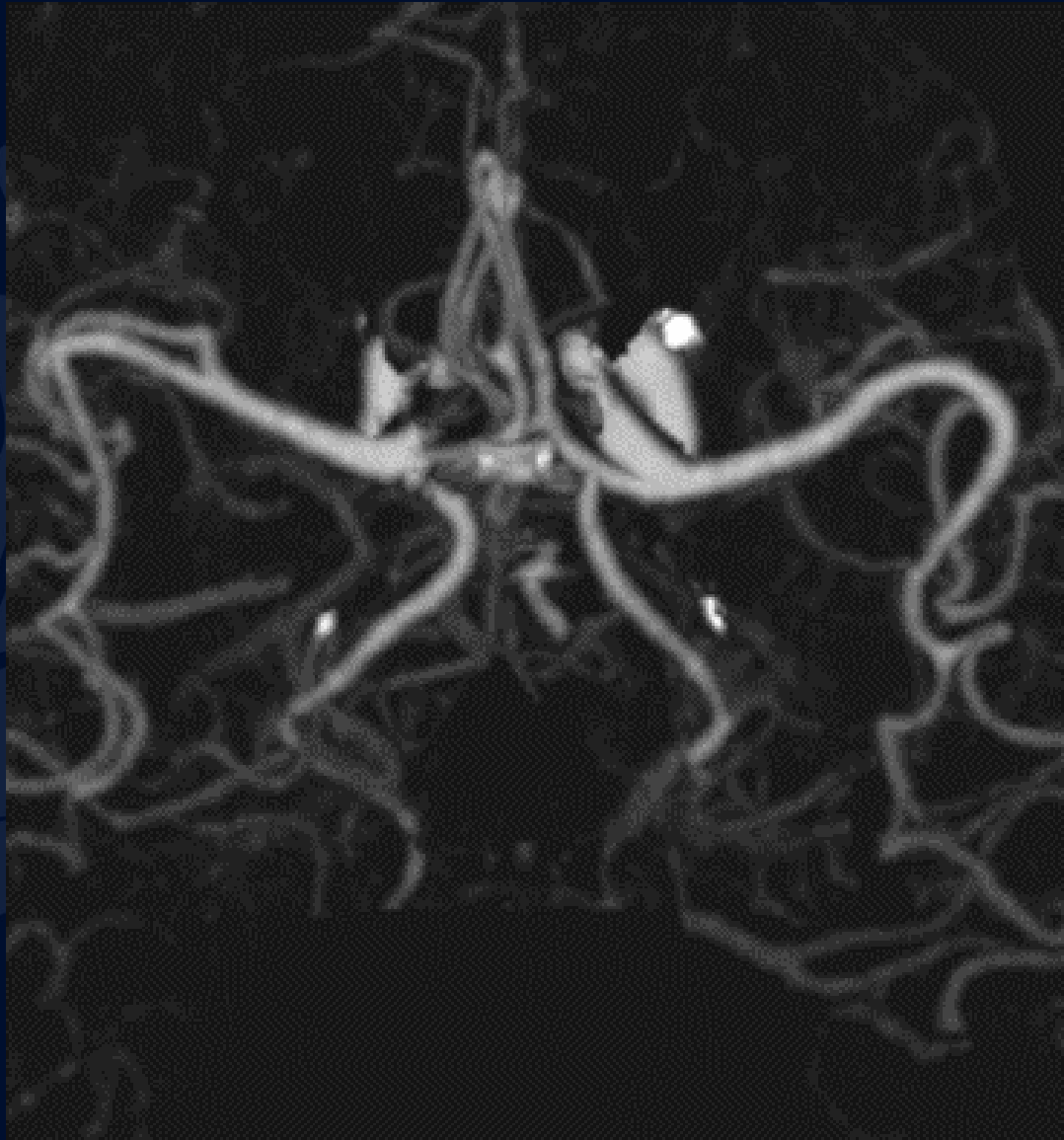
# 80-year-old female with a history of atrial fibrillation presenting with a change in mental status

Shivam Patel, MS3

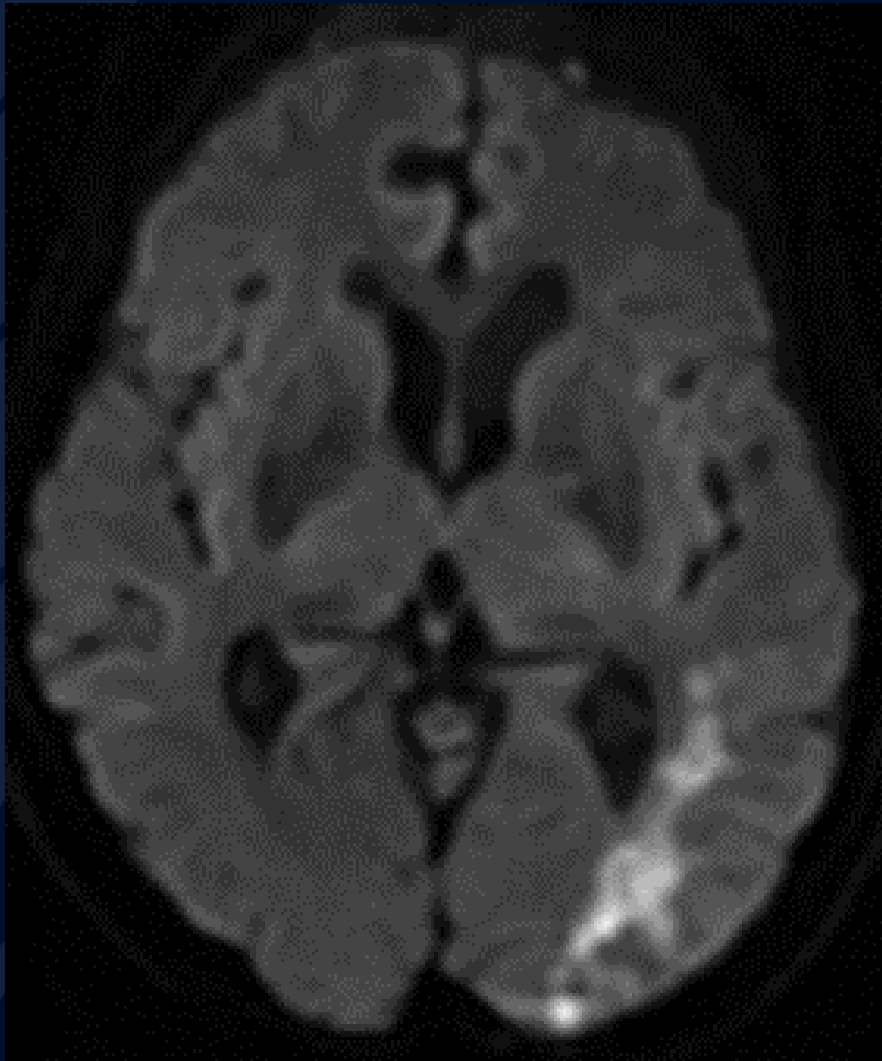
# Non-contrast CT



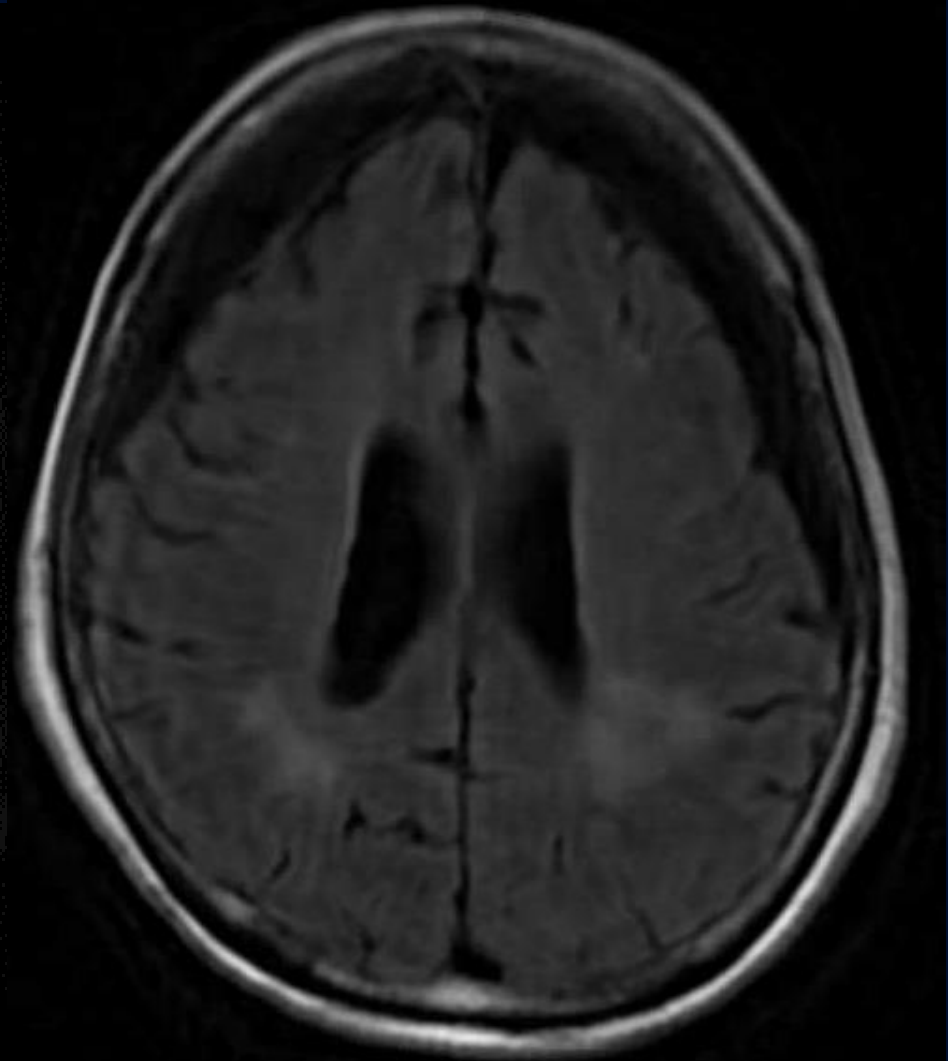
# CTA



DWI

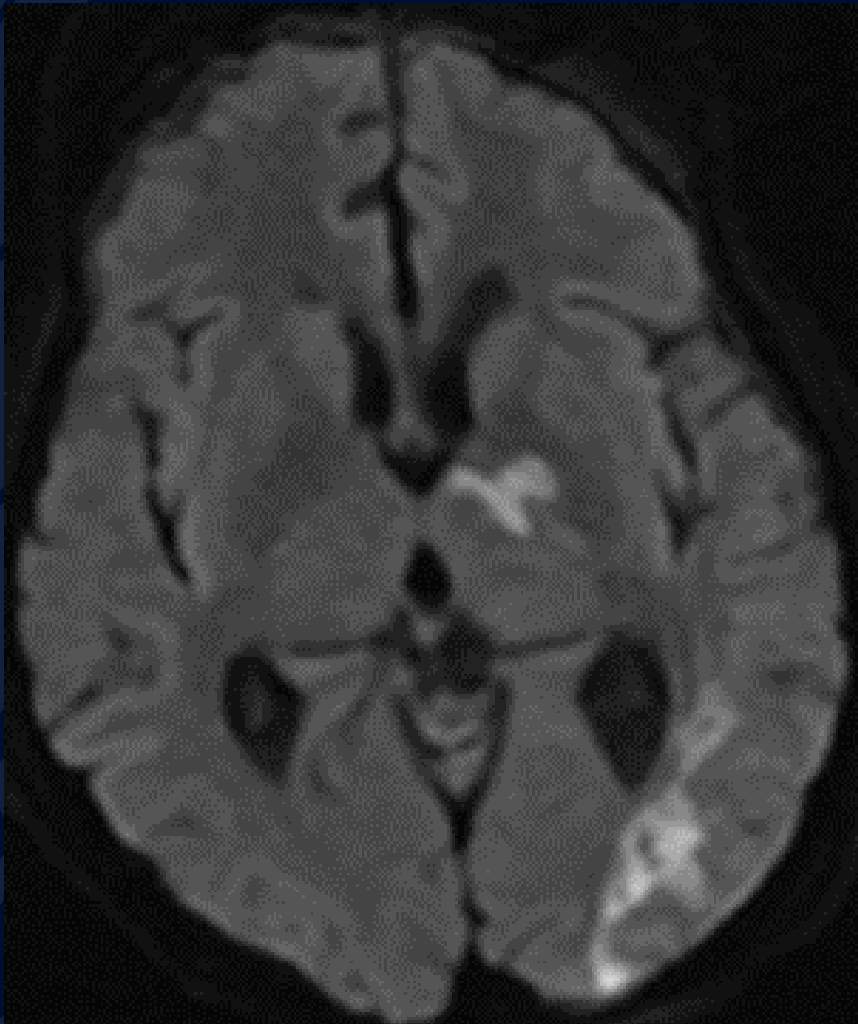


T2 FLAIR

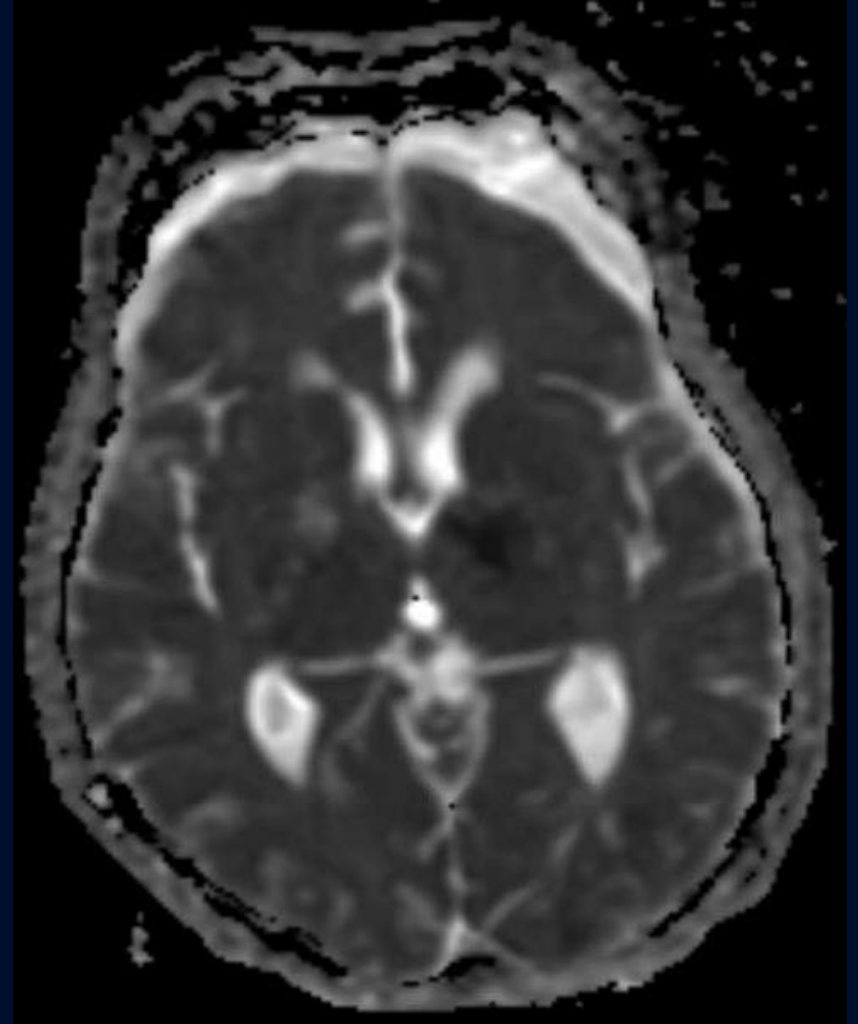


# Follow-up MRI 10 days later

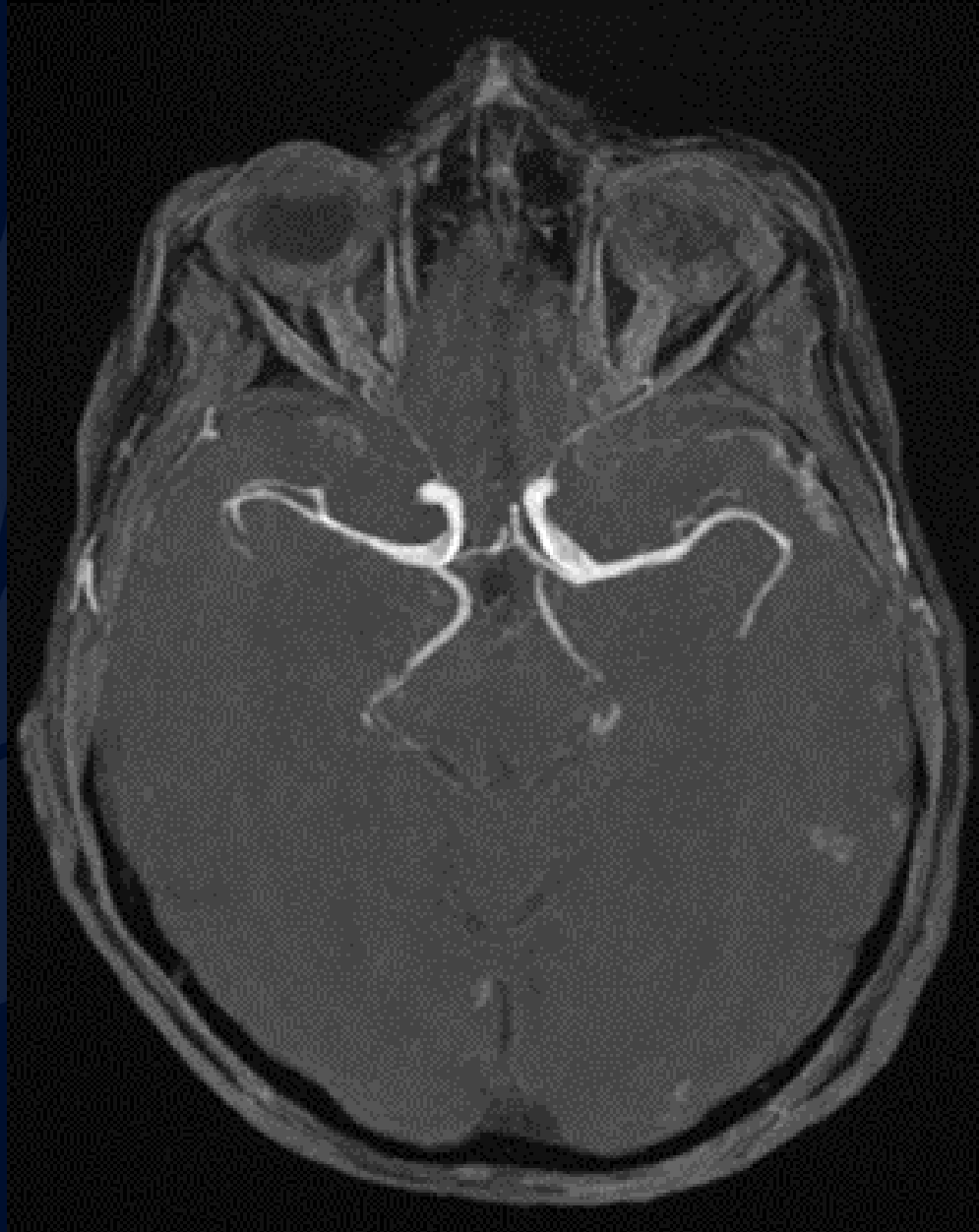DWI



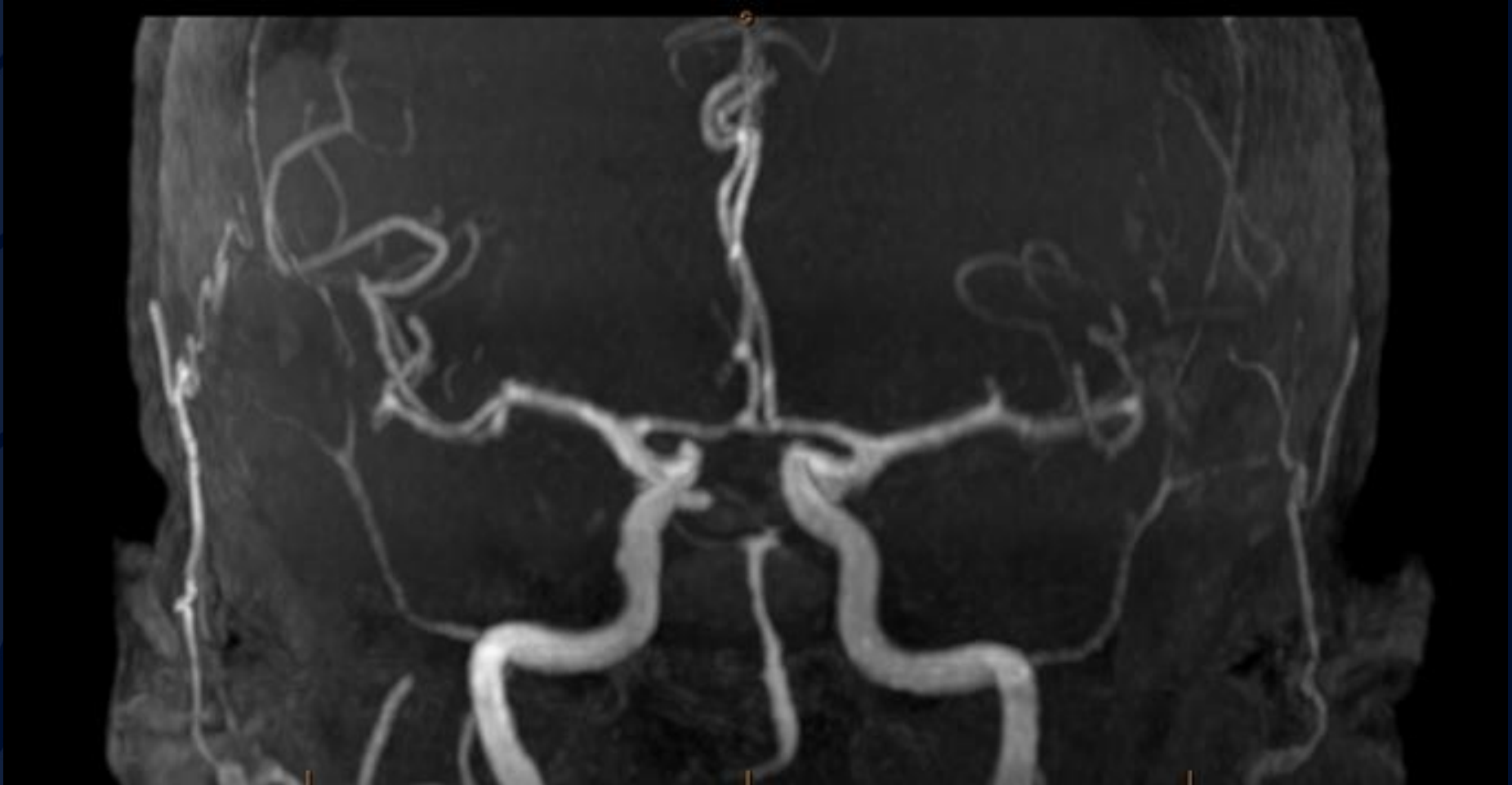ADC



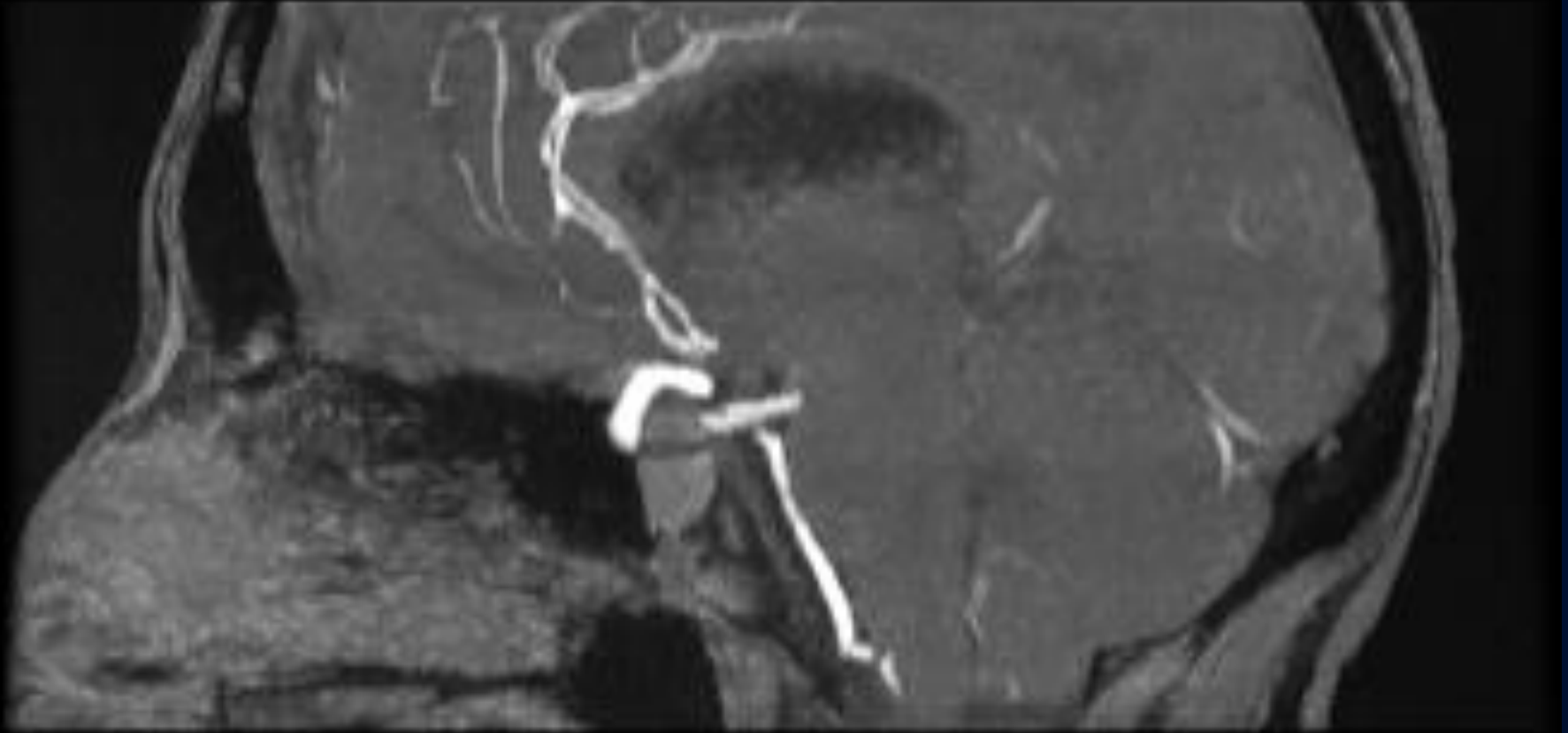MRA



# MRA



# MRA



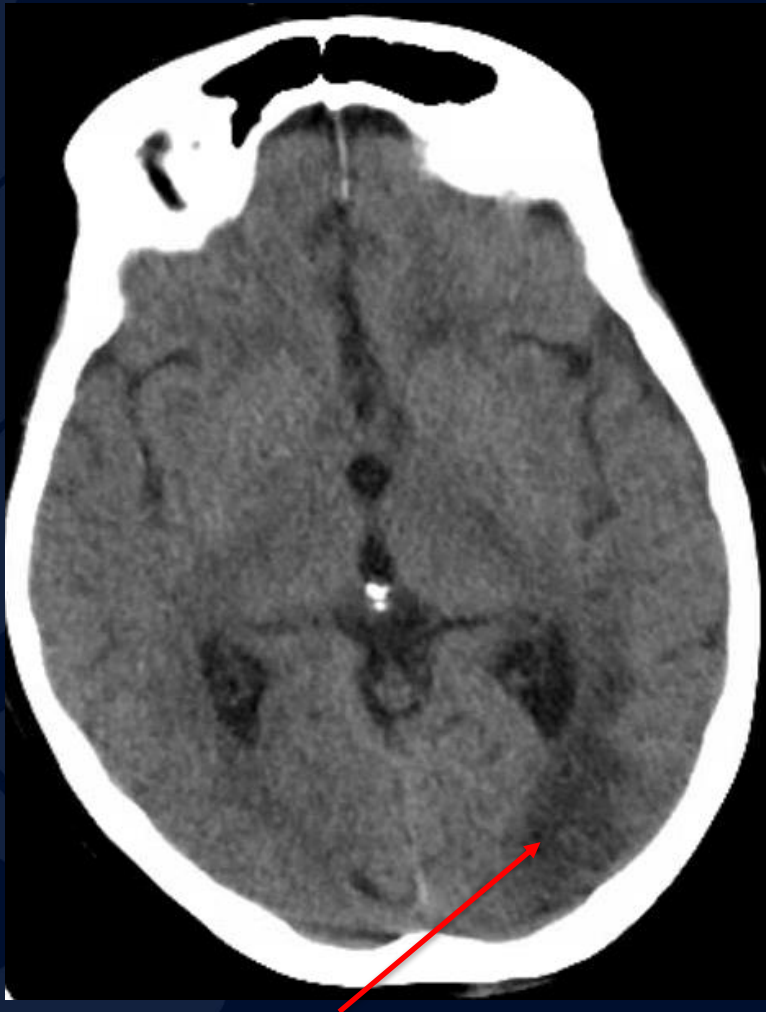



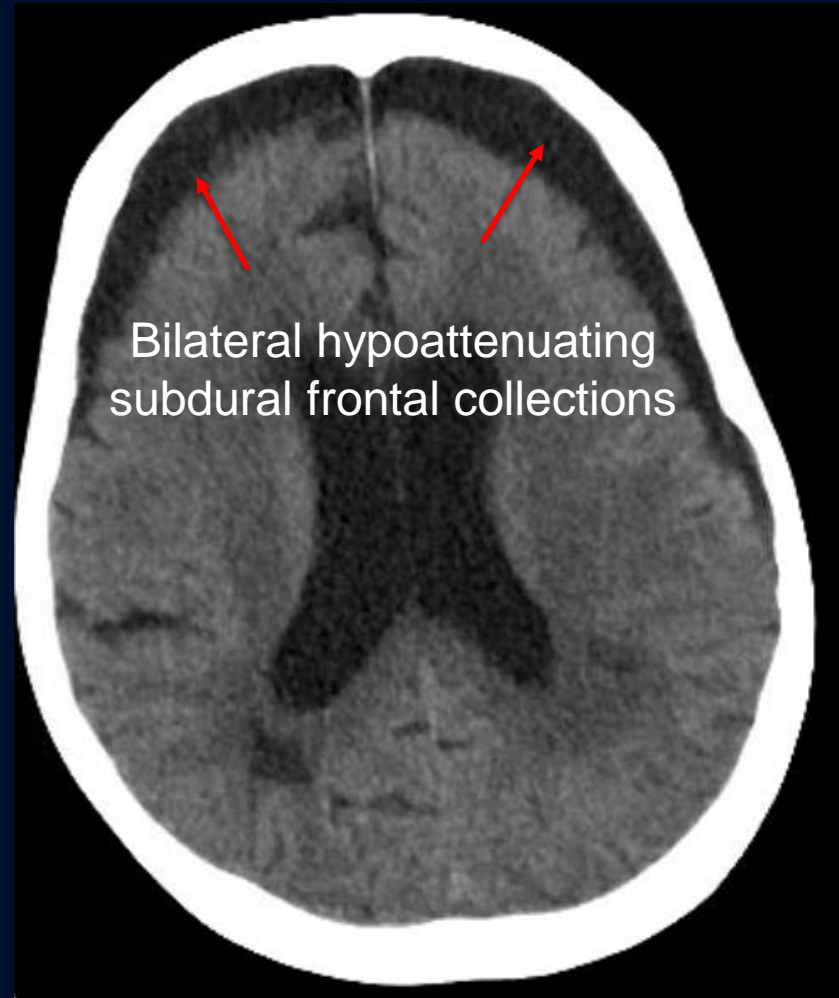
?

# HSV-2 Vasculitis Superimposed on HSV-2 Meningoencephalitis

## Non-contrast CT

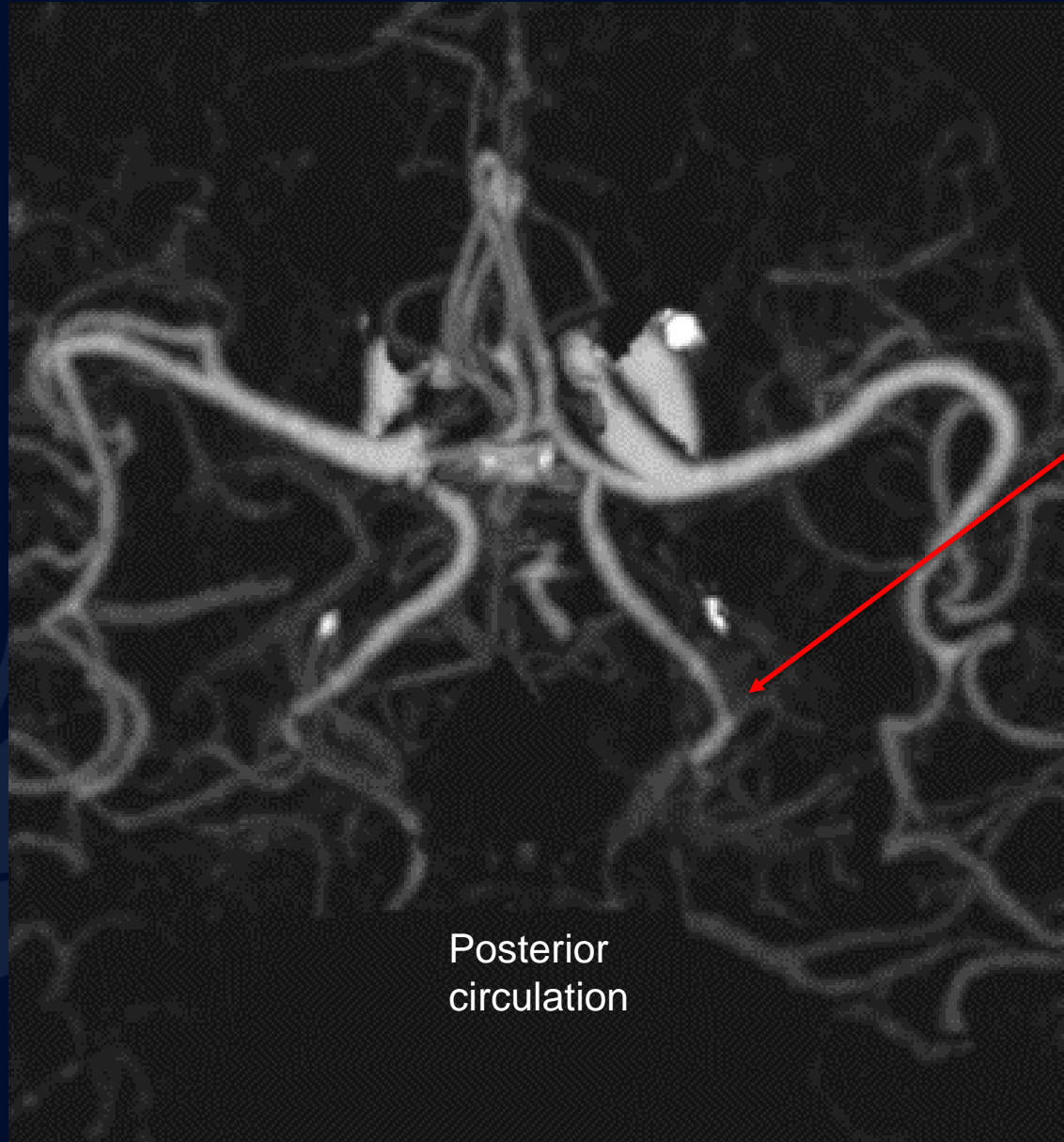


Hypoattenuation in left  
occipital lobe



Bilateral hypoattenuating  
subdural frontal collections

# CTA

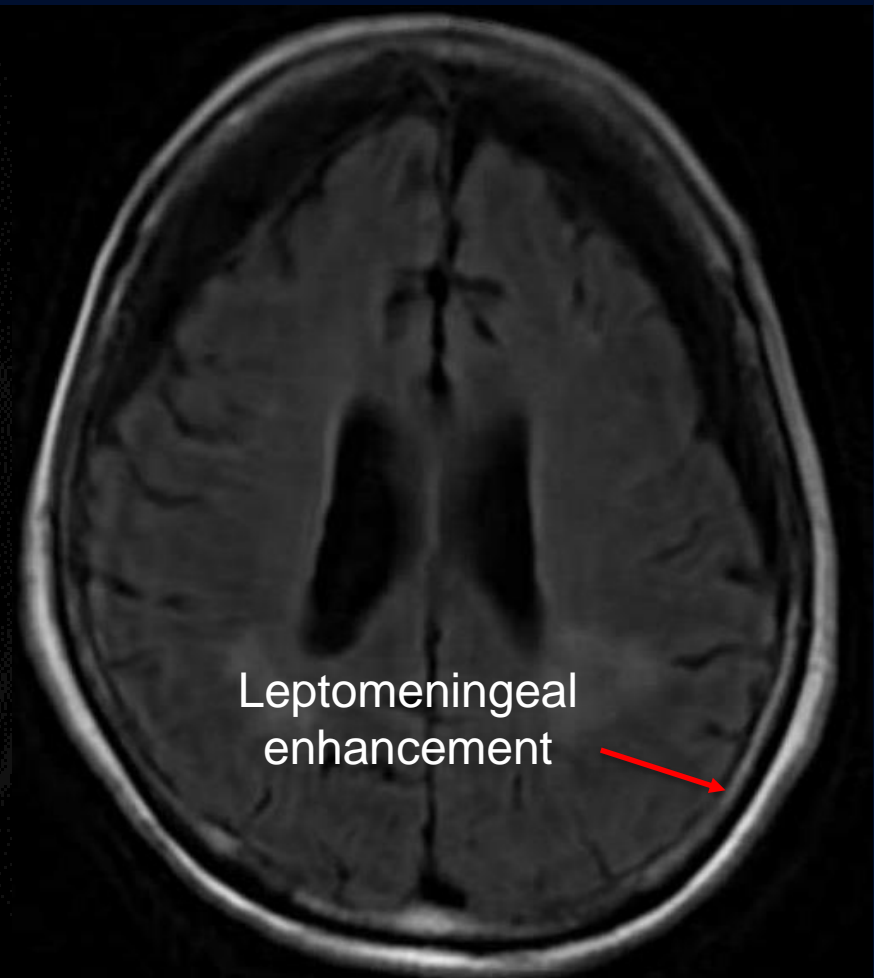
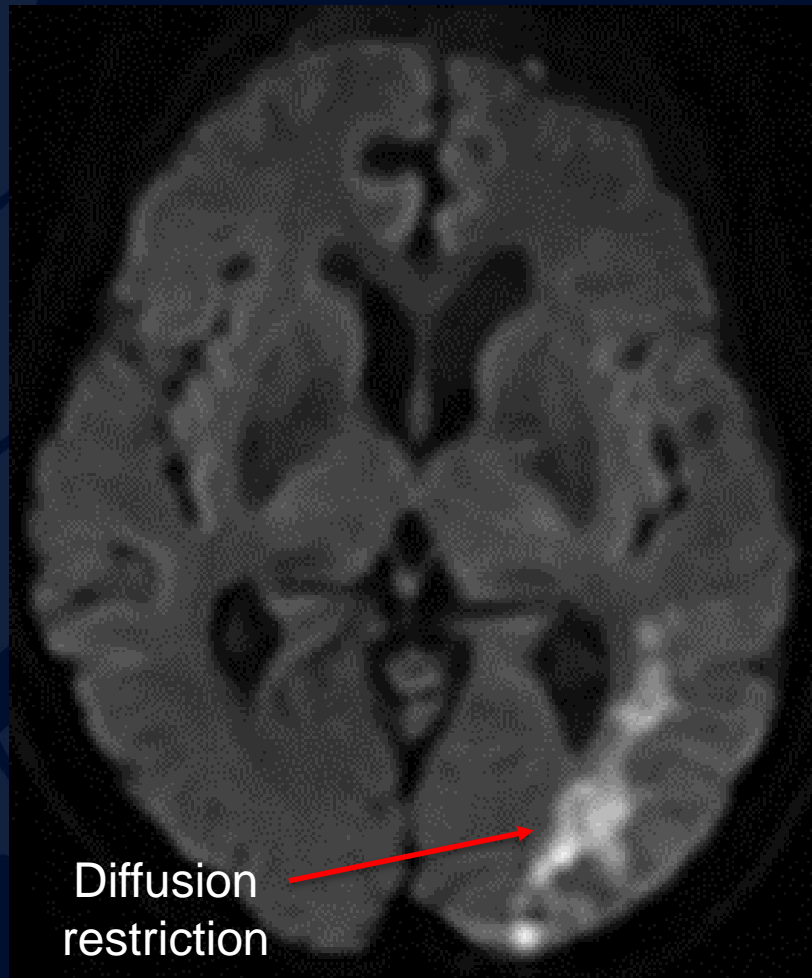


Stenosis of  
left posterior  
cerebral artery

Posterior  
circulation

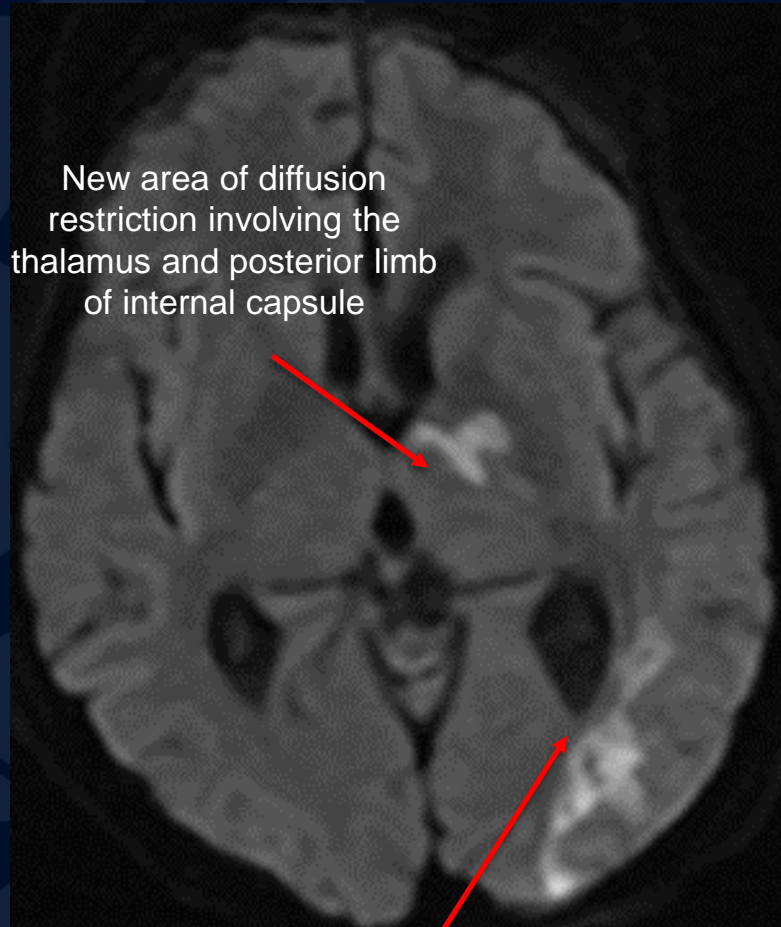
DWI

T2 FLAIR



# Follow-up MRI 10 days later

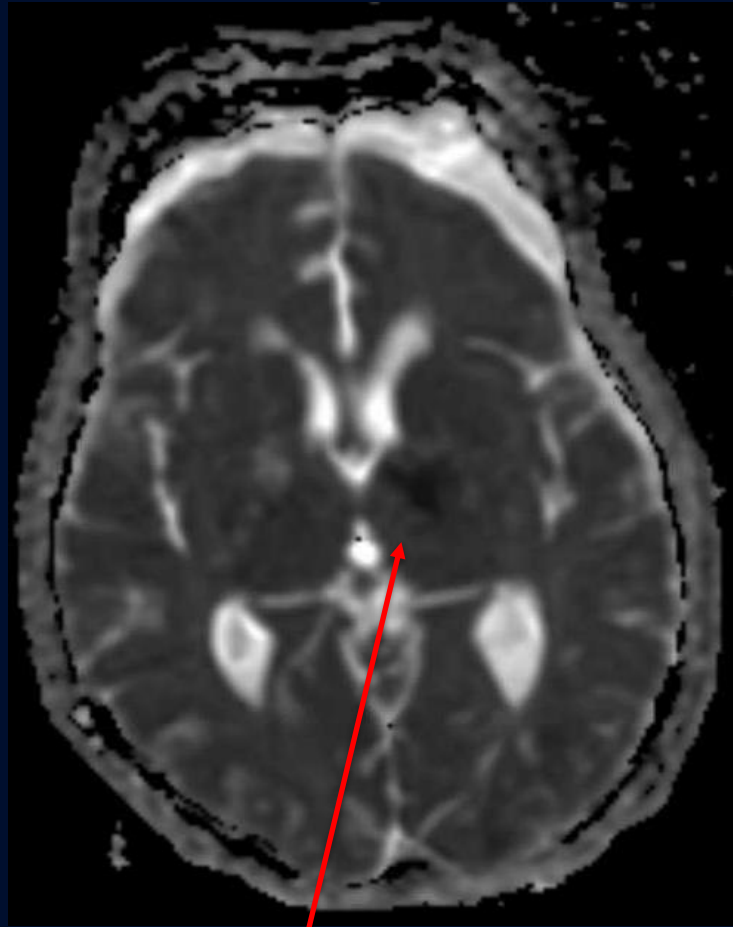
## DWI



New area of diffusion restriction involving the thalamus and posterior limb of internal capsule

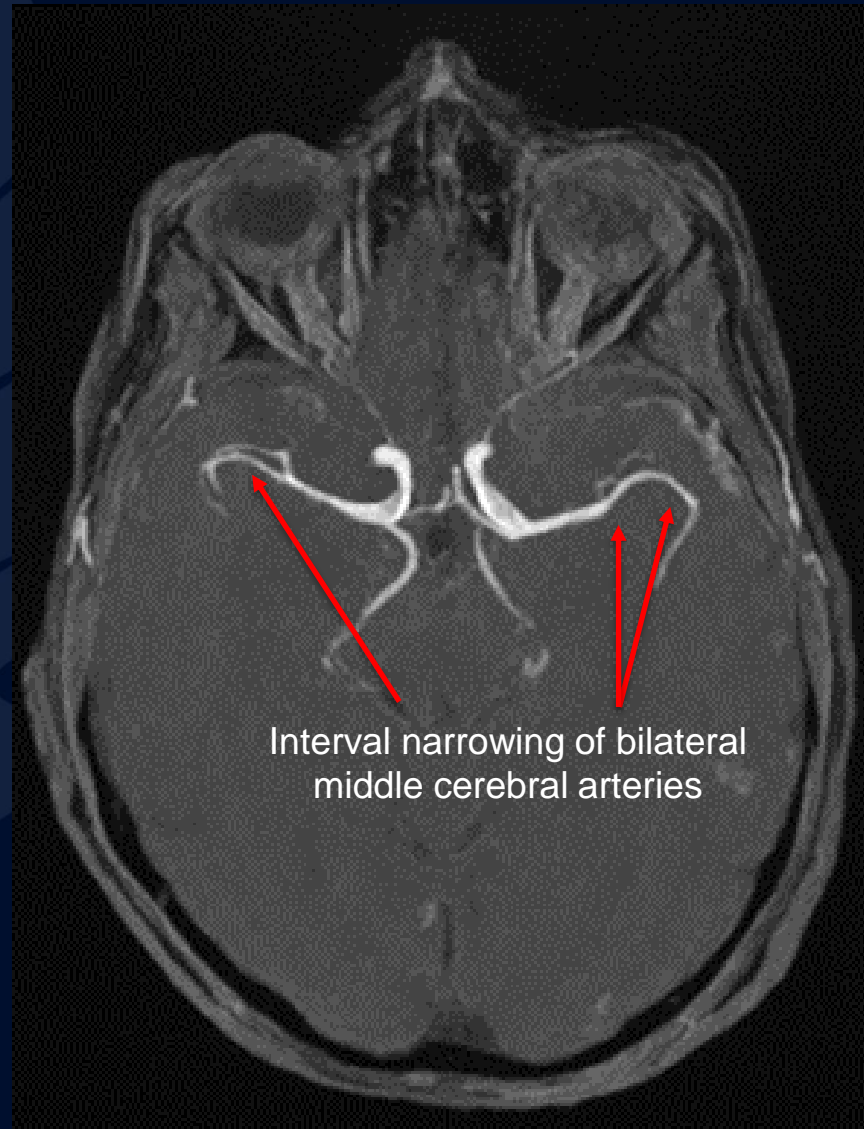
Redemonstrated area of diffusion restriction in left occipital lobe, stable from prior study

## ADC

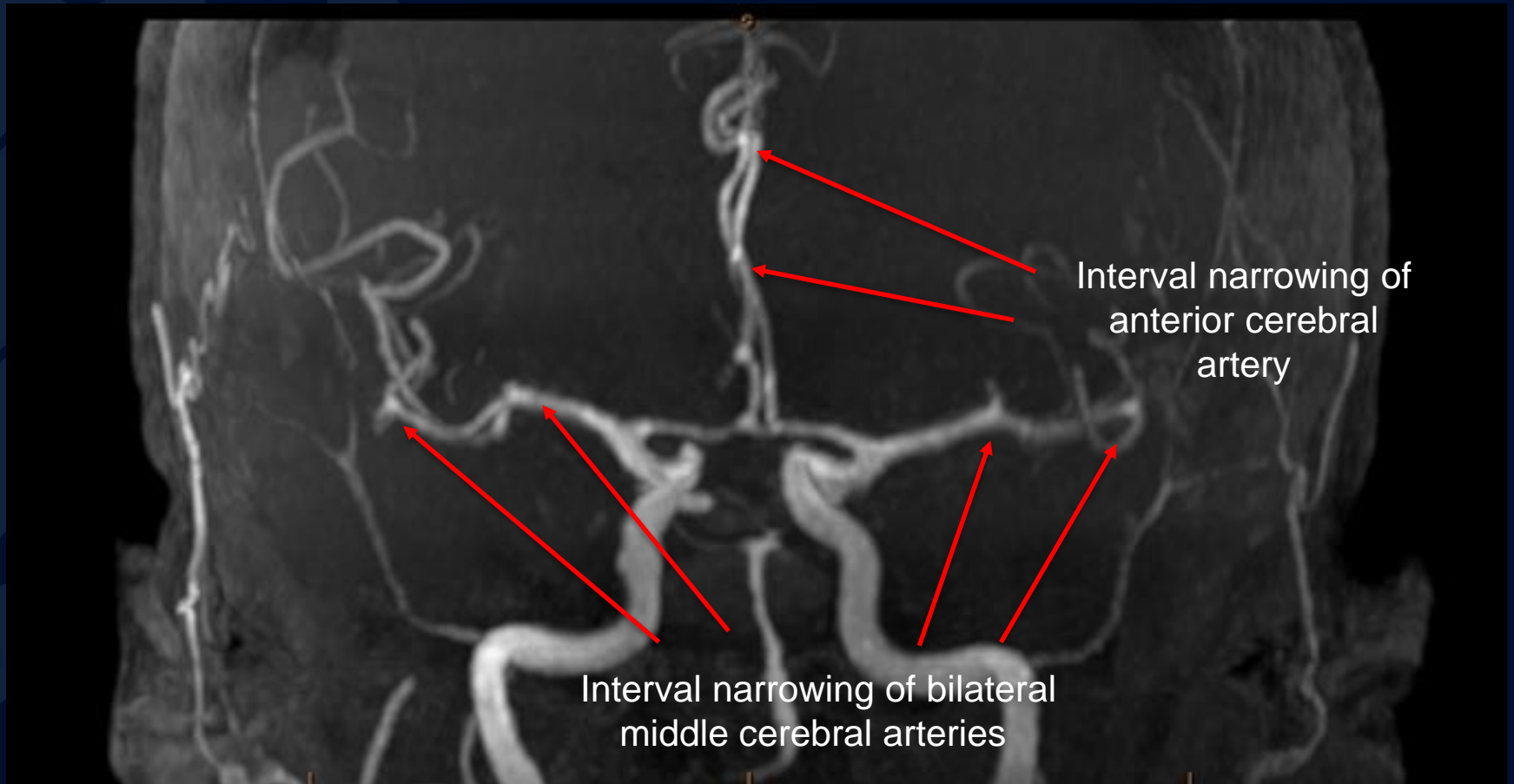


ADC correlated area of hypointensity

# MRA

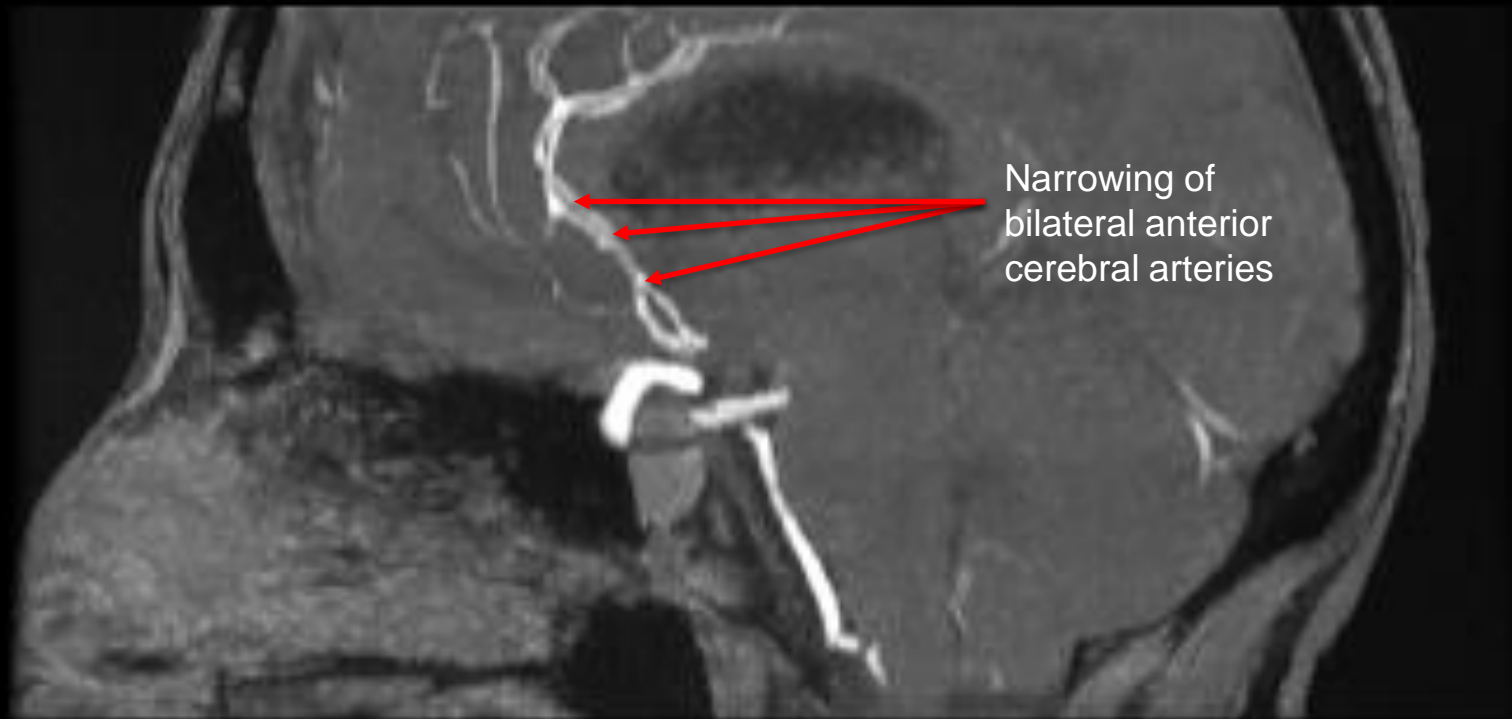


# MRA





# MRA



# HSV-2 Vasculitis Superimposed on HSV-2 Meningoencephalitis

- Herpes simplex virus (HSV) infection can cause a variety of commonly observed CNS manifestations including encephalitis, meningitis, and myelitis.
- HSV-2 has been implicated as a rare cause of ischemic strokes in adults. The proposed mechanism of ischemia is multifocal large vessel vasculitis.

# References

- Siva A. (2001). Vasculitis of the nervous system. *Journal of neurology*, 248(6), 451–468.  
<https://doi.org/10.1007/s004150170154>
- Fan, T. H., Khoury, J., Cho, S. M., Bhimraj, A., Shoskes, A., & Uchino, K. (2020). Cerebrovascular complications and vasculopathy in patients with herpes simplex virus central nervous system infection. *Journal of the neurological sciences*, 419, 117200.  
<https://doi.org/10.1016/j.jns.2020.117200>
- Chow, E., & Troy, S. B. (2014). The differential diagnosis of hypoglycorrhachia in adult patients. *The American journal of the medical sciences*, 348(3), 186–190.  
<https://doi.org/10.1097/MAJ.0000000000000217>
- Berlitz P, Kraemer M. Cerebral vasculitis in adults: what are the steps in order to establish the diagnosis? Red flags and pitfalls. *Clin Exp Immunol*. 2014 Mar;175(3):419-24.
- Byram, K., Hajj-Ali, R. A., & Calabrese, L. (2018). CNS Vasculitis: an Approach to Differential Diagnosis and Management. *Current rheumatology reports*, 20(7), 37