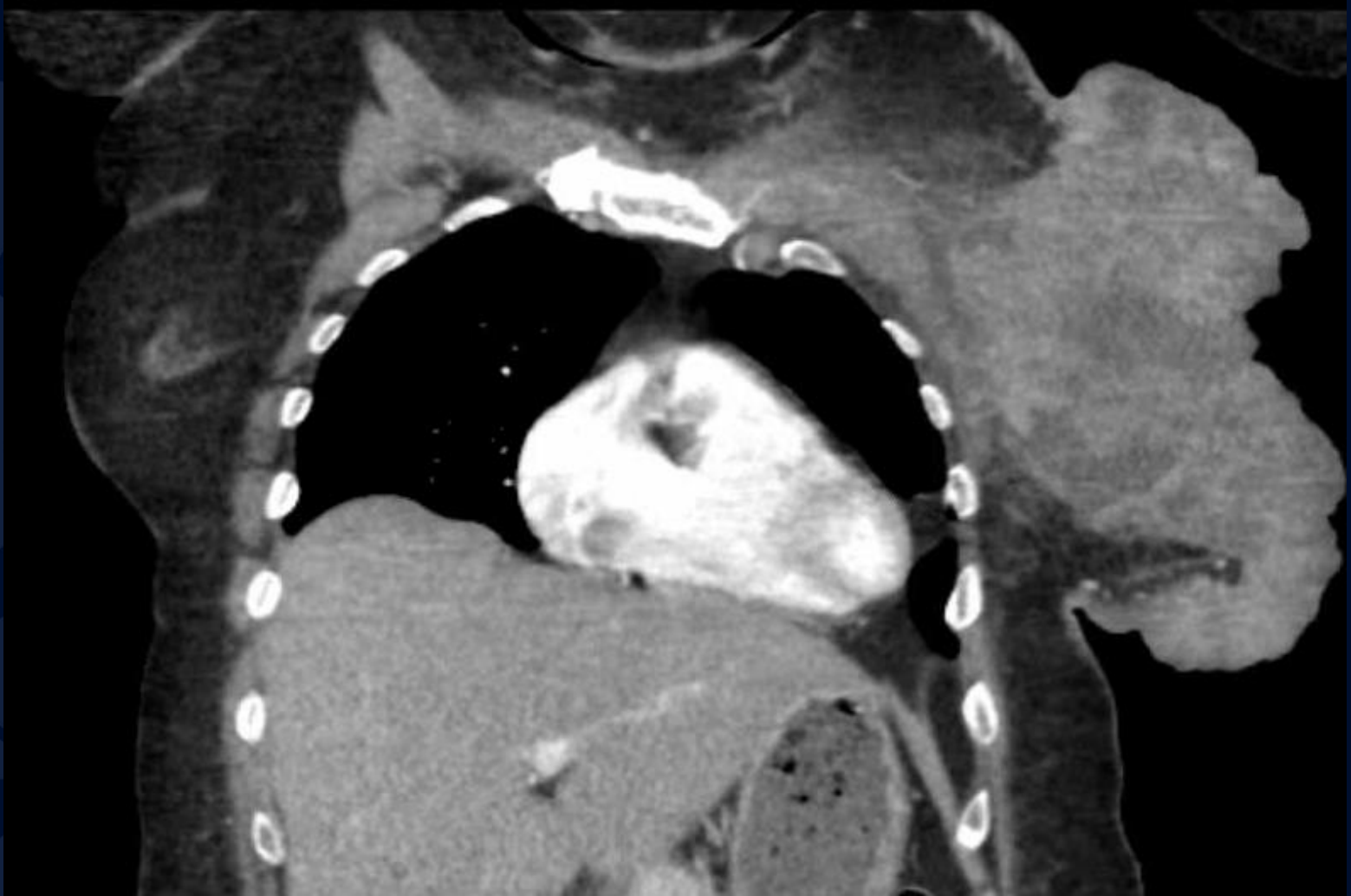
A large, stylized leaf graphic in a dark blue color, positioned on the left side of the slide. The leaf has a prominent vein structure and a wavy, serrated edge.

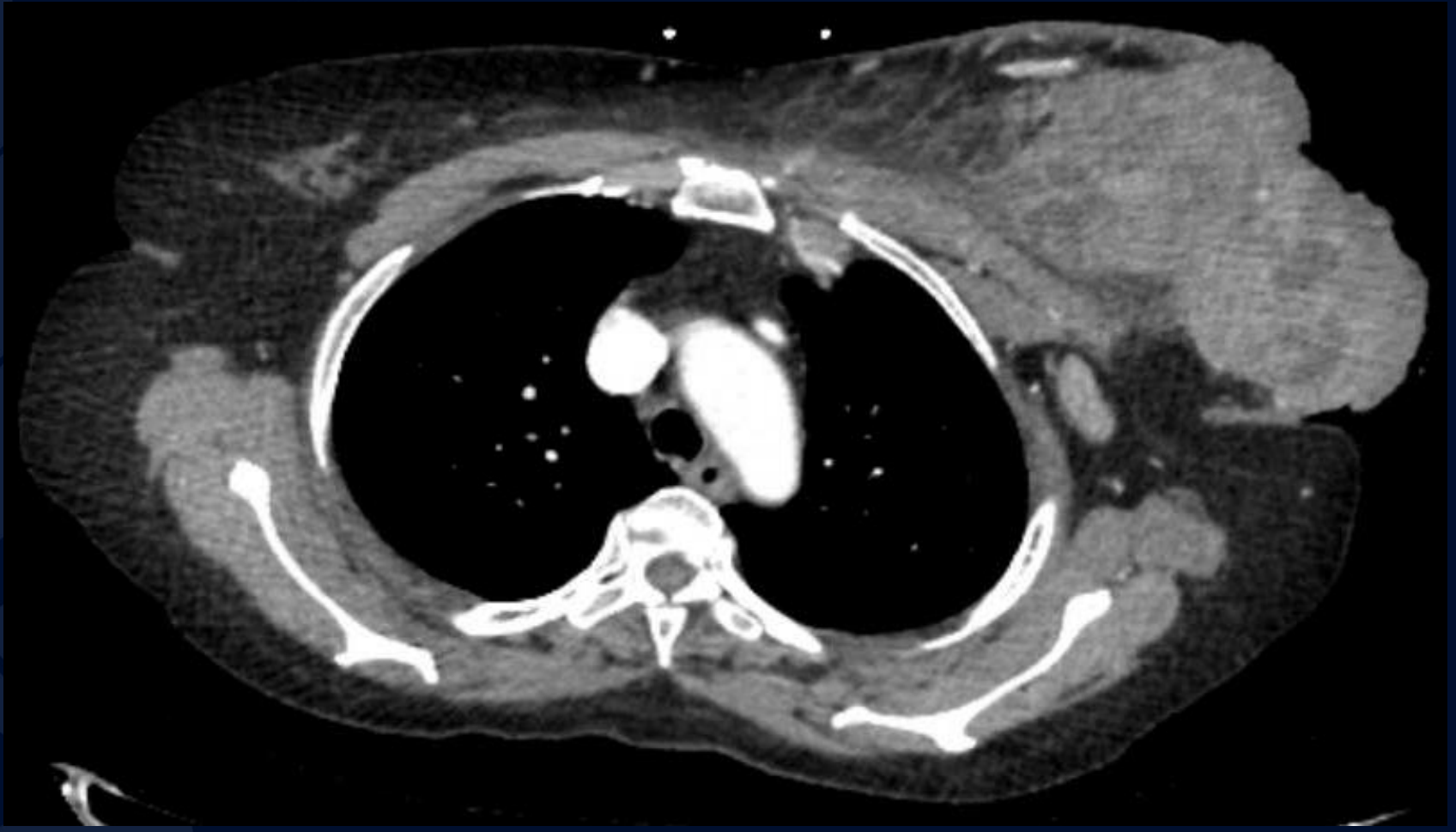60-year-old female presenting with fevers, chills and painful left breast mass

Ashley Hine, MS3

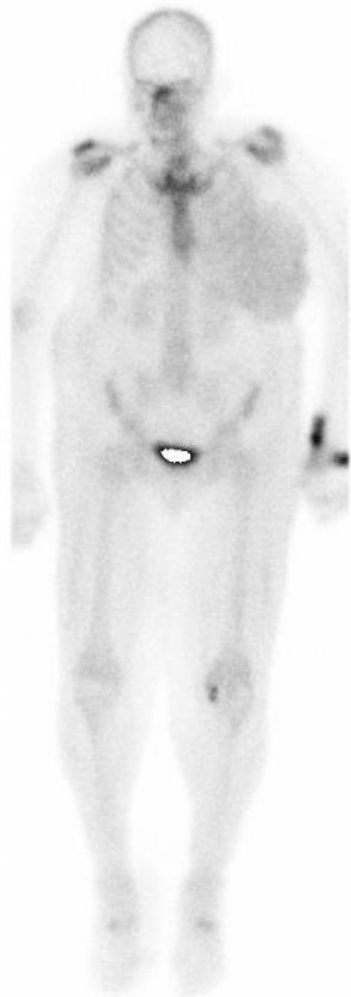
CT IV Contrast



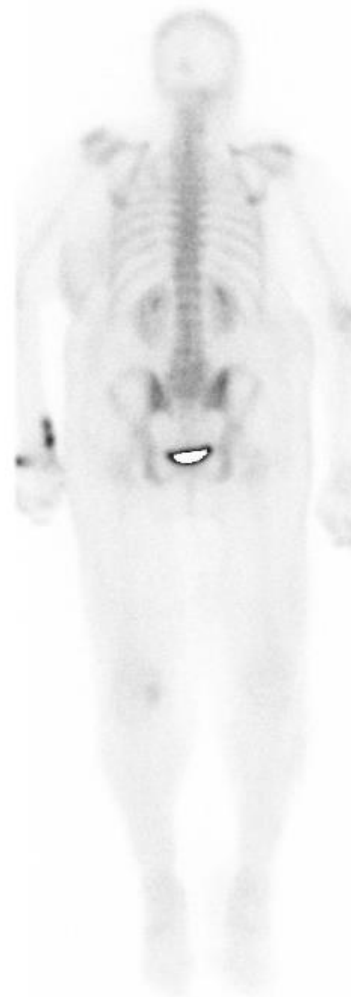CT Thorax IV Contrast



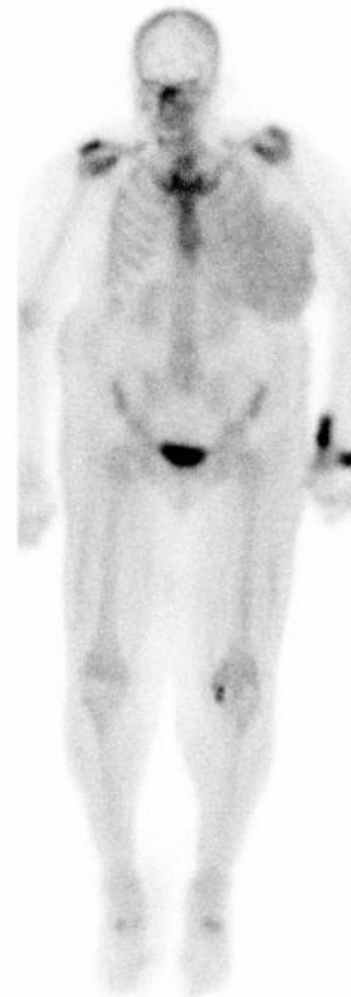27.0 mCi Tc99m MDP/Lt Wrist/IV



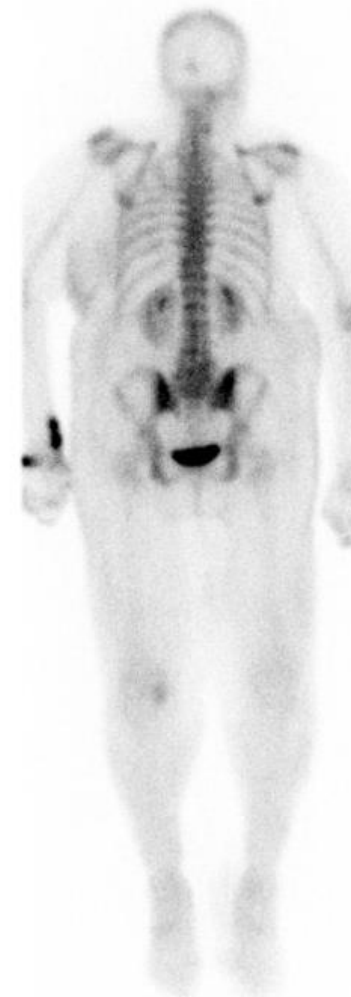R ANTERIOR L



L POSTERIOR R



R ANTERIOR L



L POSTERIOR R


Nuclear Medicine Bone Scan

UConn
HEALTH

RADIOLOGY

A large, stylized oak leaf graphic in a dark blue color, positioned on the left side of the slide. It features detailed vein patterns and a lobed edge.

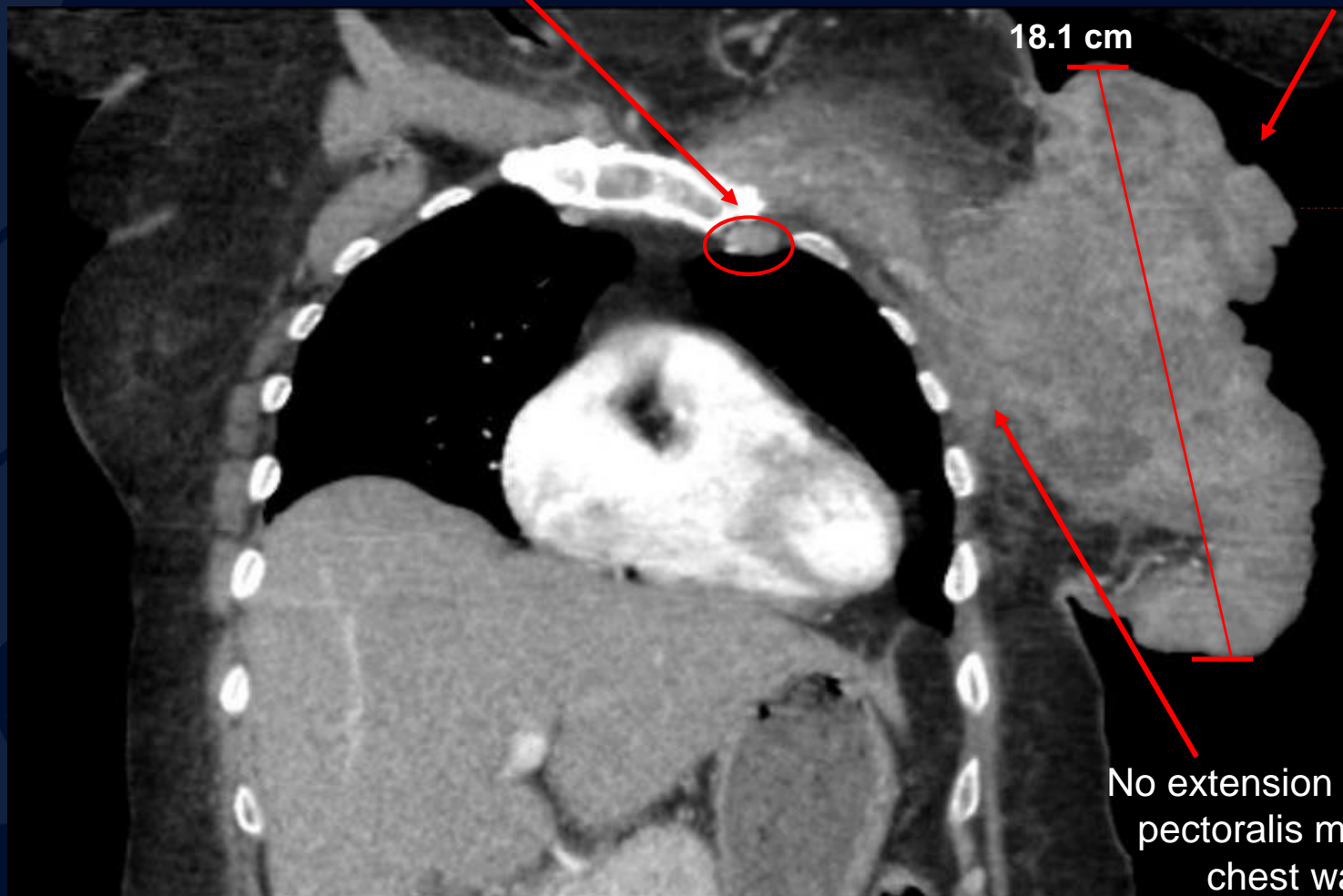
?

A large, stylized oak leaf graphic in a dark blue color, positioned on the left side of the slide, partially overlapping the main text.

Locally Advanced Breast Cancer (LABC)

Enlarged left upper internal
mammary lymph node

Large irregularly shaped,
heterogeneously
enhancing left breast
mass



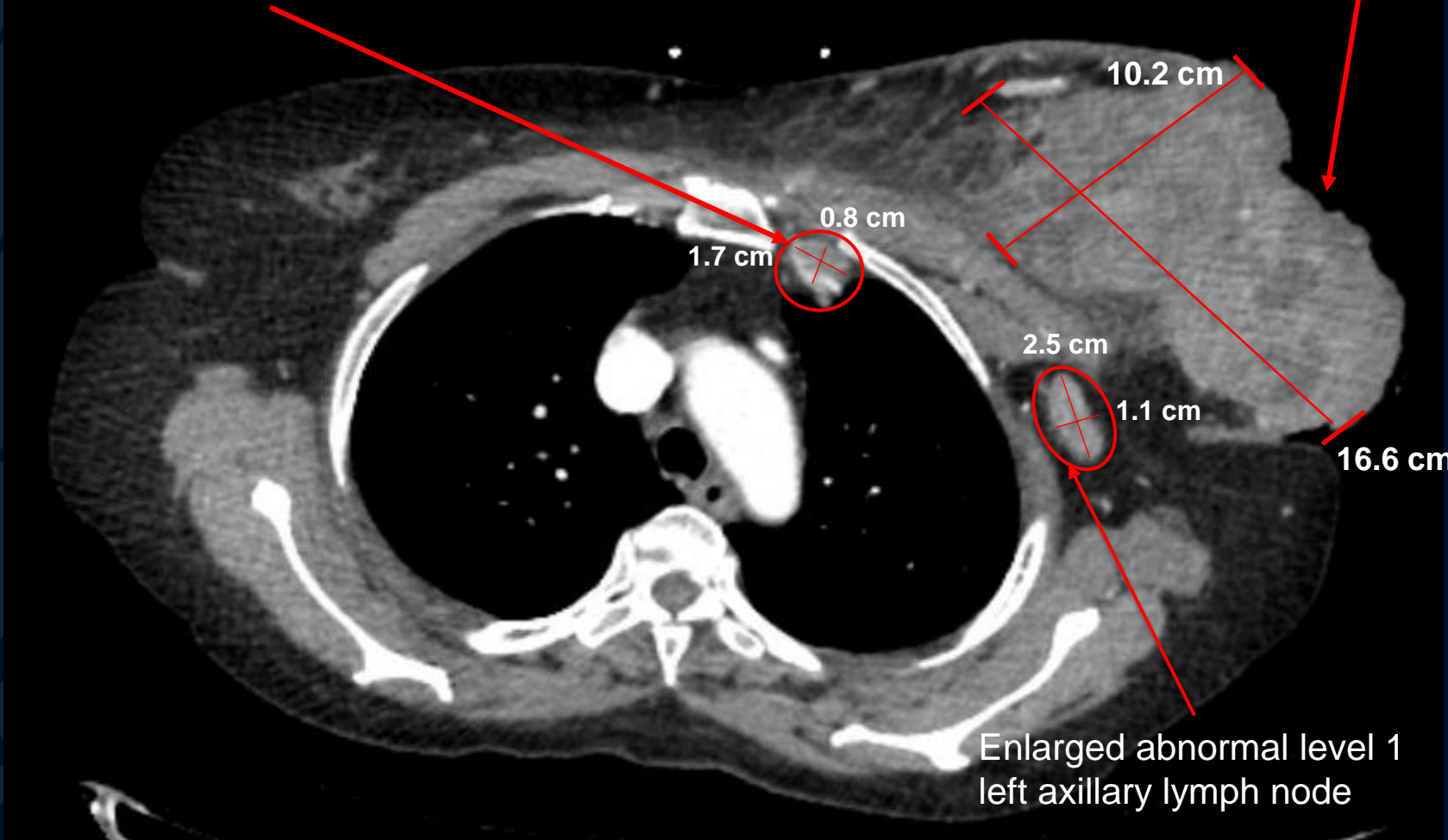
18.1 cm

No extension into underlying
pectoralis muscles of the
chest wall or ribs

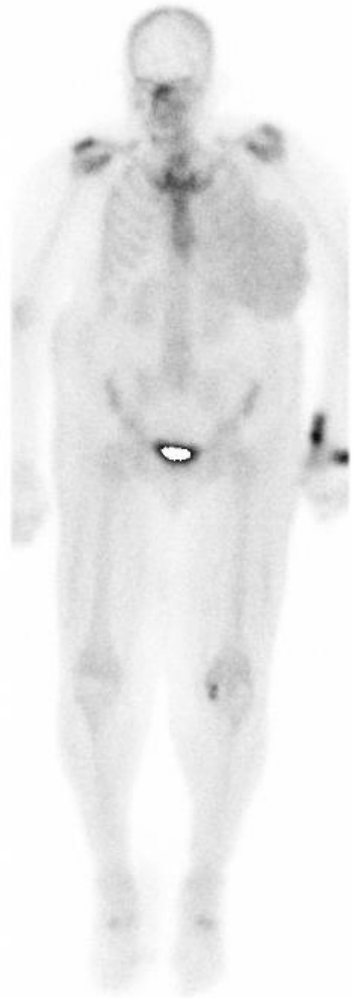
CT Thorax IV Contrast

Enlarged left upper internal
mammary lymph node

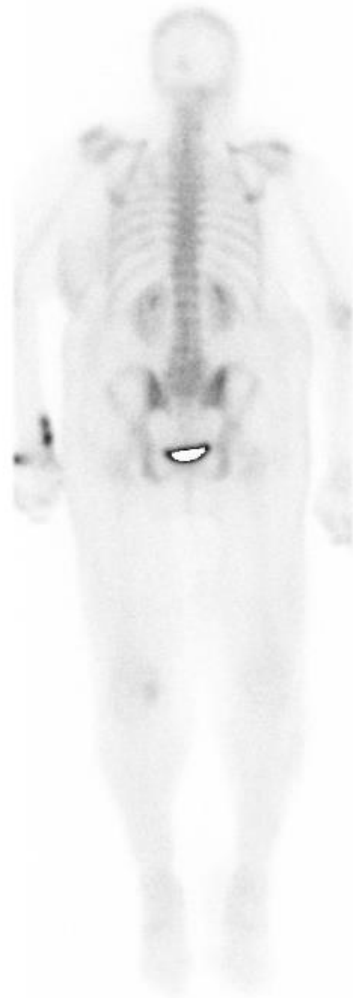Left breast skin thickening with
subcutaneous inflammation



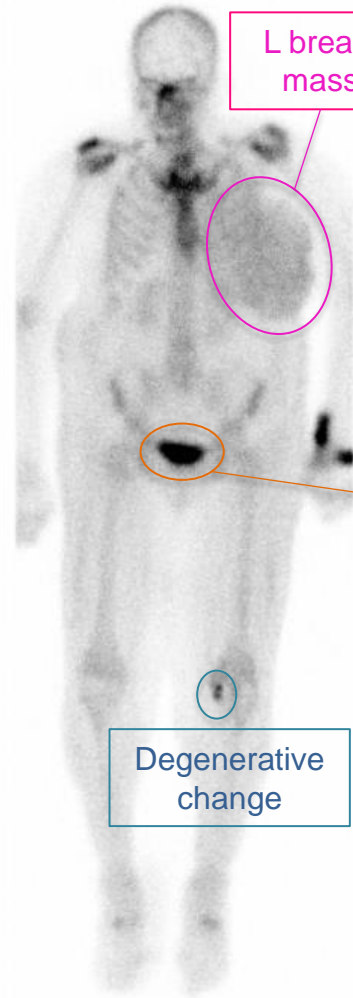
CT Thorax IV Contrast



R ANTERIOR L

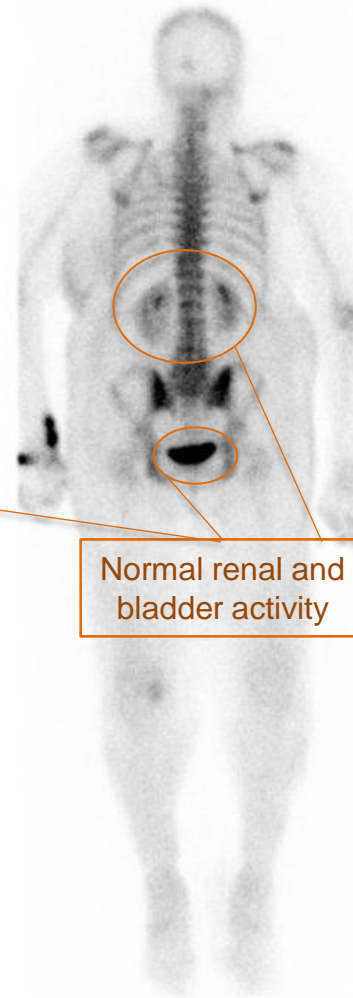


L POSTERIOR R



L breast mass

Degenerative change



Normal renal and bladder activity

Nuclear Medicine Bone Scan

- Soft tissue uptake of radiotracer in the left breast
- No evidence of metastatic disease

Locally advanced breast cancer (LABC)

LABC is uncommon in developed countries where breast cancer screening is widely available.

- Represents 10-30% of all new breast cancer diagnoses worldwide and is associated with a poor prognosis
- 2-5% of LABCs present with a fungating wound as a result of malignant infiltration of the skin causing breakdown, ulceration and infection
 - Often a delay to seek medical attention is involved due to shame/fear, inaccessible care, low socioeconomic status.

Extensive breast masses do not specifically require initial imaging with mammography/US.

- **CT with contrast** is an ideal option to evaluate findings concerning for malignancy.

Treatment is multimodal consisting of wound care, neoadjuvant systemic therapy ± immunotherapy, surgery, and radiation.

References

- Bruce NR, Carlson JT, Barnard KJ, Henry-Tillman R. Phyllodes tumor masquerading as a fungating breast mass. *J Surg Case Rep.* 2017;2017(12):rjx220.
- Carson B, Cox S, Ismael H. Giant siliconoma mimicking locally advanced breast cancer: A case report and review of literature. *Int J Surg Case Rep.* 2018;48:54-60.
- Chung HL, Le-Petross HT, Leung JWT. Imaging Updates to Breast Cancer Lymph Node Management. *Radiographics.* 2021;41(5):1283-1299.
- Liu H, Liu B, Ma Y, et al. Giant Fungated Locally Advanced Breast Carcinoma Responded to Hypofractionated Radiotherapy Combined with Apatinib: A Case Report and Literature Review. *Cancer Manag Res.* 2021;13:605-611.
- Rupert KL, Fehl AJ. A Patient-Centered Approach for the Treatment of Fungating Breast Wounds. *J Adv Pract Oncol.* 2020;11(5):503-510.
- Sosin M, Pulcrano M, Feldman ED, et al. Giant juvenile fibroadenoma: a systematic review with diagnostic and treatment recommendations. *Gland Surg.* 2015;4(4):312-321.