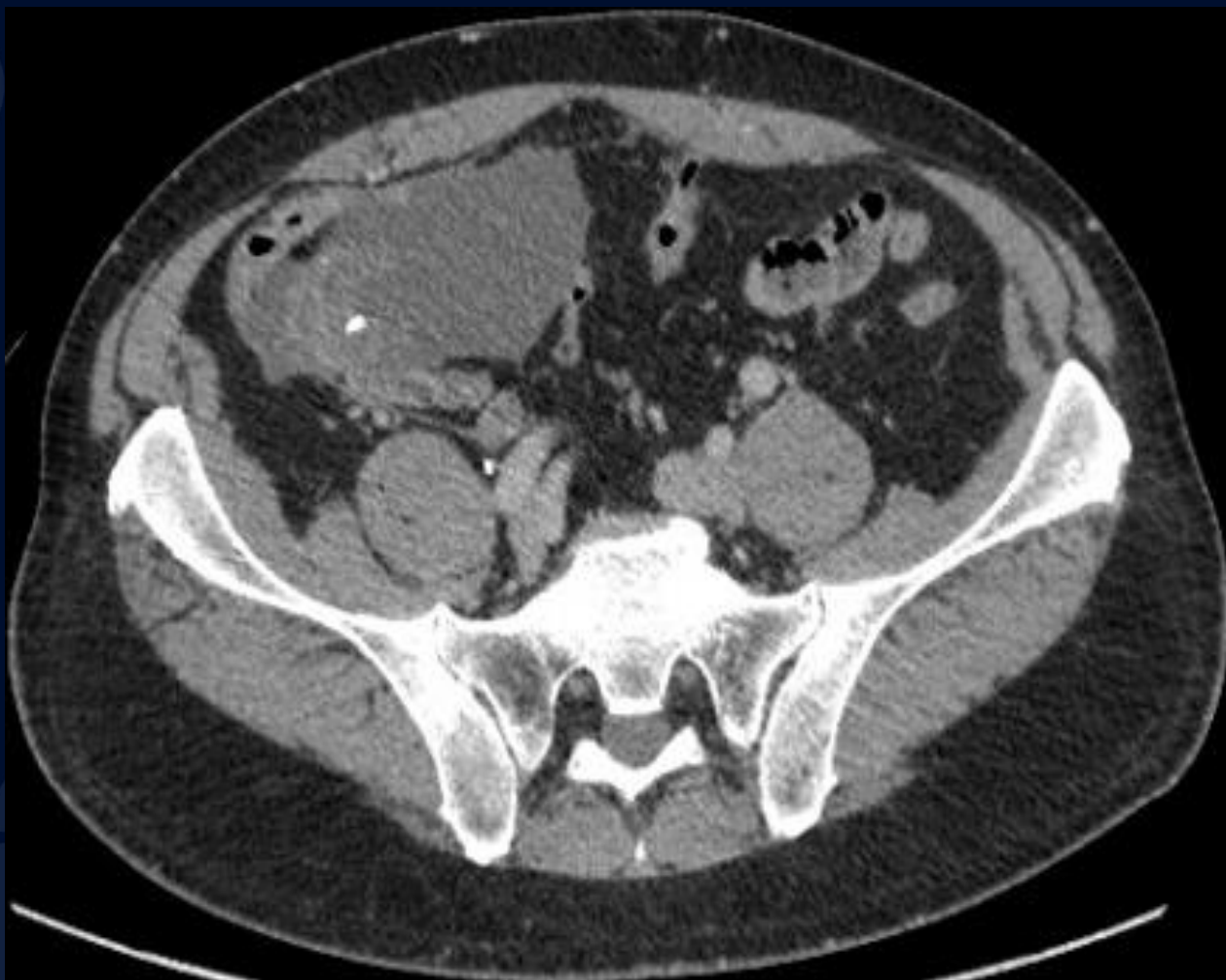

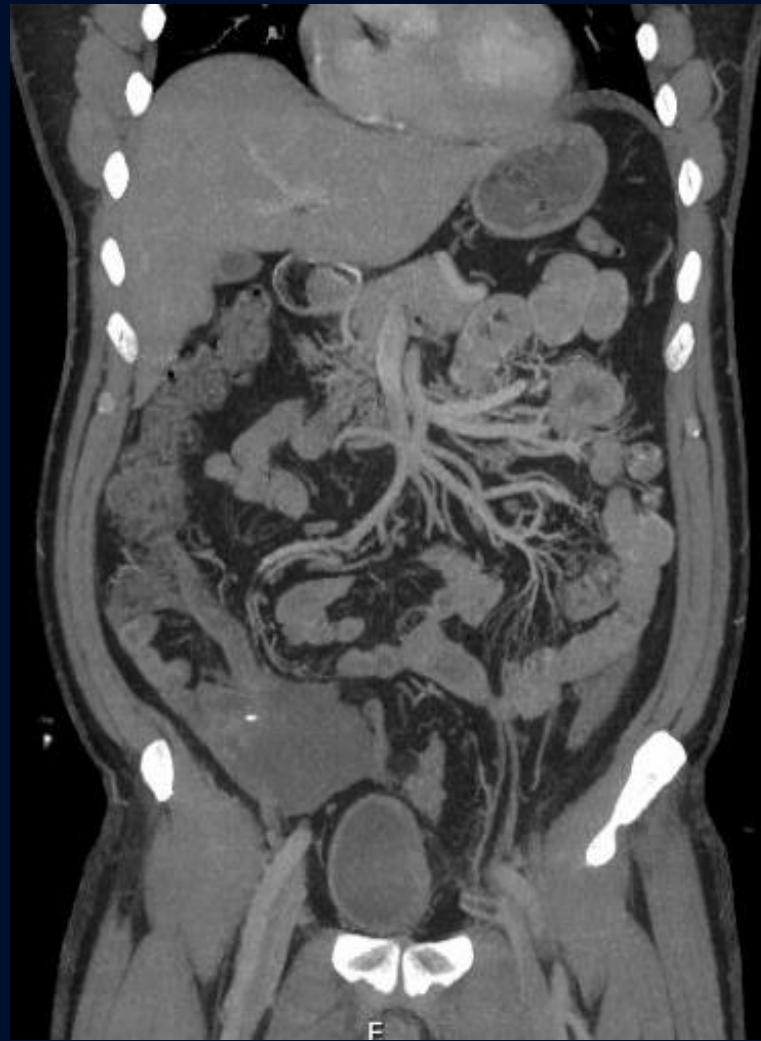
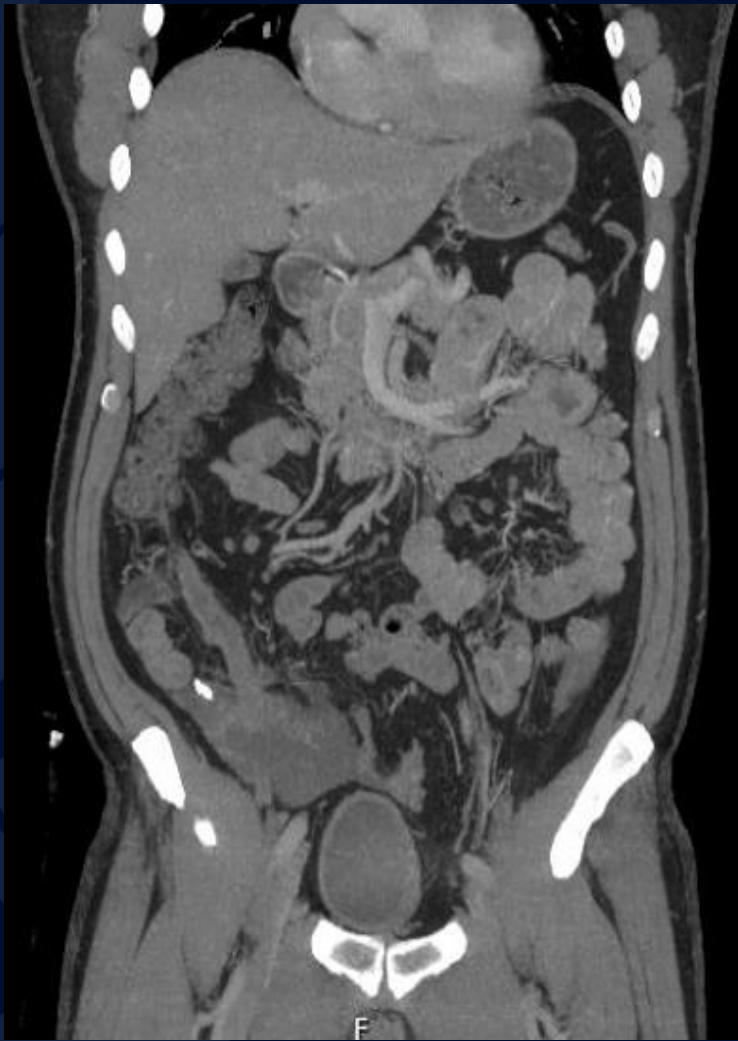58-year-old male presenting for possible kidney donation

Owen Karsmarski, MS3

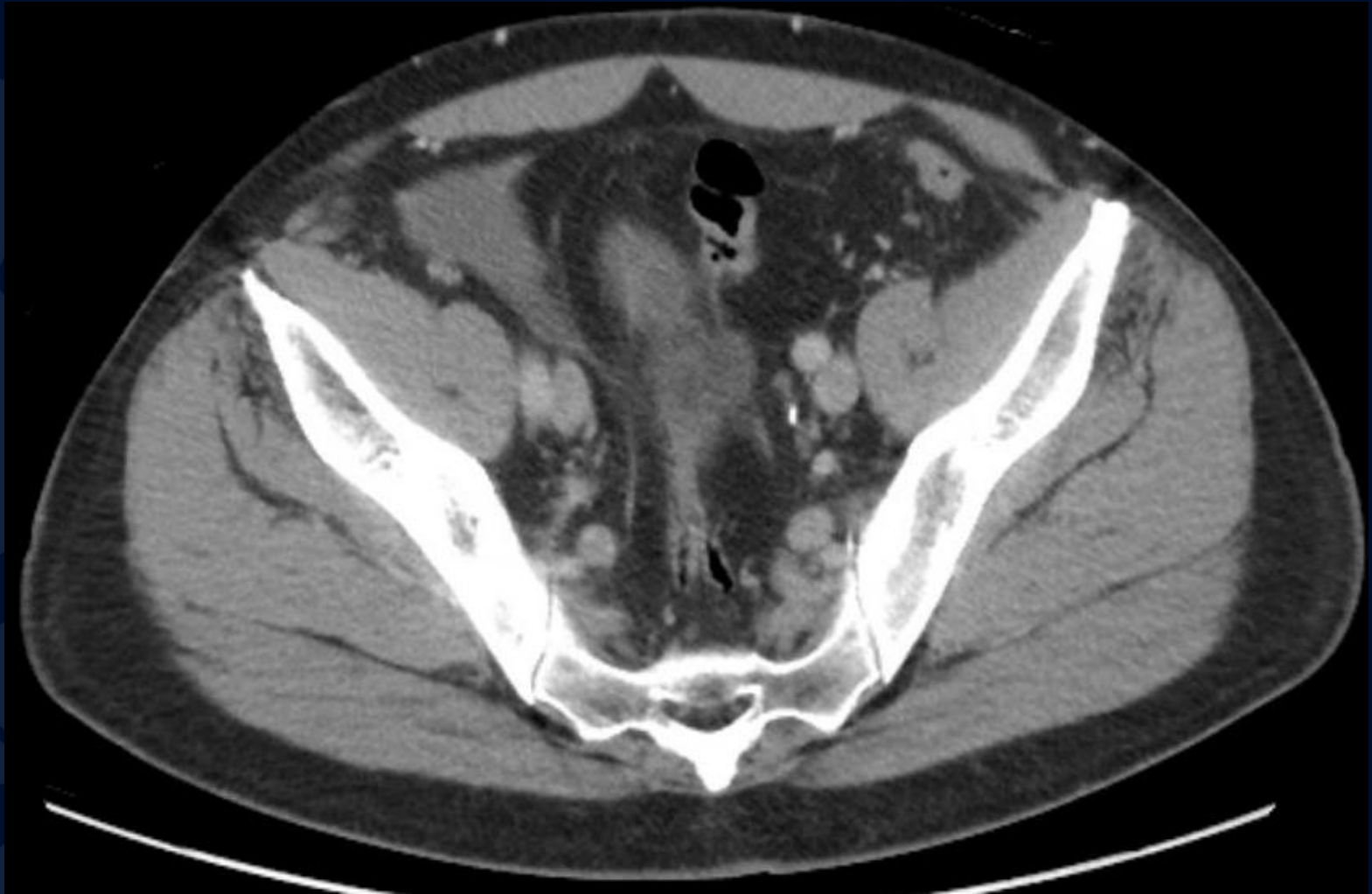CTA



MIPS CTA



CT

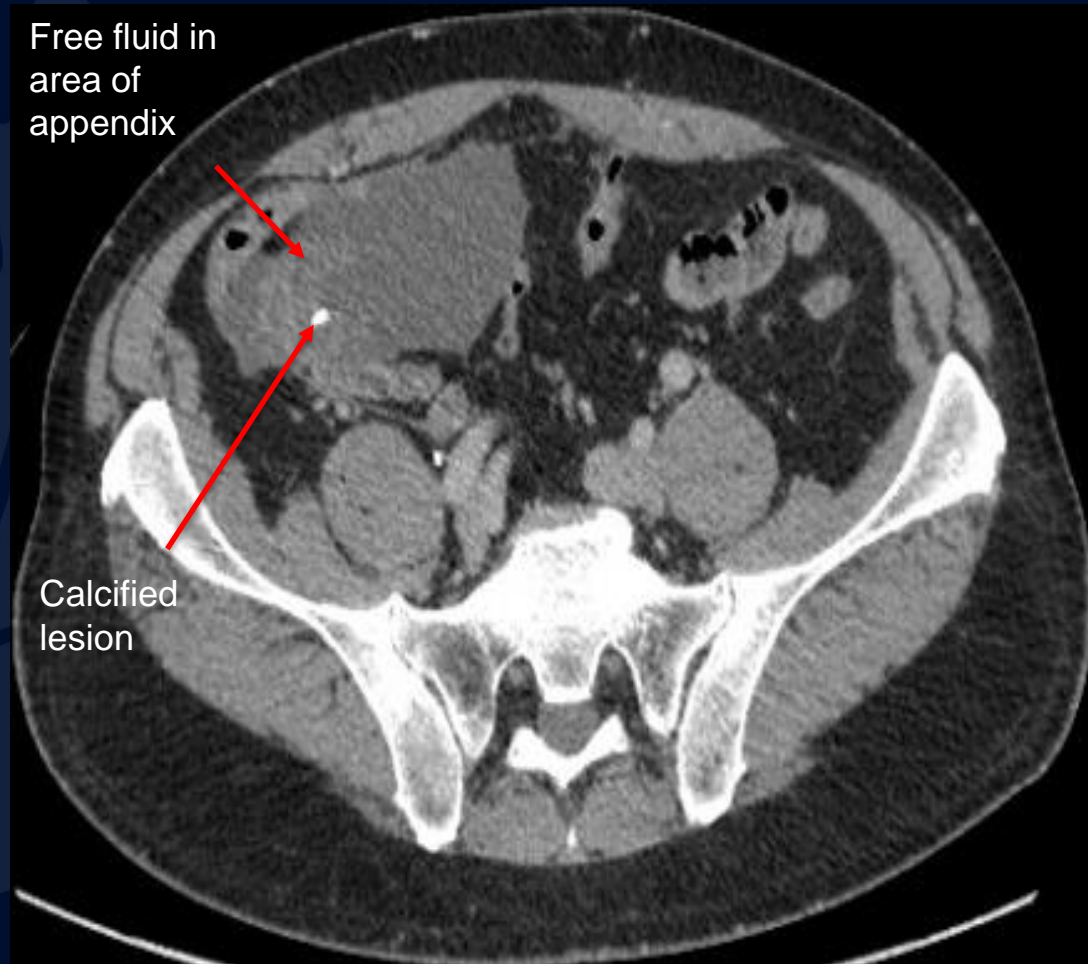


A large, stylized oak leaf graphic in a dark blue color, positioned on the left side of the slide. The leaf has a prominent central vein and several smaller veins branching off it. The leaf's edge is serrated.

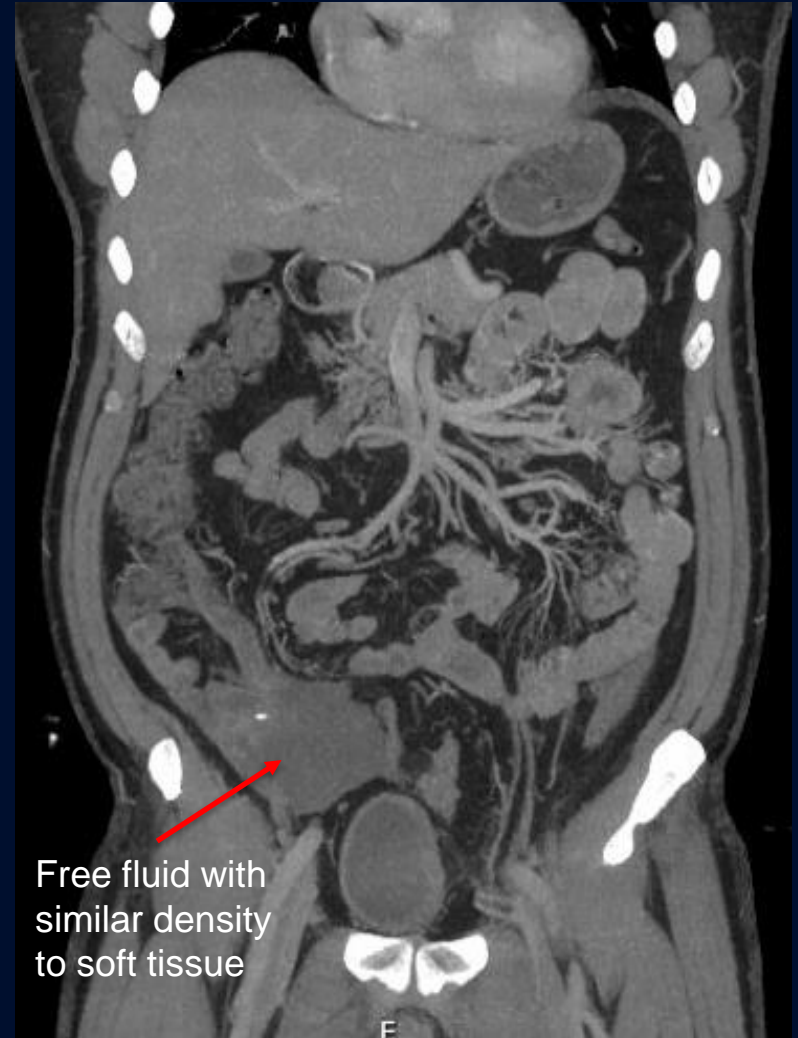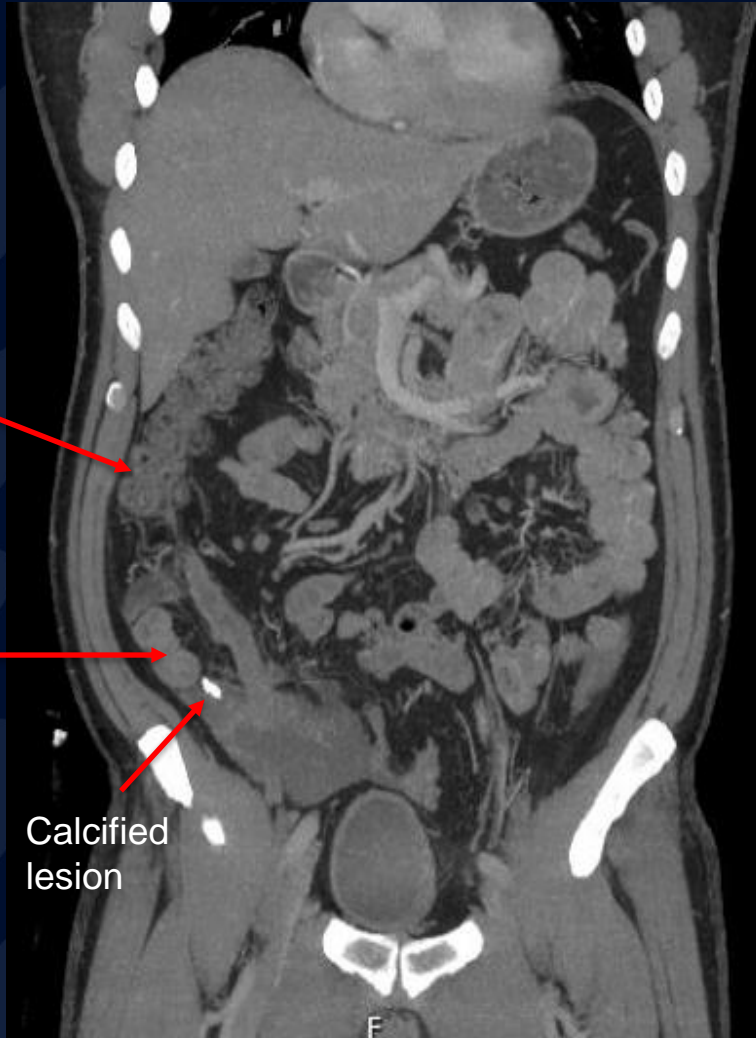?

Appendiceal Mucocele Neoplasm

CTA



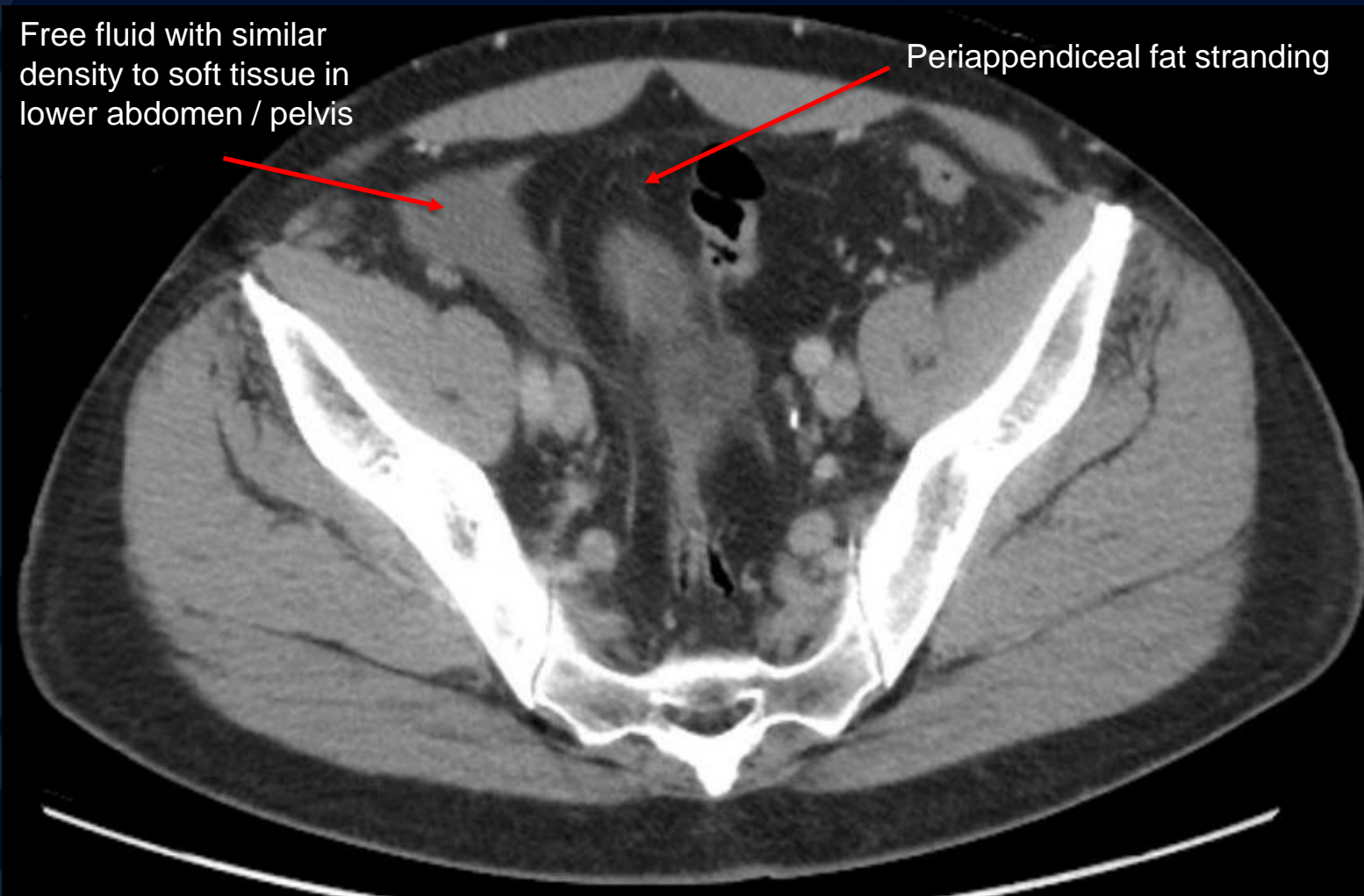
MIPS CTA



CT

Free fluid with similar density to soft tissue in lower abdomen / pelvis

Periappendiceal fat stranding



Abnormal fluid extending to level of bladder and pelvis with fat stranding

Appendiceal Mucocele Neoplasm

- Appendiceal mucoceles are a rare entity and can occur via non-neoplastic and neoplastic mechanisms
- **Pathophysiology:** Uncontrollable cell growth of epithelium of the appendix causing excessive mucous production causes dilation of the organ
- **Prognosis:**
 - Appendiceal mucocele neoplasms have varying prognosis based on extent of disease
 - Failure of early diagnosis can lead to organ rupture and pseudomyxoma peritonei which has a poor prognosis
- Often picked up incidentally on x-ray showing soft tissue mass or CT scan but can also present with vague abdominal pain and palpable right lower quadrant mass

Imaging Findings

- CT Scan of Abdomen
 - Often will have low-attenuated, encapsulated round or tubular cystic mass in right lower quadrant extending off the cecum
 - Wall calcifications may or may not be present
 - Dilated appendix
 - Periappendiceal fat stranding, calcifications, and dilation > 2 cm highly suspicious for neoplasm

References

- https://www-uptodate-com.online.uchc.edu/contents/appendiceal-mucinous-lesions?search=appendiceal%20mucinous%20neoplasm&source=search_result&selectedTitle=1~150&usage_type=default&display_rank=1#H3497214841
- Louis TH, Felter DF. Mucocele of the appendix. *Proc (Bayl Univ Med Cent)*. 2014 Jan;27(1):33-4. doi: 10.1080/08998280.2014.11929046. PMID: 24381400; PMCID: PMC3862129.
- Netter, FH. *Atlas of human anatomy*. Sixth edition. (2014). Philadelphia, PA, Saunders/Elsevier.
- Singh, Mahendra Pratap. A general overview of mucocele of appendix. *Journal of Family Medicine and Primary Care* 9(12):p 5867-5871, December 31, 2020. | DOI: 10.4103/jfmpc.jfmpc_1547_20
- Stocchi L, Wolff BG, Larson DR, Harrington JR. Surgical Treatment of Appendiceal Mucocele. *Arch Surg*. 2003;138(6):585–590. doi:10.1001/archsurg.138.6.585