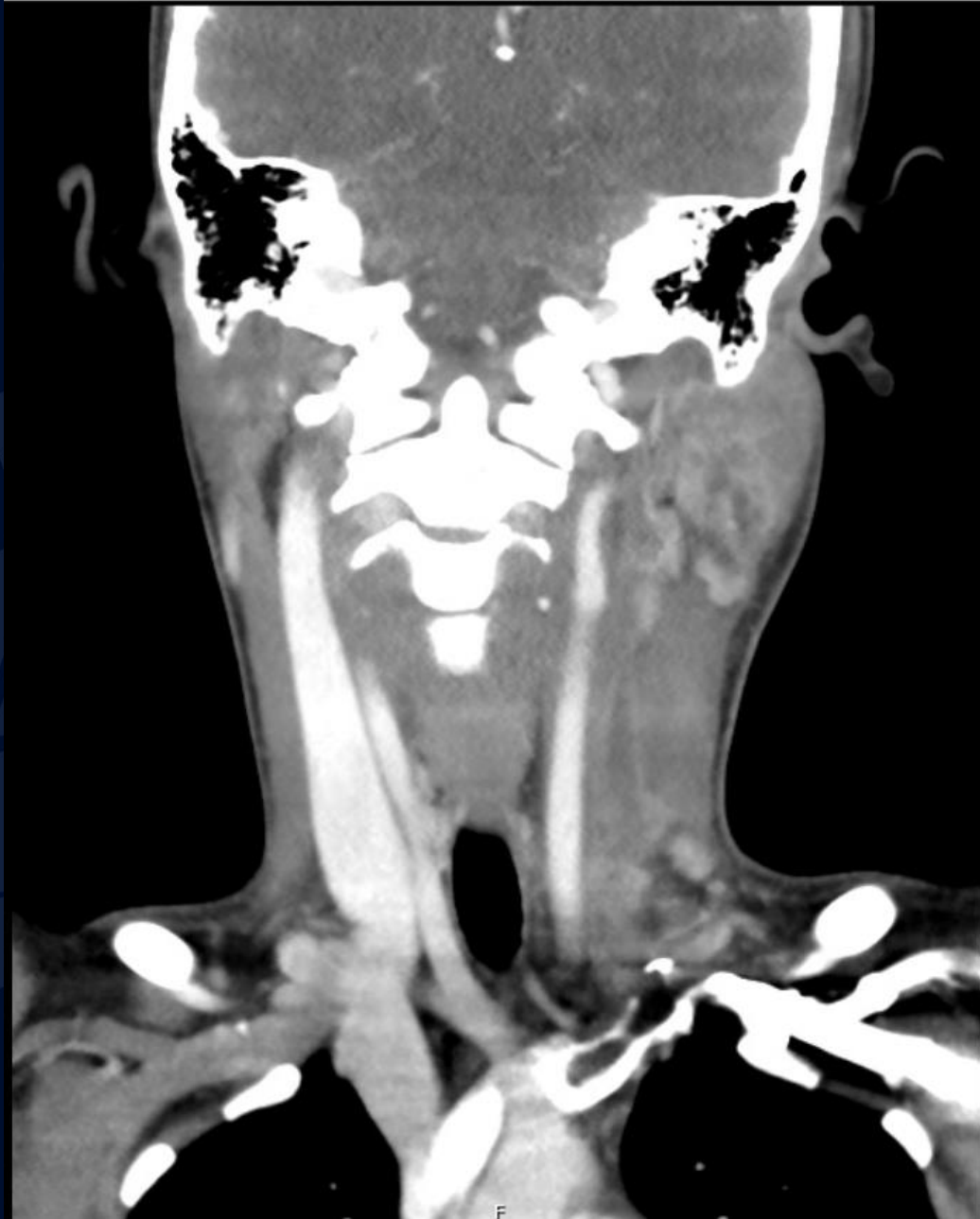

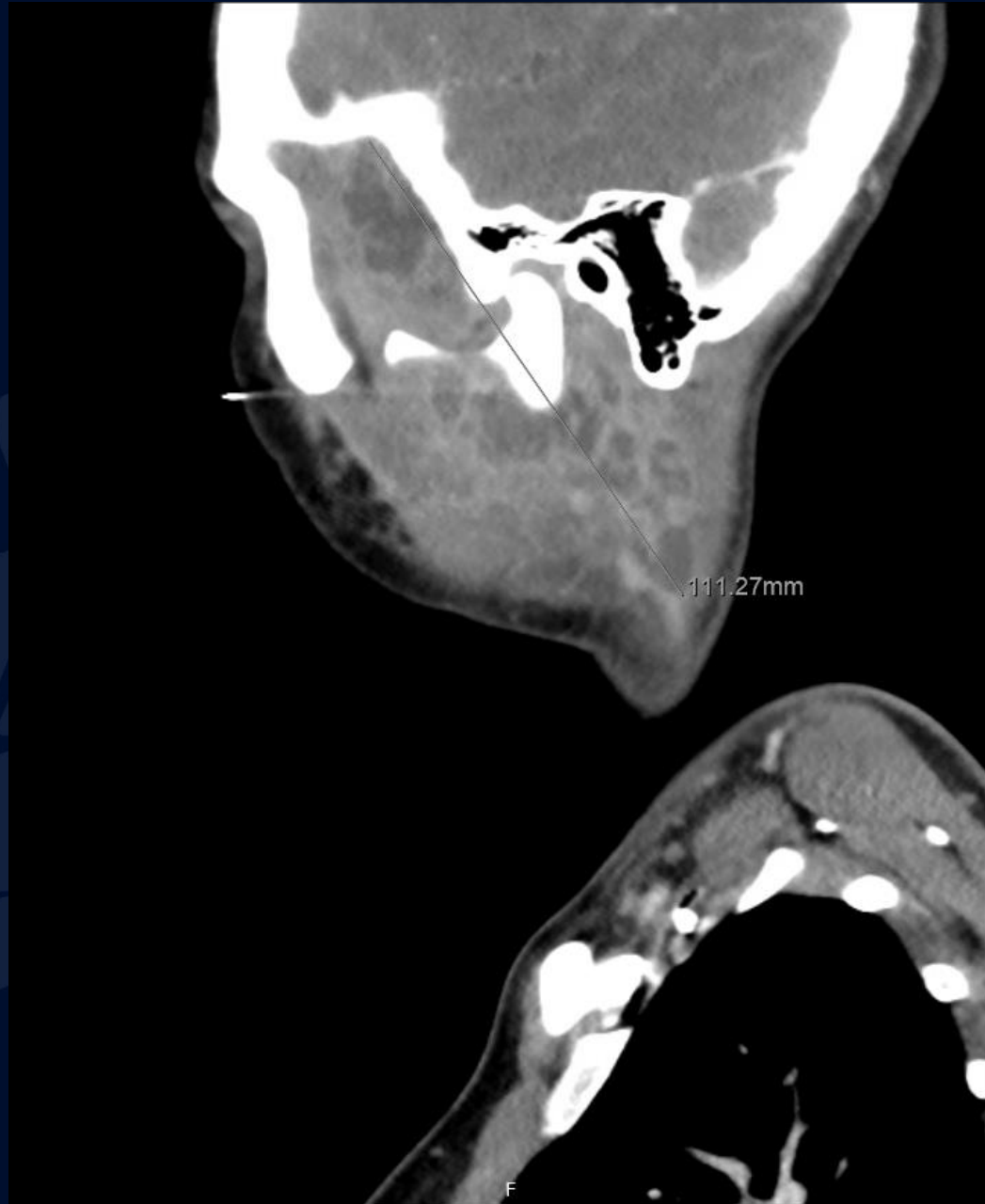
21-year-old female presents with
3 weeks of left-sided facial, ear
pain and neck swelling

Dean Kim, MS3

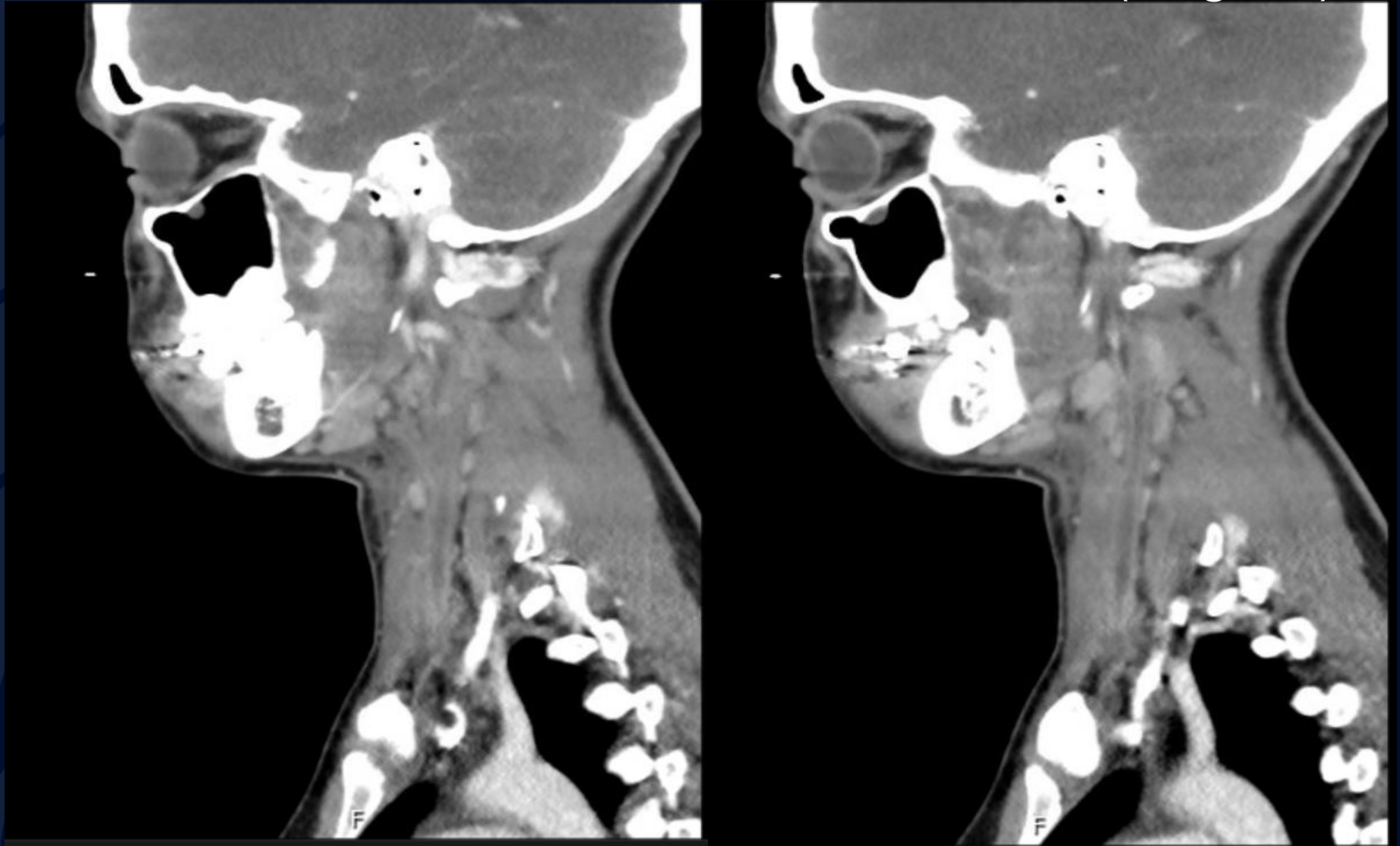
Contrast Enhanced CT Soft Tissue Neck



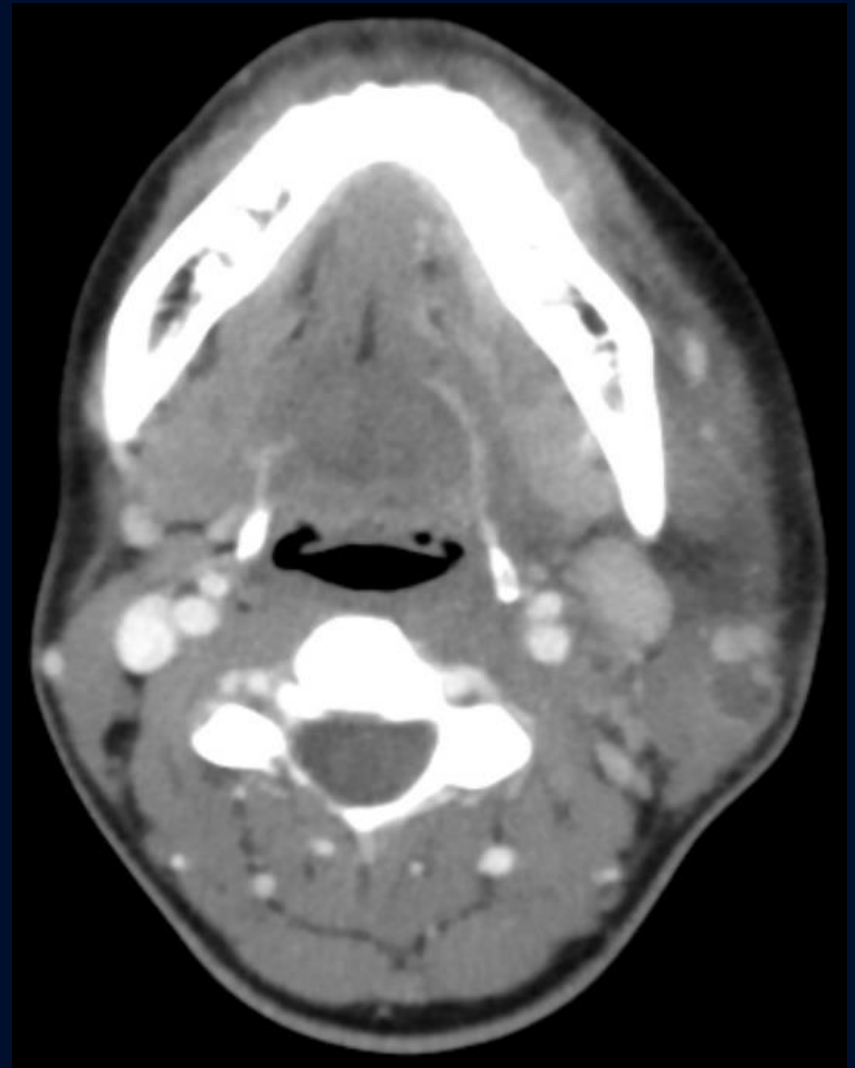
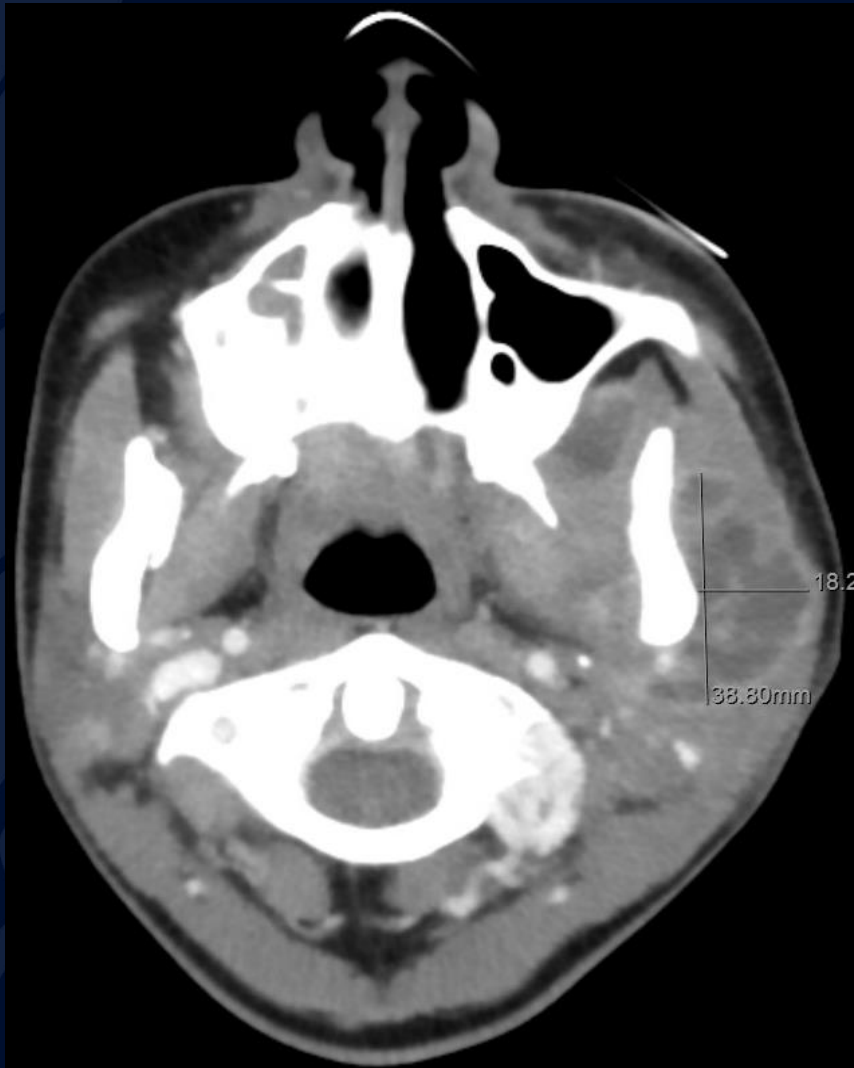Contrast Enhanced CT Soft Tissue Neck (Sagittal)



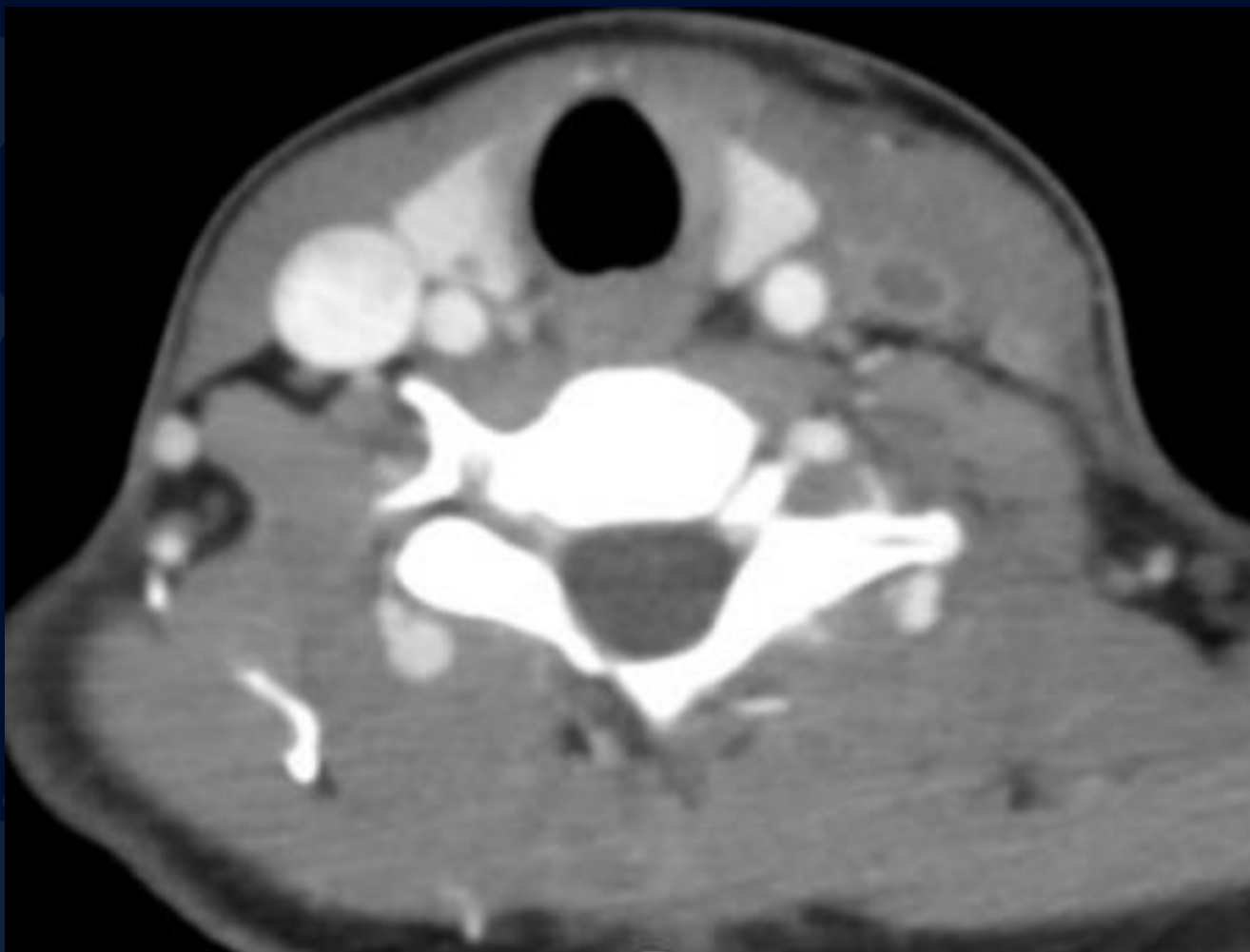Contrast Enhanced CT Soft Tissue Neck (Sagittal)



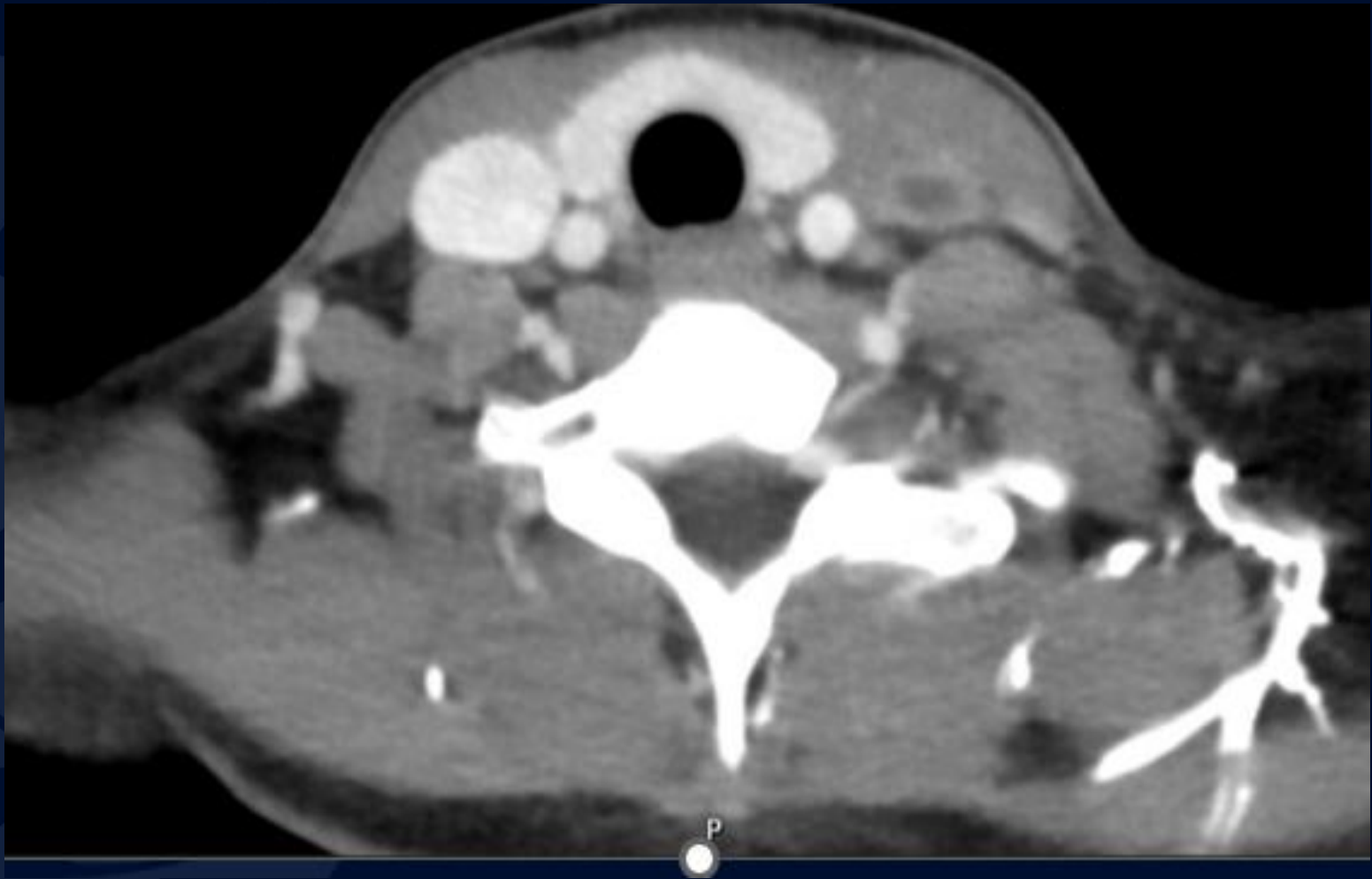Contrast Enhanced CT Soft Tissue Neck (Axial)



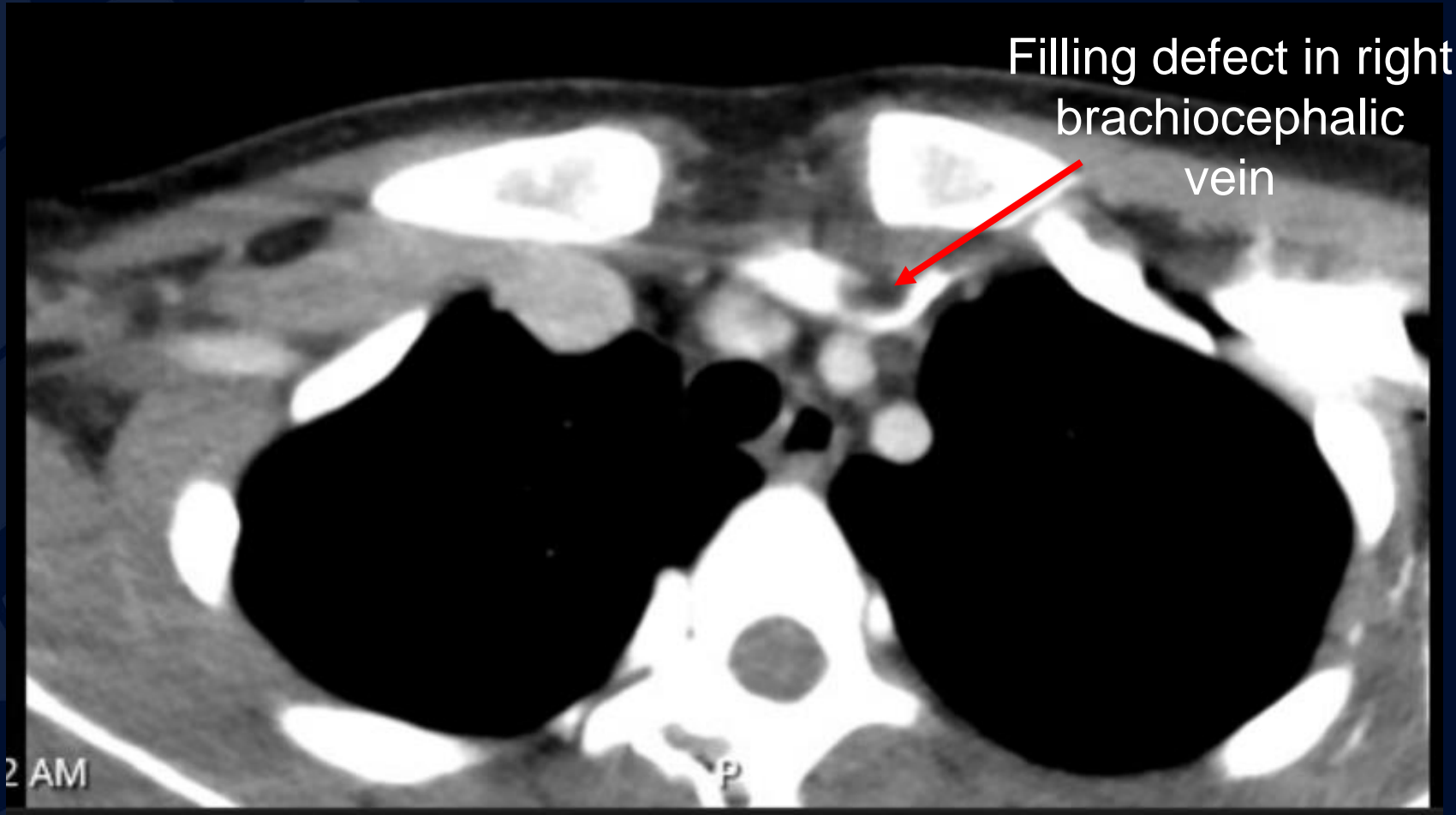
Contrast Enhanced CT Soft Tissue Neck (Axial)



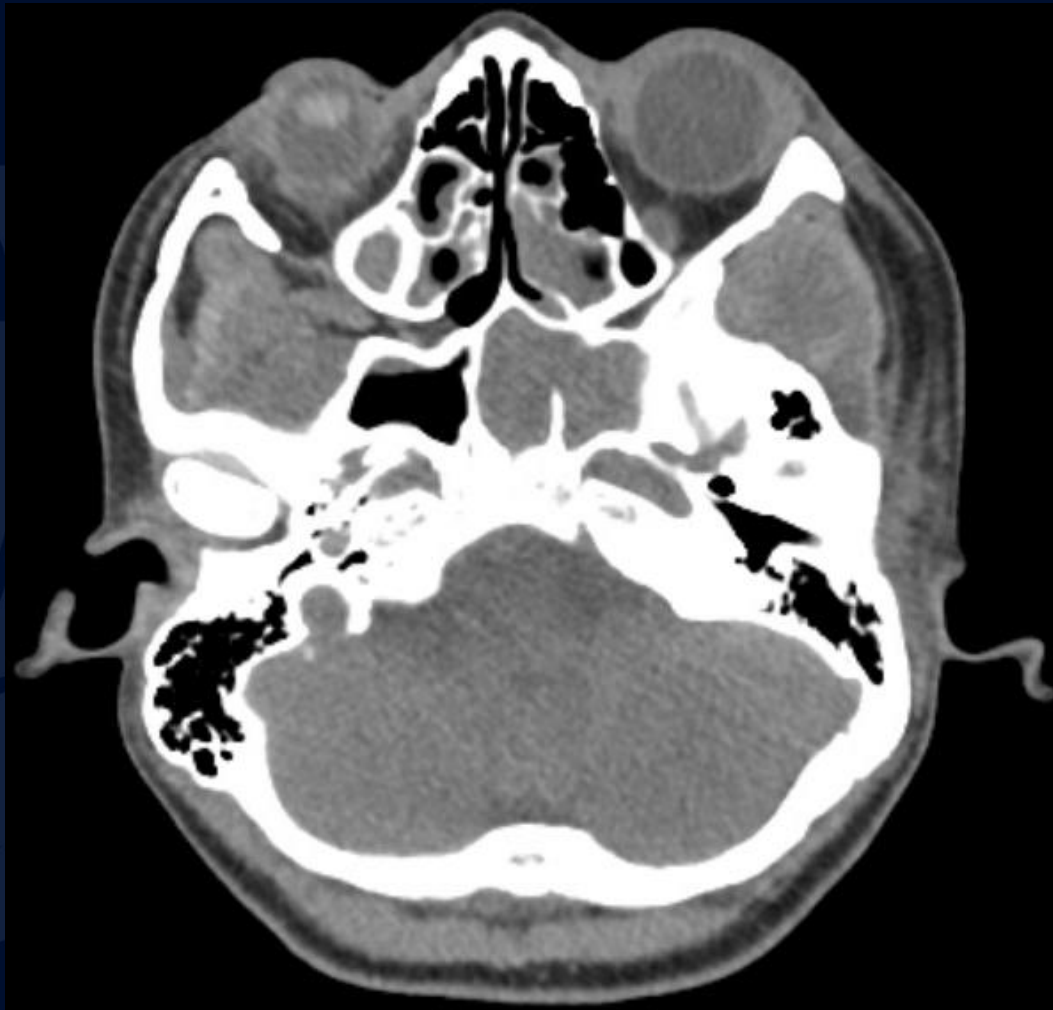
Contrast Enhanced CT Soft Tissue Neck (Axial)



Contrast Enhanced CT Soft Tissue Neck (Axial)



Non contrast CT Sinus (Axial)



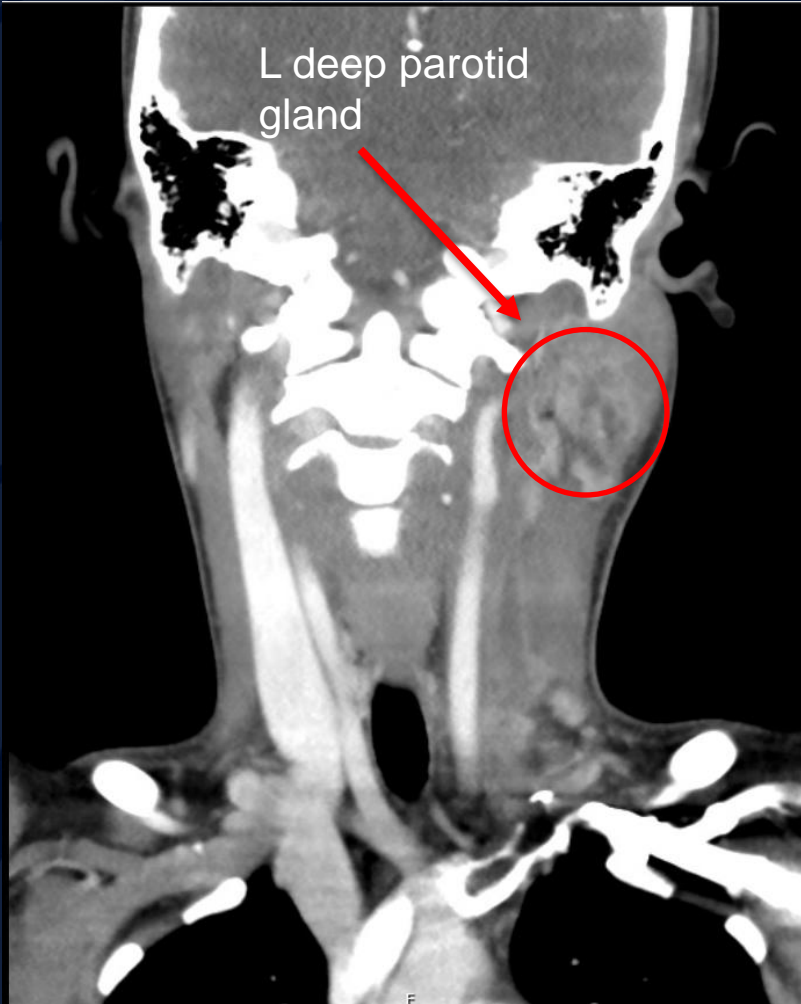
A large, stylized oak leaf graphic in a dark blue color, positioned on the left side of the slide. The leaf has a prominent central vein and several smaller veins branching off it. The leaf's edge is serrated.

?

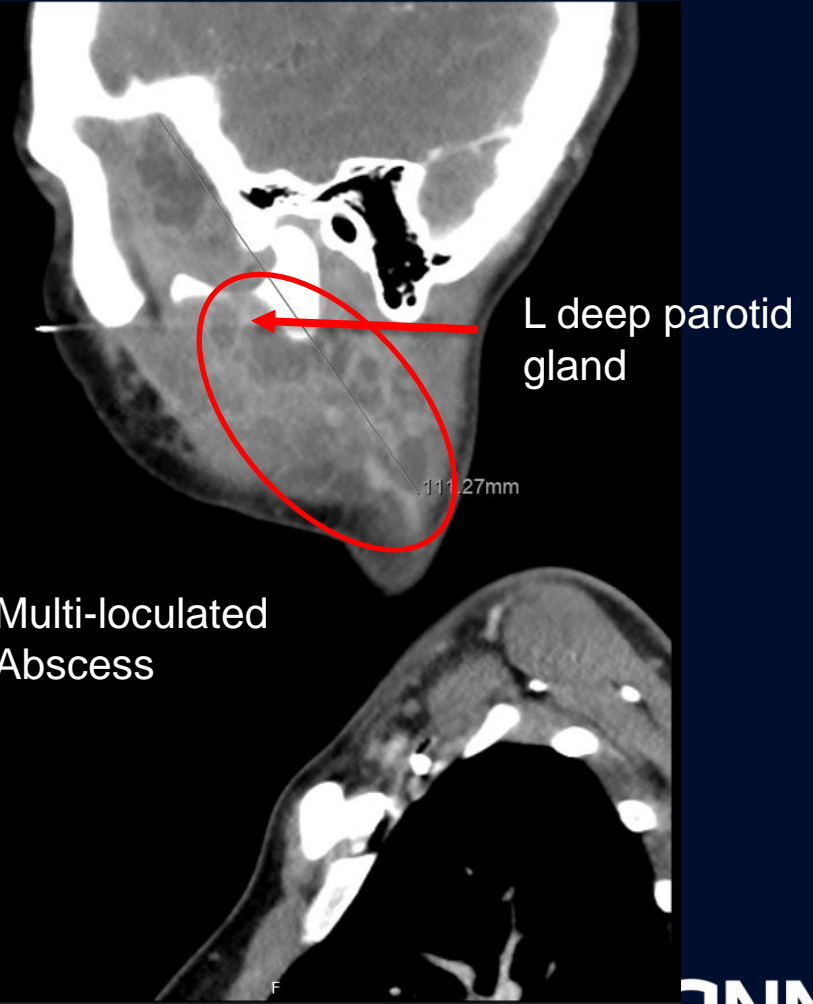
Lemierre Syndrome

Contrast Enhanced CT Soft Tissue Neck

Coronal

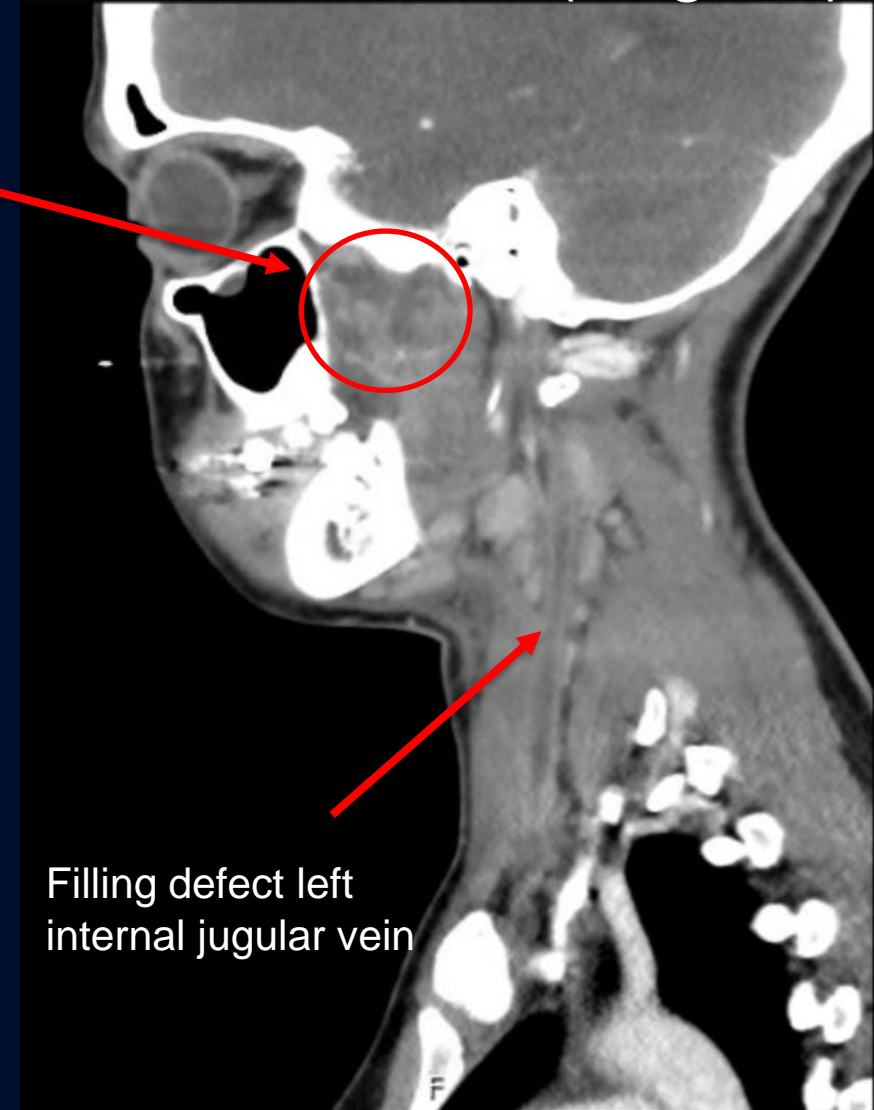
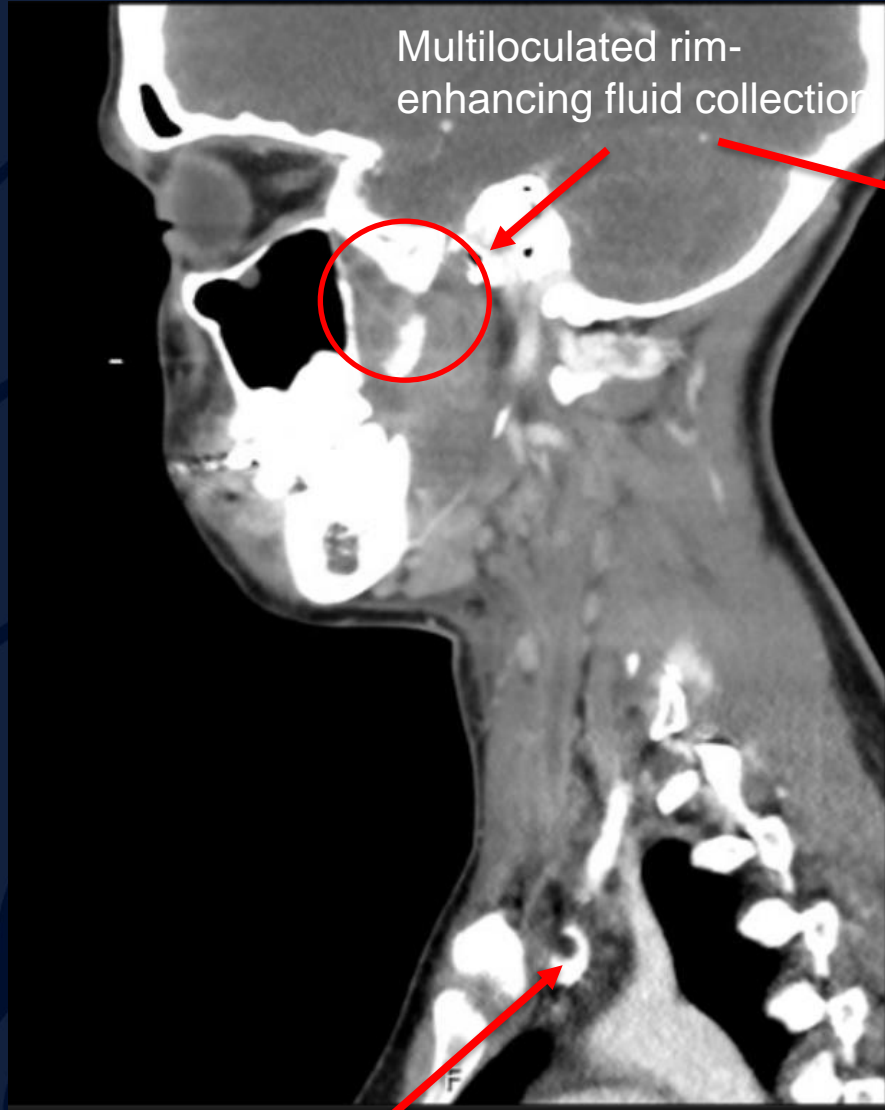


Sagittal

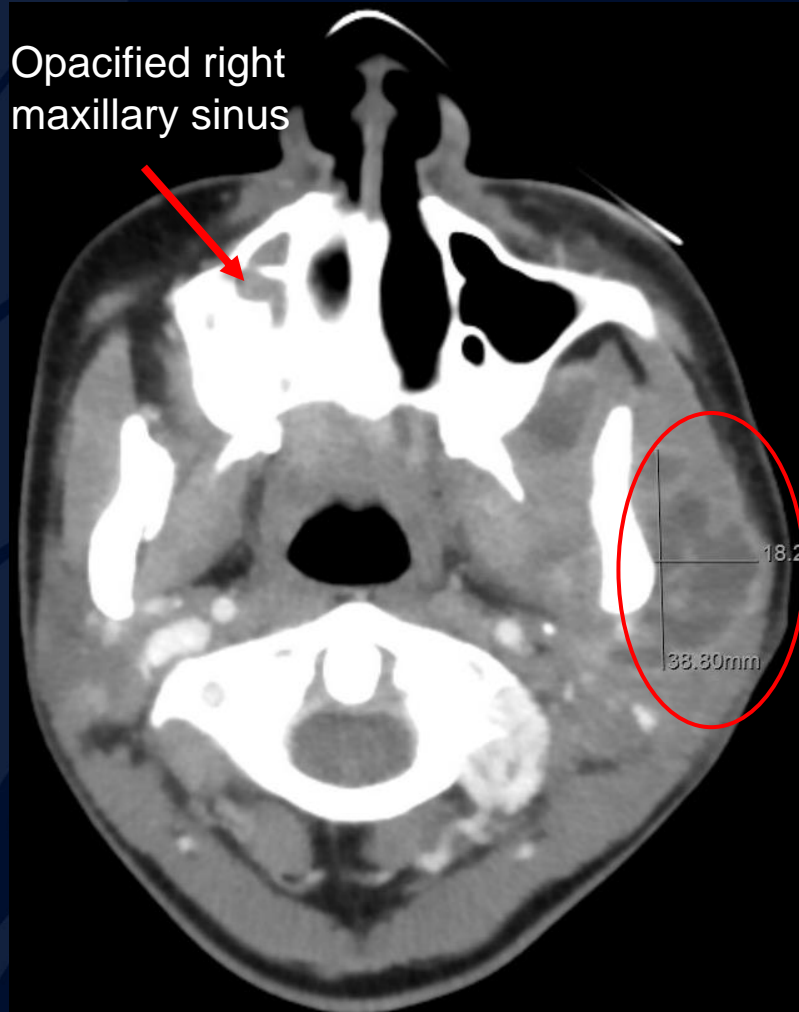


Multi-loculated Abscess involving left parotid space and sternocleidomastoid muscle

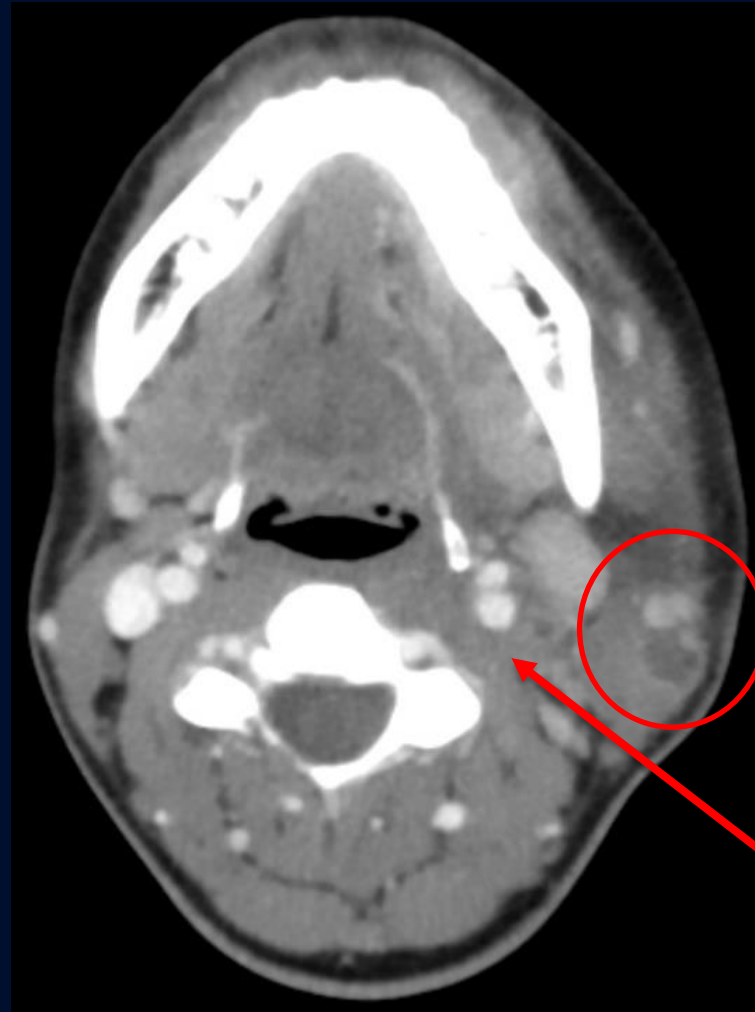Contrast Enhanced CT Soft Tissue Neck (Sagittal)



Contrast Enhanced CT Soft Tissue Neck (Axial)

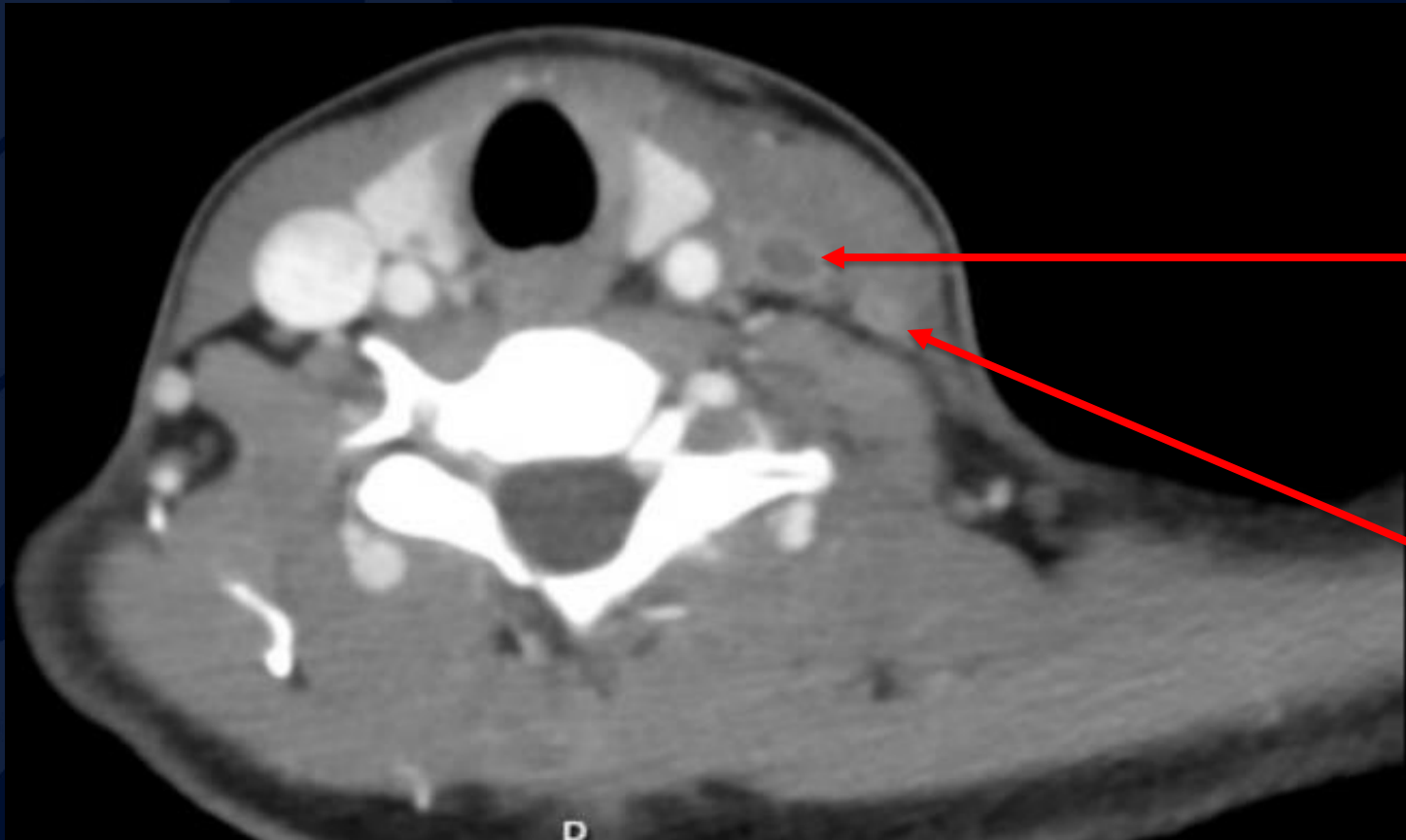


Multiloculated rim-enhancing fluid collection



Loculated Abscess

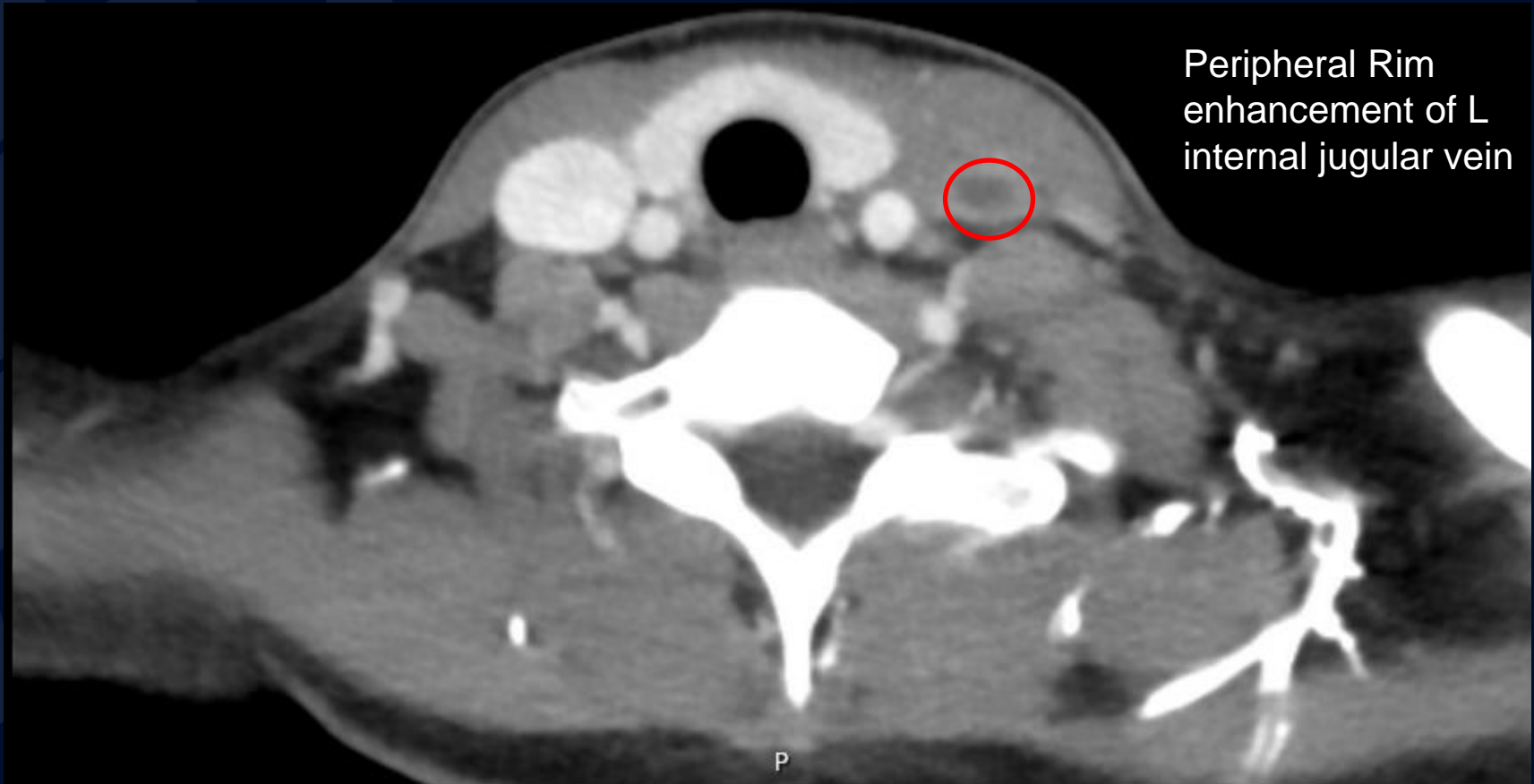
Contrast Enhanced CT Soft Tissue Neck (Axial)



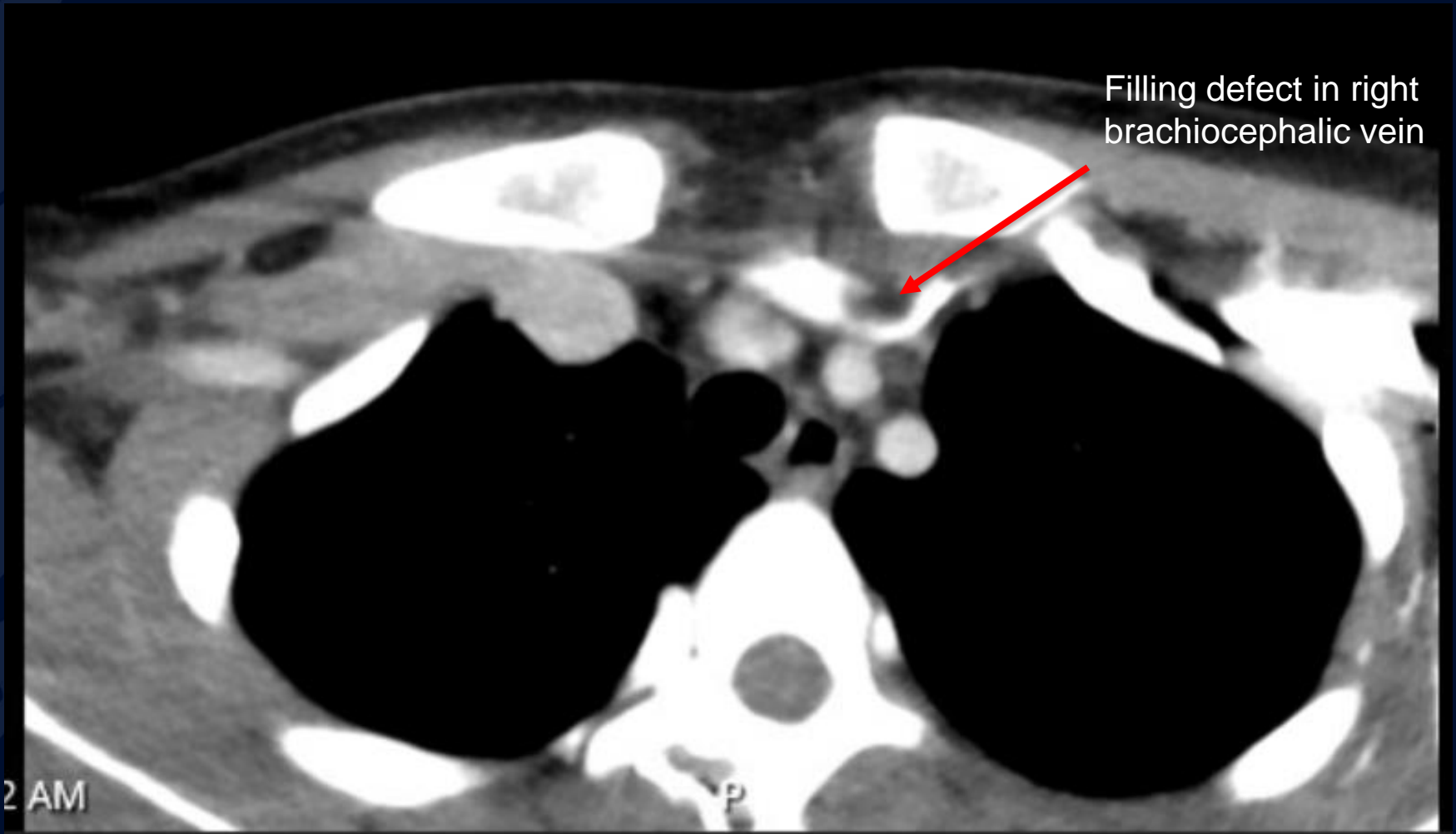
Low-density,
peripheral rim
enhancement of
left internal
jugular vein

Low-density,
peripheral rim
enhancement of
left external
jugular vein

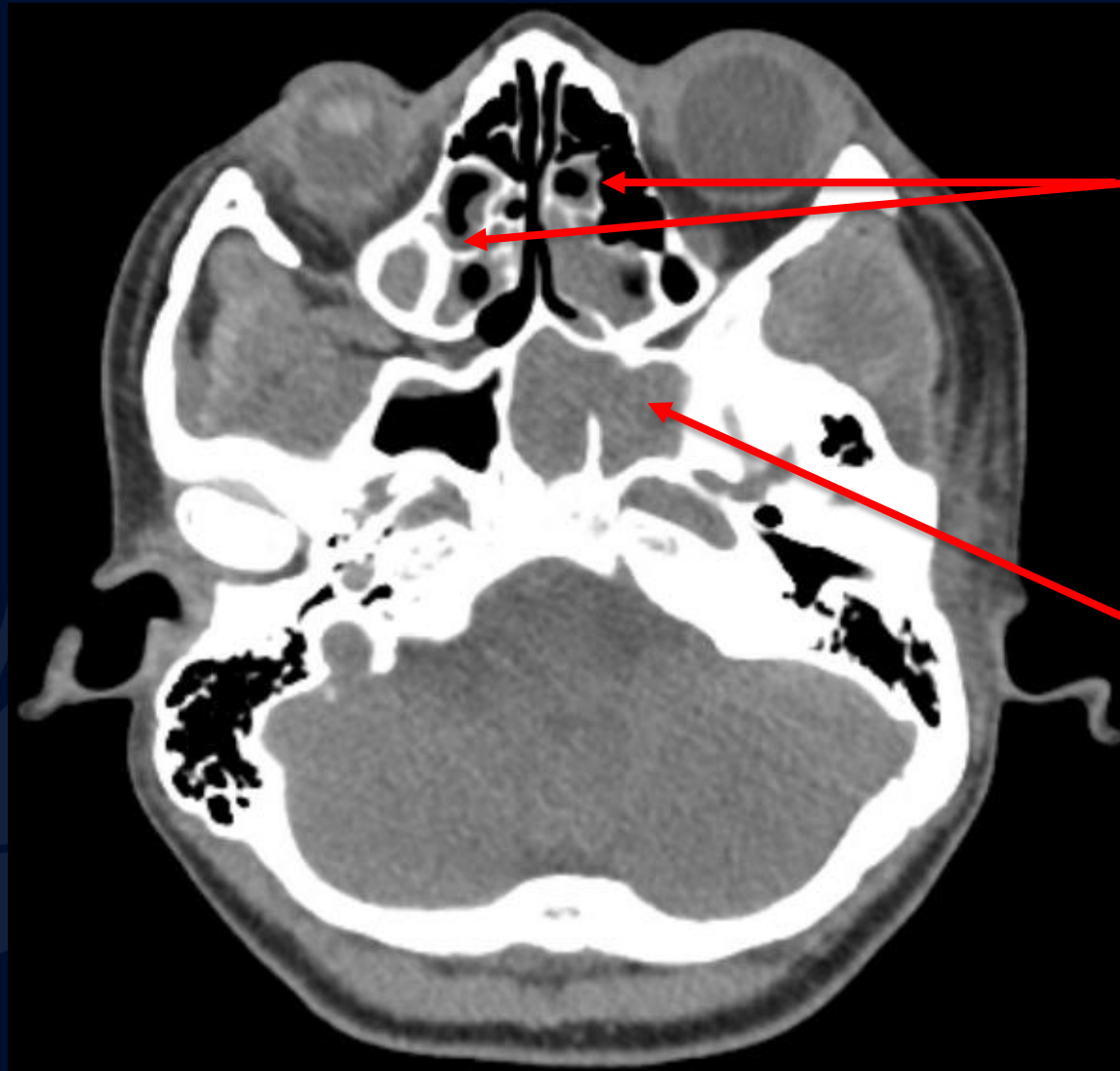
Contrast Enhanced CT Soft Tissue Neck (Axial)



Contrast Enhanced CT Soft Tissue Neck (Axial)



Non contrast CT Sinus (Axial)



Ethmoid air cell
mucosal
thickening

Complete
opacification of
left sphenoid
sinus

Lemierre Syndrome

- Lemierre Syndrome, otherwise known as septic thrombophlebitis of the internal jugular vein, is a rare disease (incidence 1/1000000) and is a rare complication of bacterial pharyngitis/tonsillitis
- Commonly caused by *F. necrophorum*
 - Gram-negative non-spore-forming obligate anaerobe
- Preferred Imaging for Diagnosis
 - CT scan with contrast of neck and chest
 - Classic finding of filling defect of IJV and complications such as abscesses and septic pulmonary emboli
 - MRI
 - Second-line study due to high cost and limited availability; can also demonstrate thrombus and emboli
- Treatment
 - Antibiotics (3–6-week course)
 - Anticoagulation (controversial efficacy)
 - Surgical drainage for parapharyngeal, cervical, or mediastinal abscesses
- Outcomes
 - Mortality rate of 6-22%

References

- Allen BW, Anjum F, Bentley TP. Lemierre Syndrome. [Updated 2022 Aug 1]. In: StatPearls [Internet]. Treasure Island (FL): StatPearls Publishing; 2023 Jan-. Available from: <https://www.ncbi.nlm.nih.gov/books/NBK499846/>
- Doan H, Niyazi S, Burton A, et al. Lemierre's Syndrome: A Case Report. *Cureus*. 2021;13(4). doi:10.7759/cureus.14713
- Harper LK, Pflug K, Raggio B, April D, Milburn JM. Clinical Images: Lemierre Syndrome: The Forgotten Disease? *Ochsner J*. 2016;16(1):7-9.
- Lemierre A. ON CERTAIN SEPTICÆMIAS DUE TO ANAEROBIC ORGANISMS. *The Lancet*. 1936;227(5874):701-703. doi:10.1016/S0140-6736(00)57035-4
- Lipe DN, Foris LA, King KC. Septic Thrombophlebitis. [Updated 2023 Feb 22]. In: StatPearls [Internet]. Treasure Island (FL): StatPearls Publishing; 2023 Jan-. Available from: <https://www.ncbi.nlm.nih.gov/books/NBK430731/>