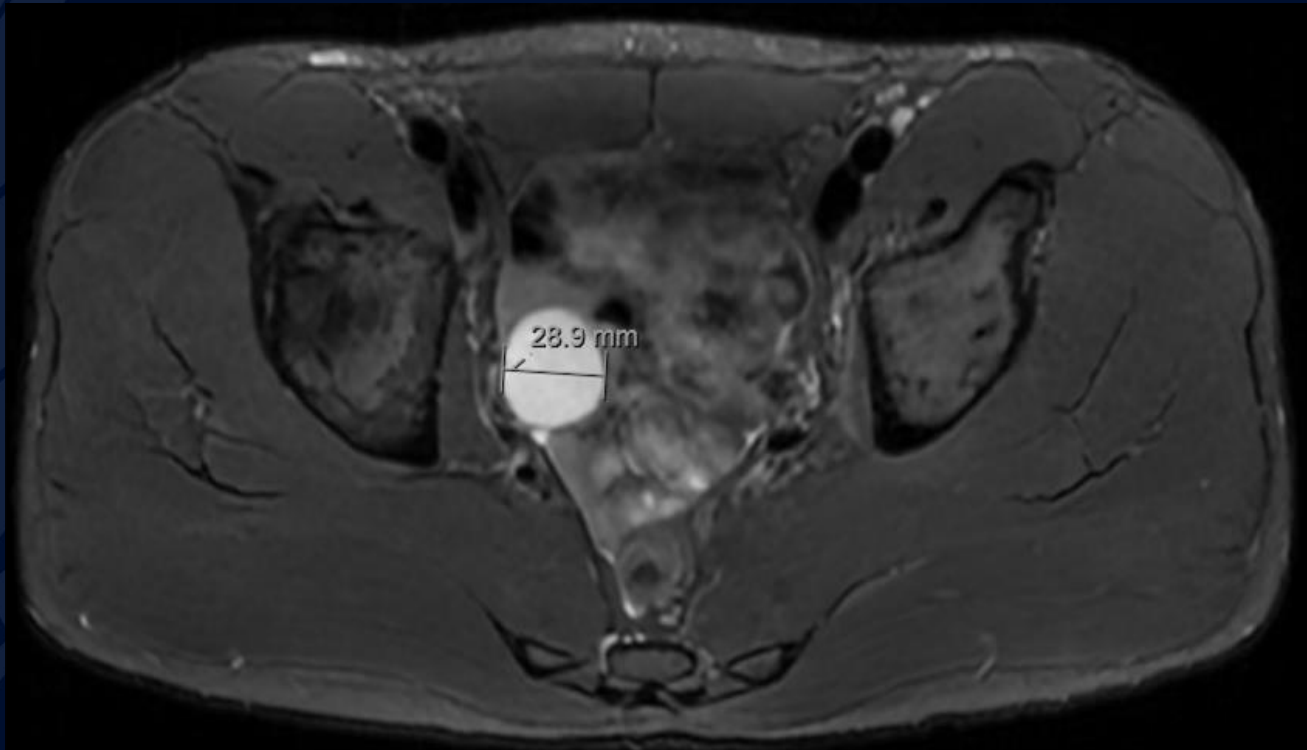


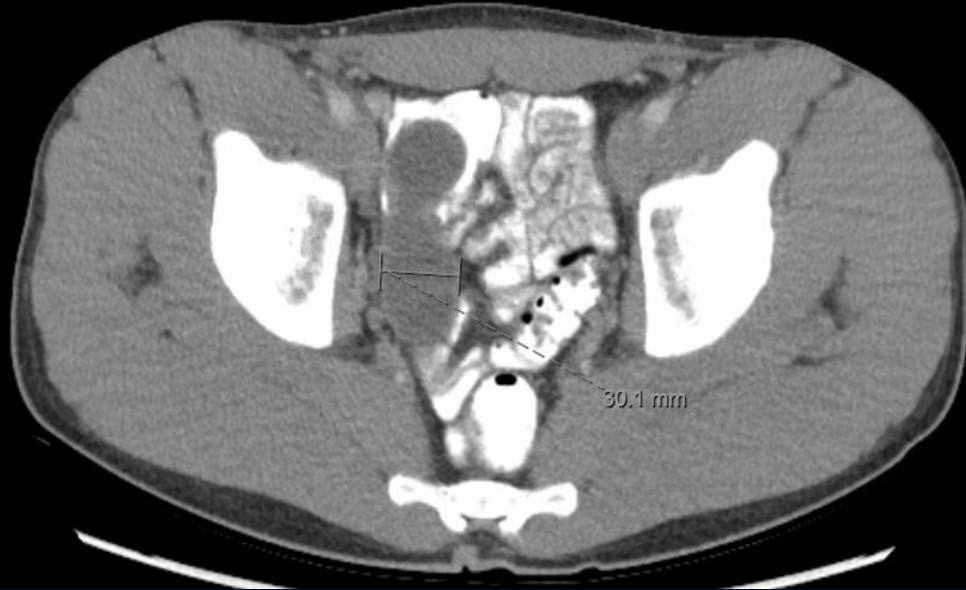
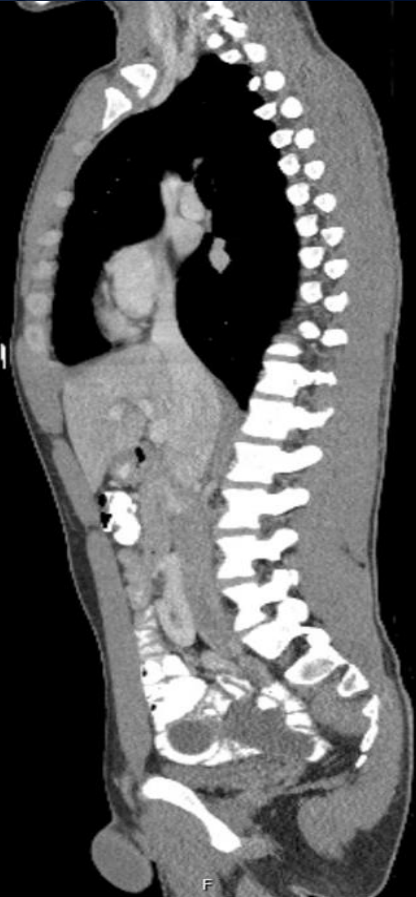22-year-old male with history of
inguinal hernia repair presenting
with chronic mild-to-moderate RLQ
pain

Will Martin, MS3

Non-contrast T2



CT Oral Contrast

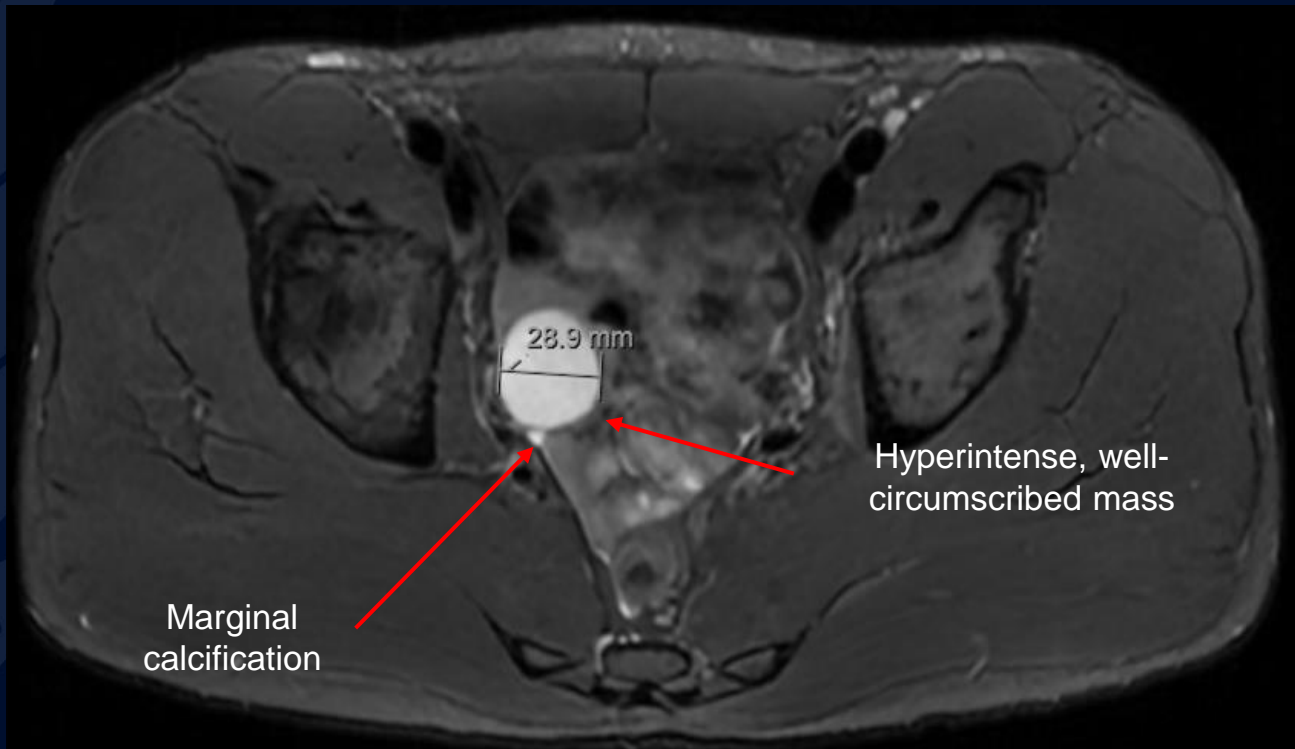




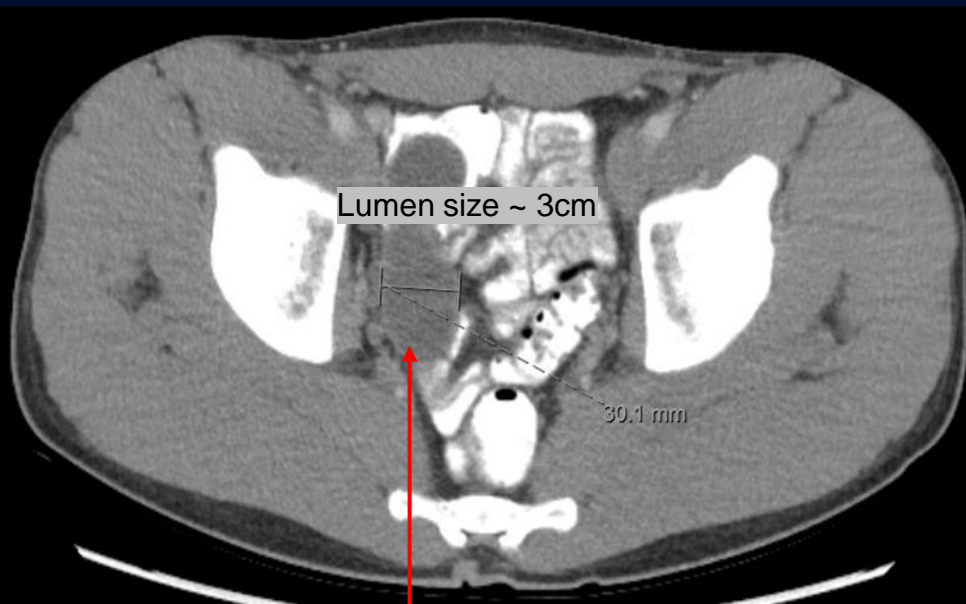
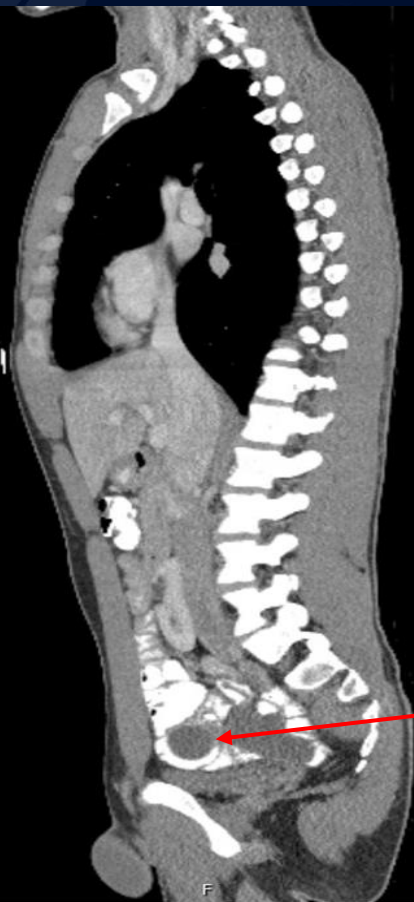?

Mucocele of Appendix

Non-contrast T2



CT Oral Contrast



Low attenuation tubular mass in patient's RLQ

No enhancement of mass with contrast

Mucocele of Appendix

- Dilation of appendix due to mucin build-up
- Usual cause is epithelial proliferation, but can be due to inflammation or obstruction of appendix
- Benign mucocele is a nonaggressive mucinous neoplasm spectrum vs more aggressive mucinous adenocarcinoma
- Presentation is not uniform and may be asymptomatic and discovered incidentally. Most common presenting chief complaint is RLQ pain which can be acute or chronic
- **Diagnosis:** CT with contrast is most specific method of diagnosis due to ability to detect hallmarks of mucocele in the appendix:
 - Lumen of >1.3 cm
 - Cystic dilatation
 - Wall calcification
- **Treatment:** Appendectomy/surgical resection with care not to spill mucinous contents into peritoneal cavity
 - Further resection of bowel is determined based on pathology of frozen section during the case. Right hemicolectomy can be warranted in severe circumstances when high-grade malignancy is found

References

- Demetrashvili Z, Chkhaidze M, Khutsishvili K, Topchishvili G, Javakhishvili T, Pipia I, Qerqadze V. Mucocele of the appendix: case report and review of literature. *Int Surg*. 2012 Jul-Sep;97(3):266-9. doi: 10.9738/CC139.1. PMID: 23113858; PMCID: PMC3723229.
- Louis TH, Felter DF. Mucocele of the appendix. *Proc (Bayl Univ Med Cent)*. 2014 Jan;27(1):33-4. doi: 10.1080/08998280.2014.11929046. PMID: 24381400; PMCID: PMC3862
- Persaud T, Swan N, Torreggiani WC. Giant mucinous cystadenoma of the appendix. *Radiographics*. 2007;27(2):553–557.129.
- Persaud T, Swan N, Torreggiani WC. Giant mucinous cystadenoma of the appendix. *Radiographics*. 2007;27(2):553–557.
- Dhage-Ivatury S, Sugarbaker PH. Update on the surgical approach to mucocele of the appendix. *J Am Coll Surg*. 2006;202(4):680–684.