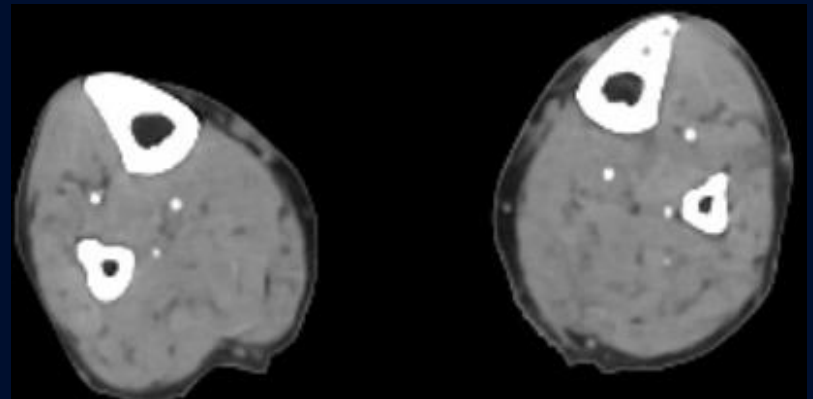
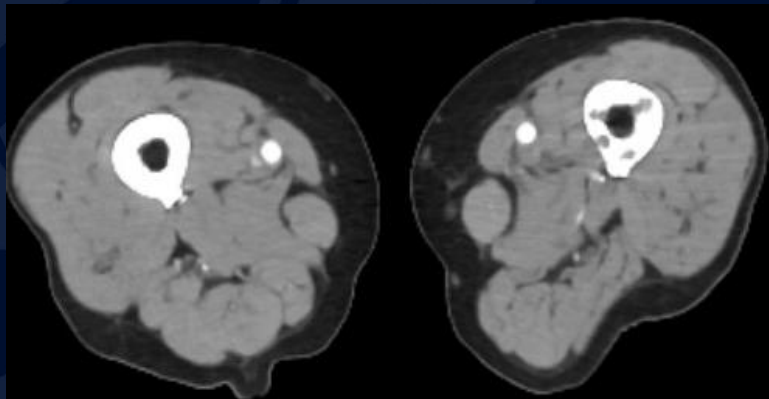
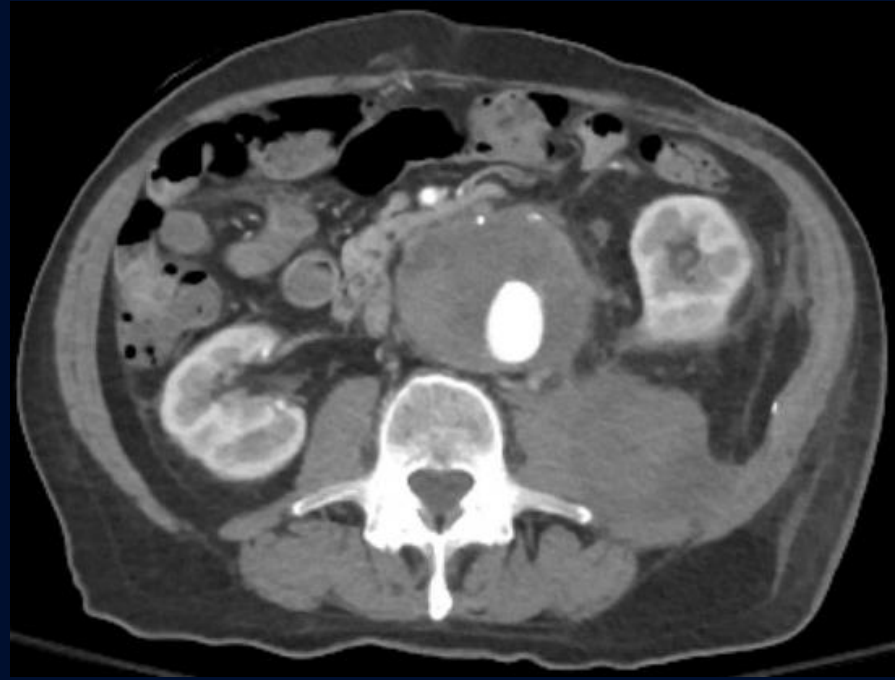
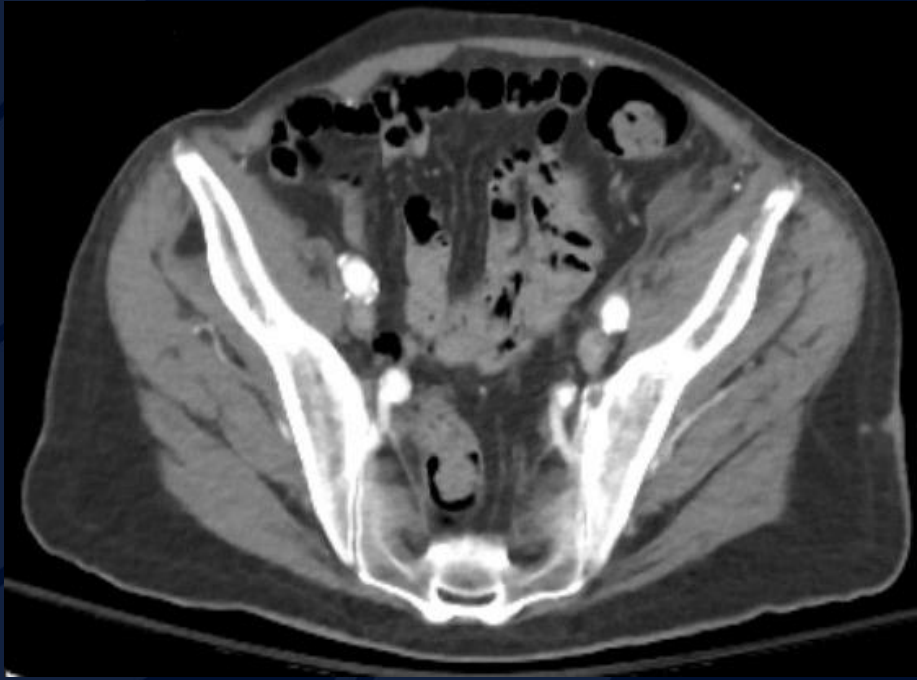
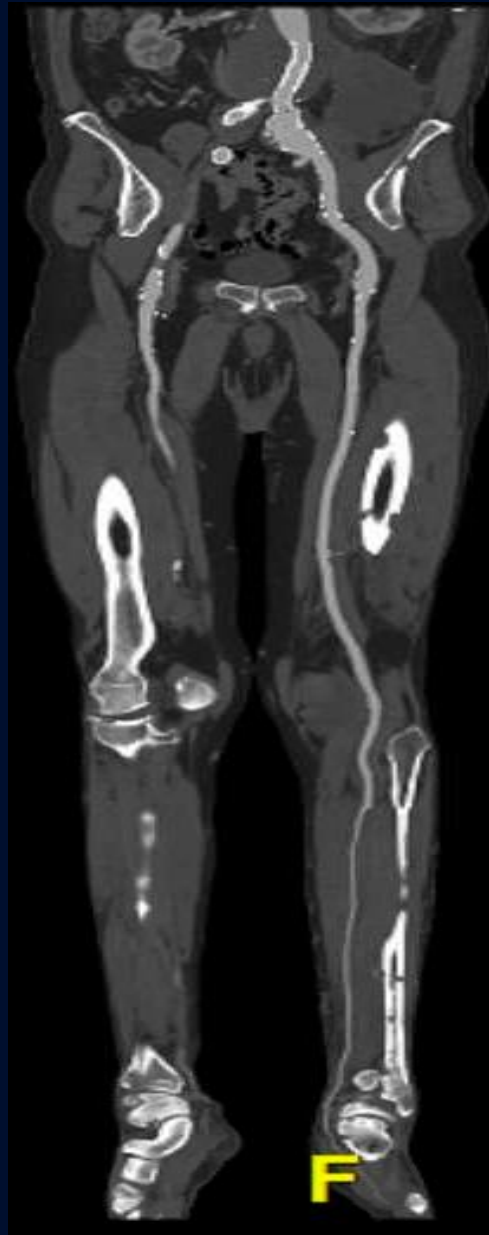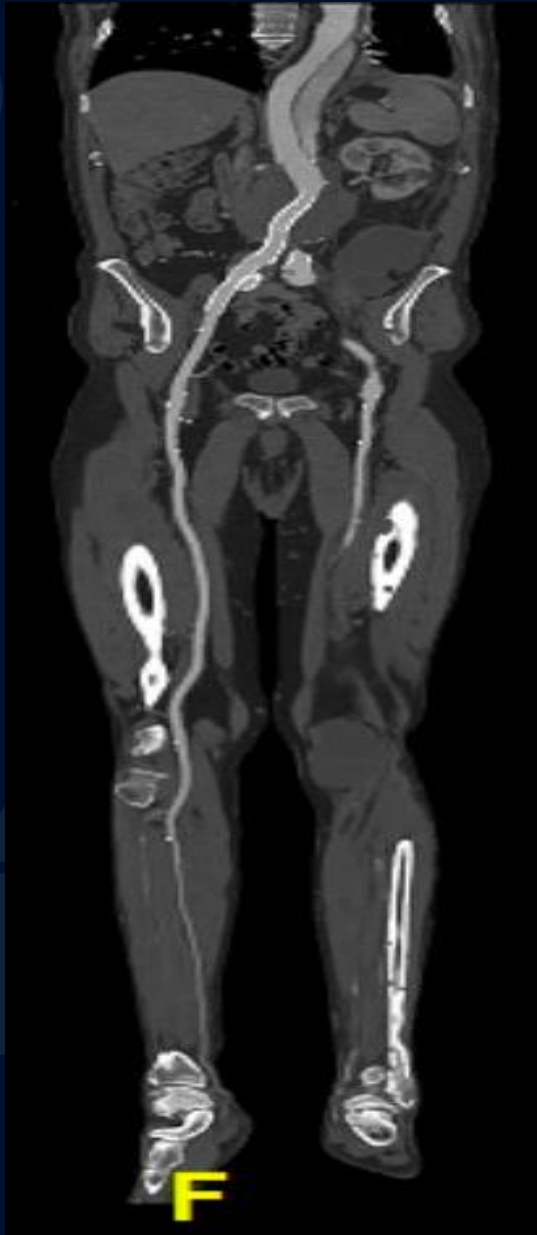70-year-old male with 5 days of left foot pain with gangrenous changes, muscle aches and altered mental status.

Patrick McMullan, MS3

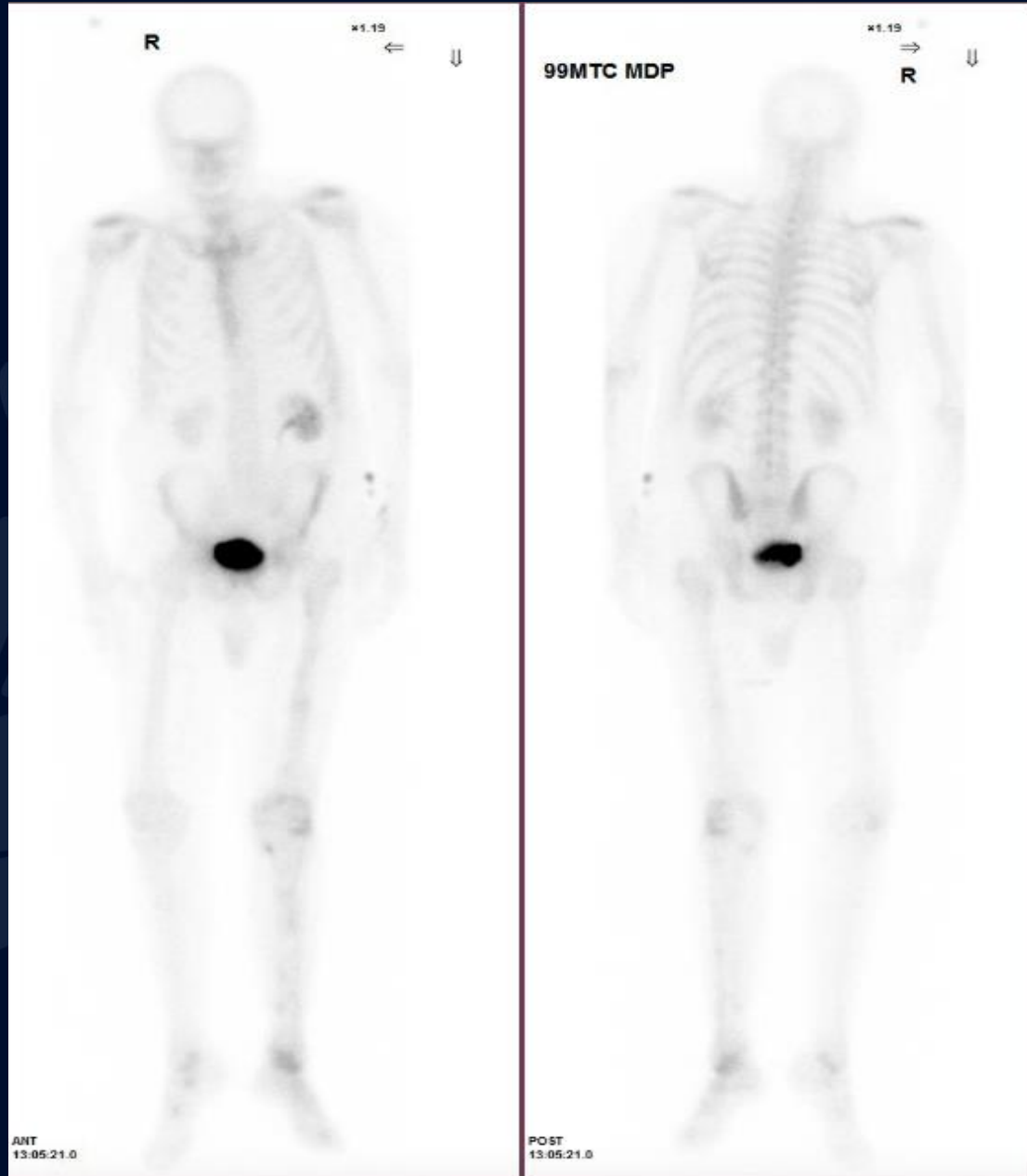CTA Bilateral Lower Extremities



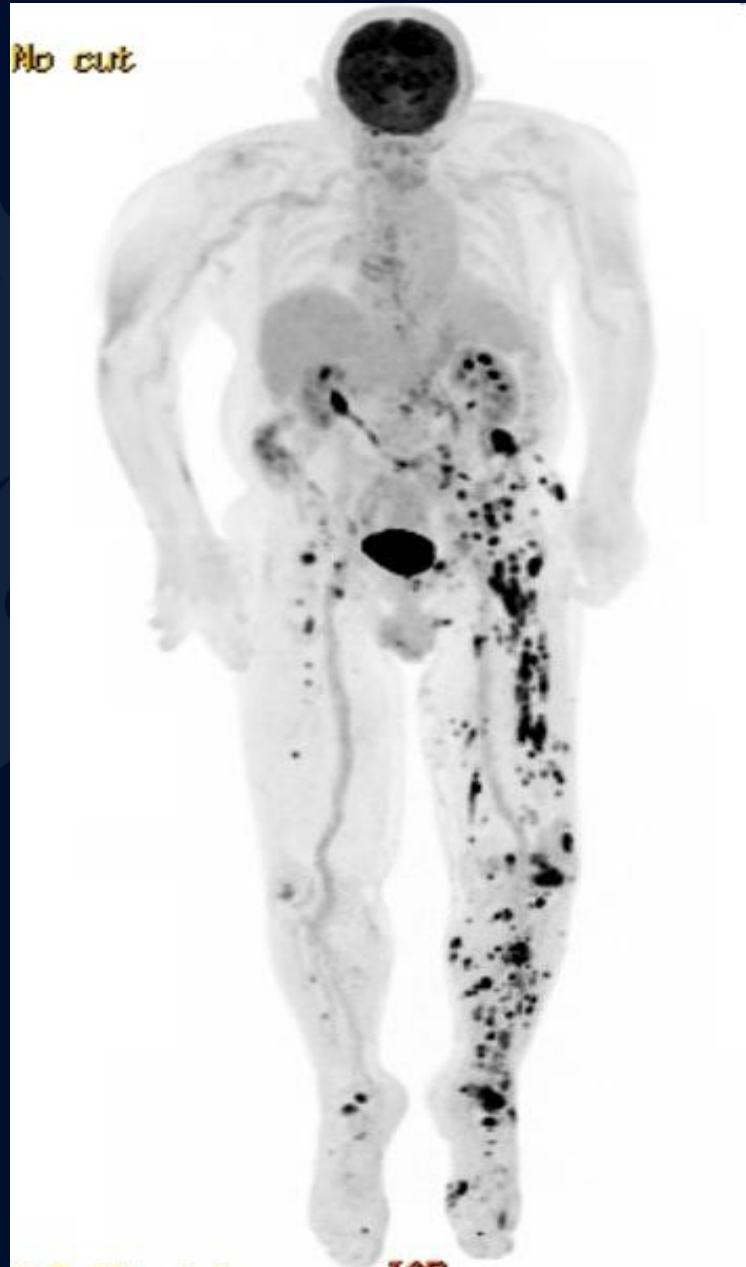
CTA Bilateral Lower Extremities



NM Bone Scan



Fluorine-18 FDG PET/CT Scan



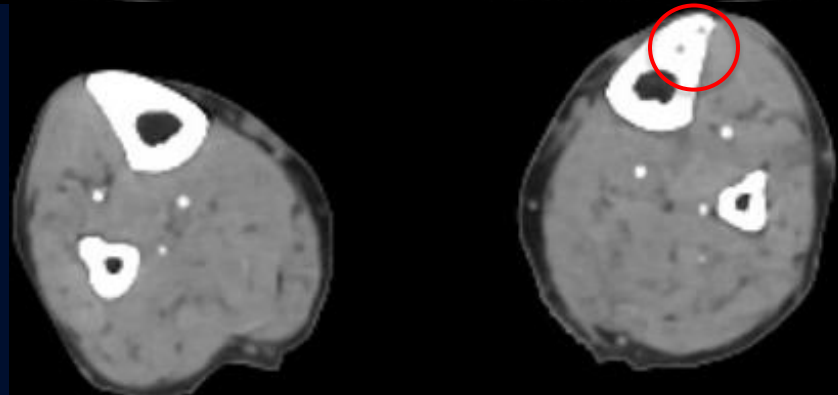
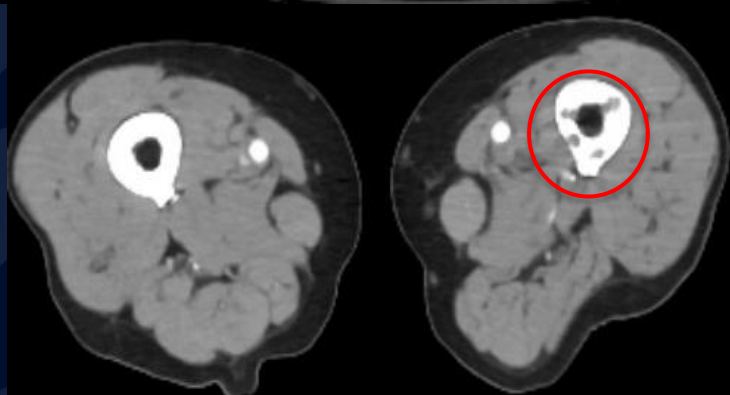
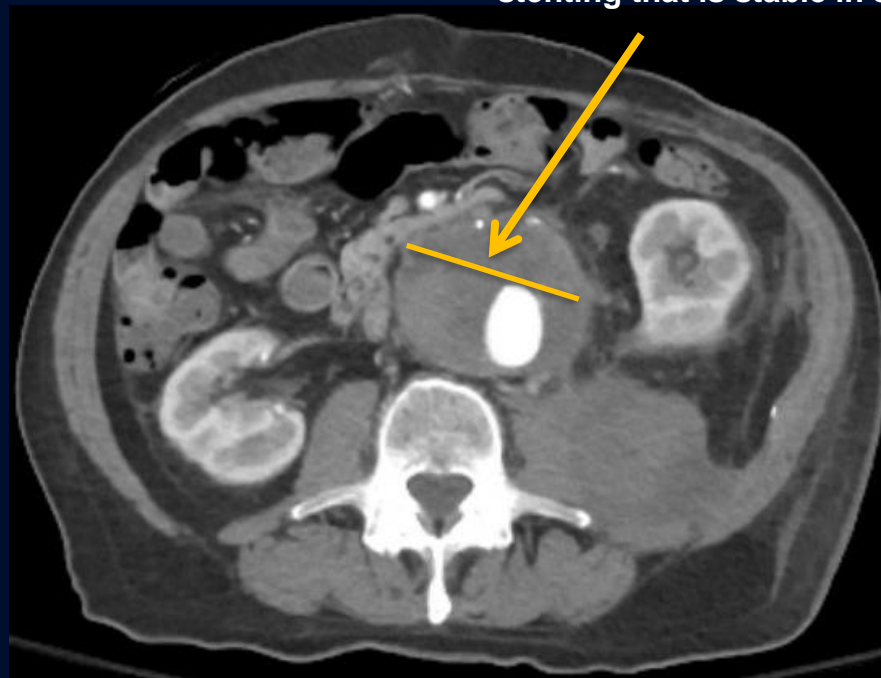
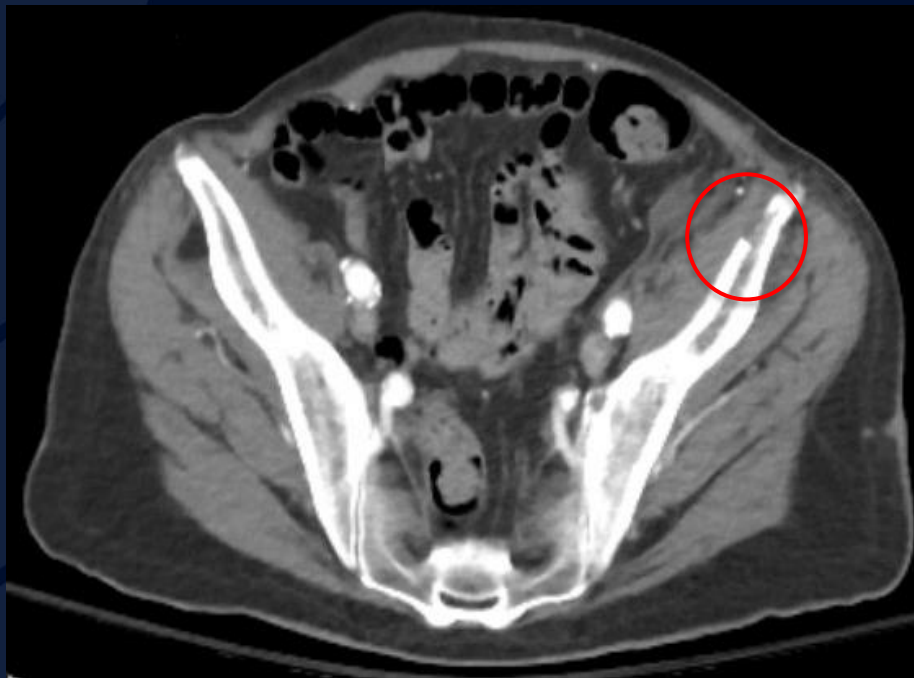

?

Metastatic Cutaneous Angiosarcoma

CTA Bilateral Lower Extremities

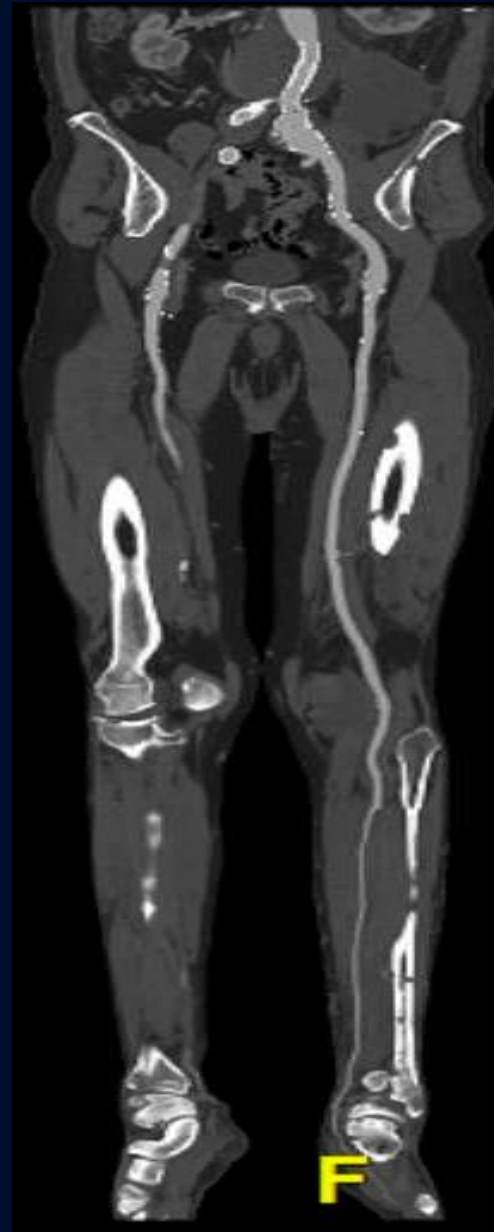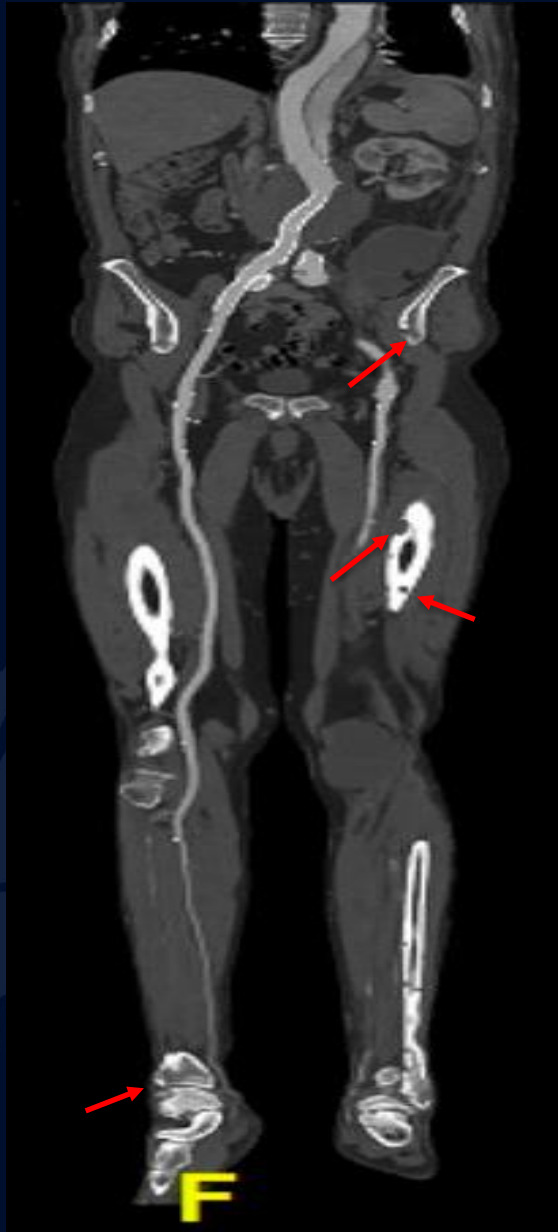Redemonstration of the known infrarenal abdominal aortic aneurysm status post stenting that is stable in size



Lytic Bone Lesions

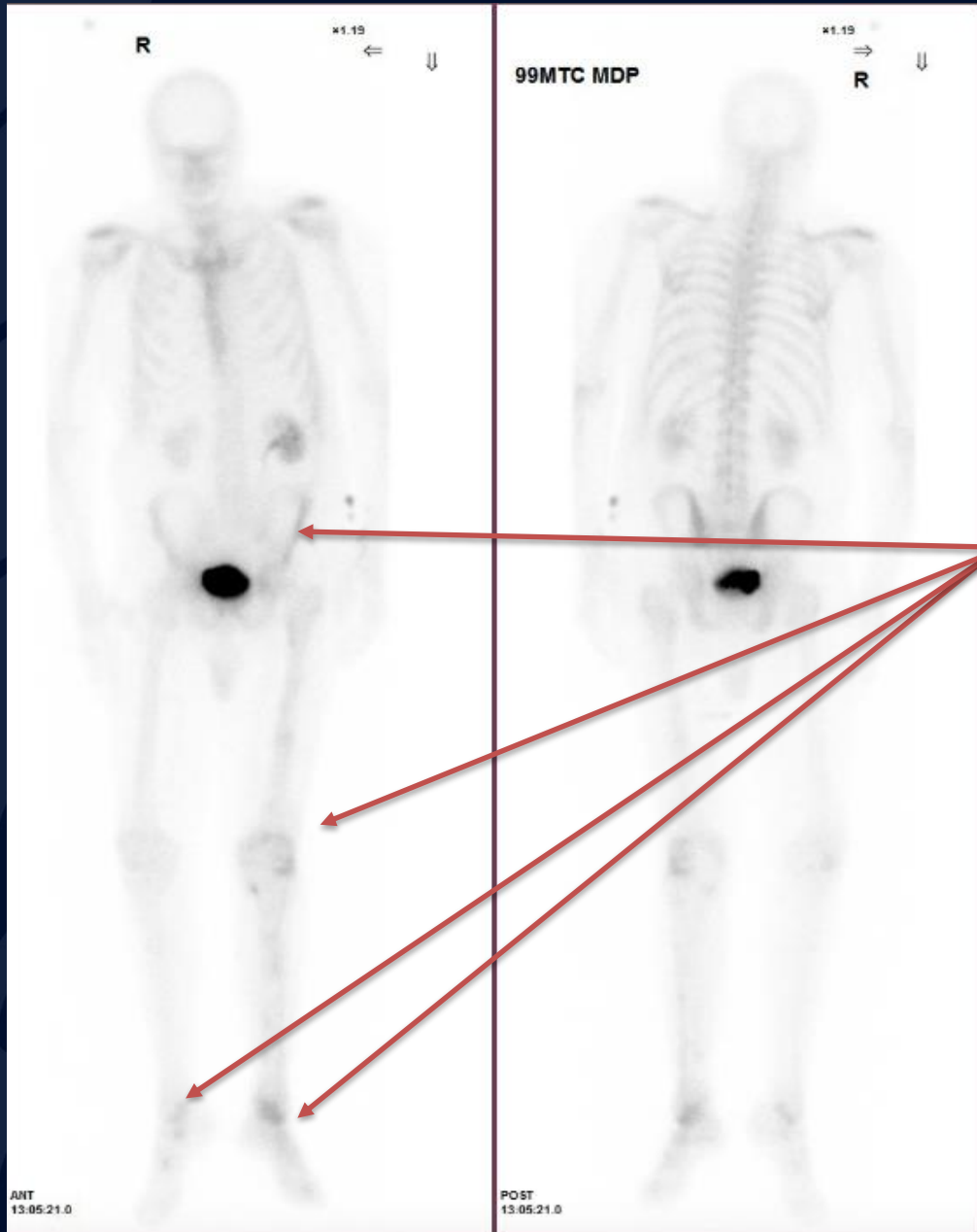
CTA Bilateral Lower Extremities

Innumerable lytic lesions throughout the pelvis and bilateral lower extremities.



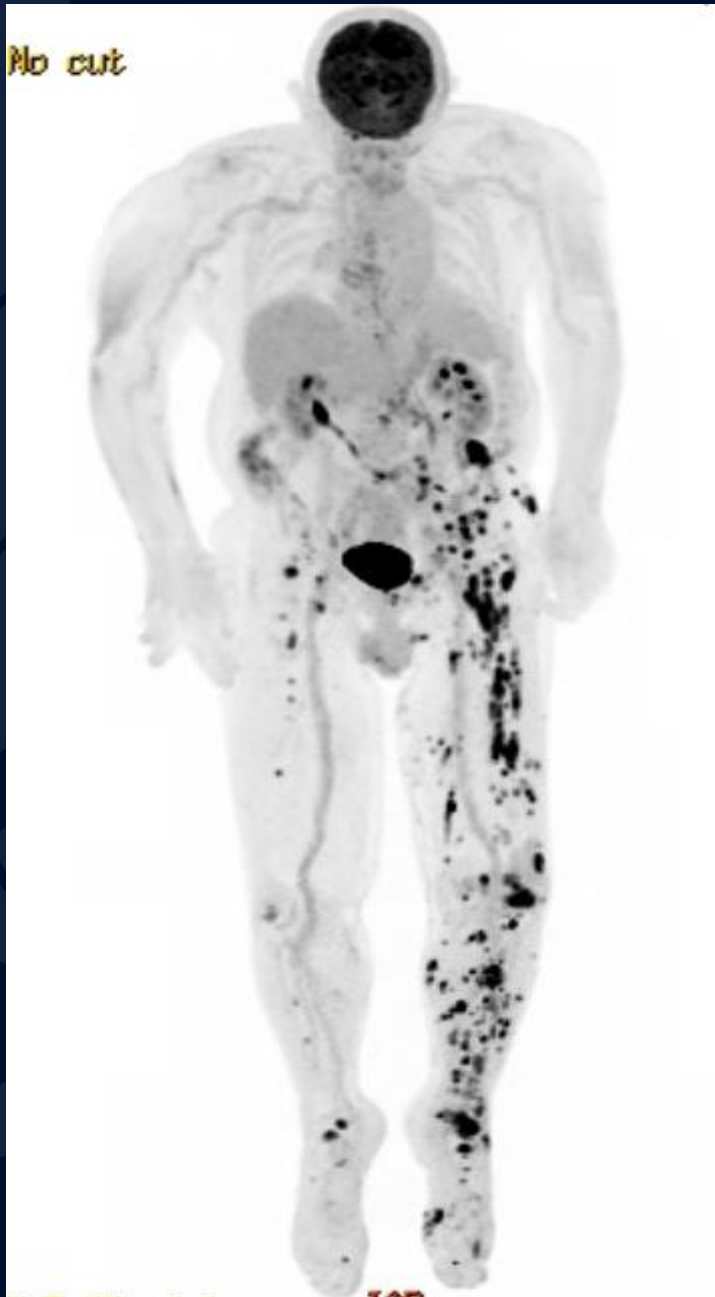
Adequate distal perfusion of the left lower extremity to the mid left foot with poor evaluation of the distal extremities as the contralateral side has relatively decreased contrast opacification distally.

NM Bone Scan



Multifocal radiotracer uptake within bilateral lower extremities, left greater than right that correspond to lytic lesions seen on most recent CTA.

Fluorine-18 FDG PET/CT Scan



Numerous FDG avid osseous as well as soft tissue lesions identified predominantly involving the left lower extremity and left hemipelvis. Additional significantly lesser number of osseous lesions are also present within the right lower extremity.

Involvement of the L3 vertebral body is also present.

The remainder of the entire visualized axial and appendicular skeleton otherwise appear unremarkable. Image guided biopsy from the partially destroyed left iliac crest may be considered for definitive tissue diagnosis, if clinically appropriate.

Metastatic Cutaneous Angiosarcoma

- Rare highly aggressive soft tissue sarcoma that arises from aberrant proliferation of vascular or lymphatic endothelial cells
- Associations with previous exposure to radiation therapy, chronic lymphedema, or severe peripheral vascular disease
- Has propensity to have wide distribution of metastases and therefore heavily relies on combination of patient history, clinical exam, laboratory findings and imaging to identify disorder and overall extent of disease.
- Diagnosis involves an interdisciplinary team which typically involves radiology, general or vascular surgery, and pathology
- Treatment options significantly vary and can range between surgery (wide excision or amputation) and chemotherapy (doxorubicin, paclitaxel and/or cisplatin-based regimens)
- Treatment is recommended to limit spread of disease and minimize risk of pathologic fracture.

References

- Abraham JA, Hornicek FJ, Kaufman AM, Harmon DC, Springfield DS, Raskin KA, Mankin HJ, Kirsch DG, Rosenberg AE, Nielsen GP, Deshpande V, Suit HD, DeLaney TF, Yoon SS. Treatment and outcome of 82 patients with angiosarcoma. *Ann Surg Oncol*. 2007 Jun;14(6):1953-67. [[PubMed](#)]
- Lewcun JA, Pameijer C, Kass R, Cream L, Hershock D, Brooks AJ, Dodge DG. Doxorubicin, paclitaxel, and cisplatin based chemotherapy for the treatment of angiosarcoma: Two case reports. *Int J Surg Case Rep*. 2020;68:83-87. doi: 10.1016/j.ijscr.2020.02.036. Epub 2020 Feb 21. PMID: 32120283; PMCID: PMC7052479.
- Rouhani P, Fletcher CD, Devesa SS, Toro JR. Cutaneous soft tissue sarcoma incidence patterns in the U.S. : an analysis of 12,114 cases. *Cancer*. 2008 Aug 01;113(3):616-27. [[PubMed](#)]
- Spiker AM, Mangla A, Ramsey ML. Angiosarcoma. 2022 Nov 30. In: *StatPearls* [Internet]. Treasure Island (FL): StatPearls Publishing; 2023 Jan–. PMID: 28723012.