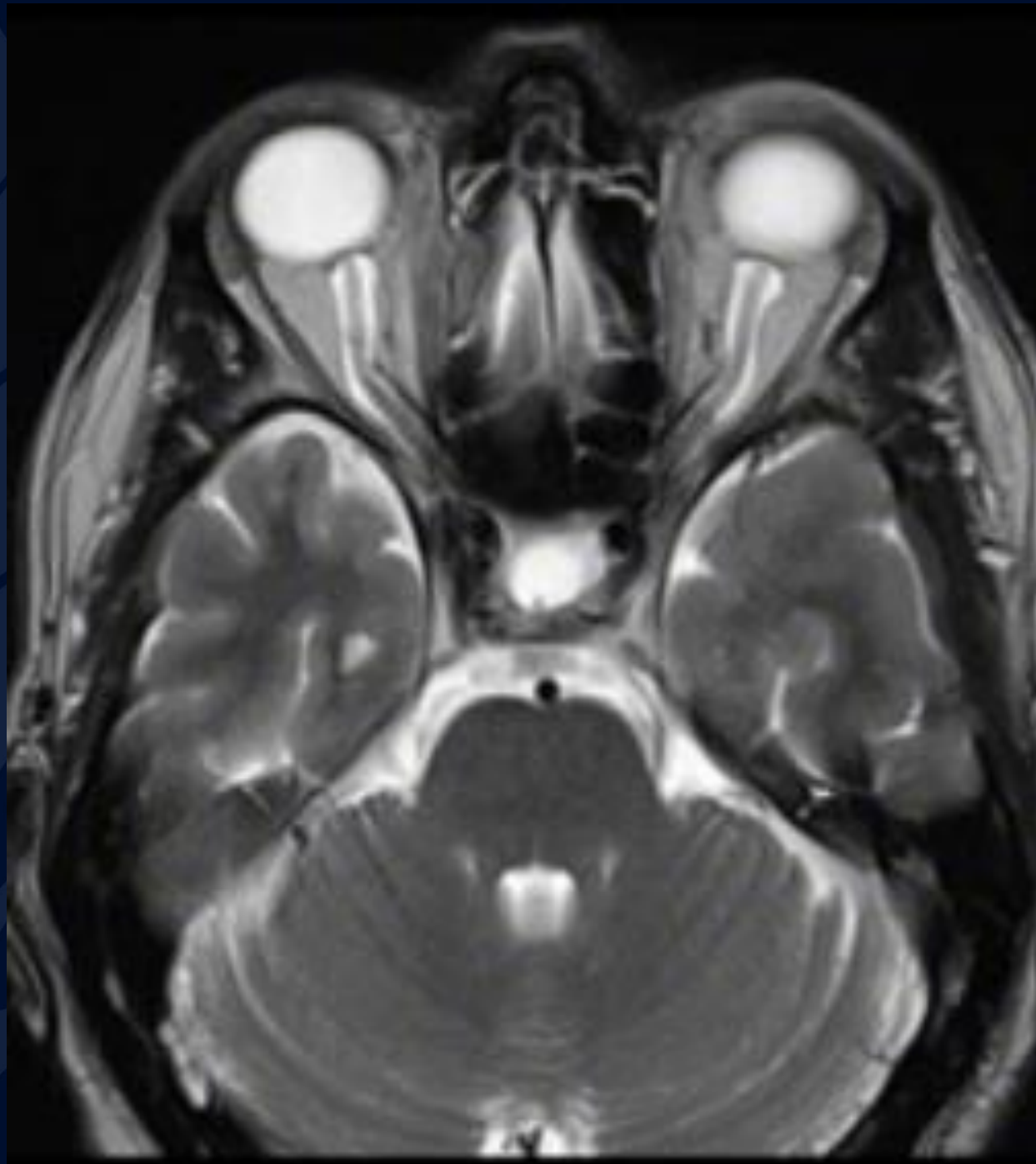
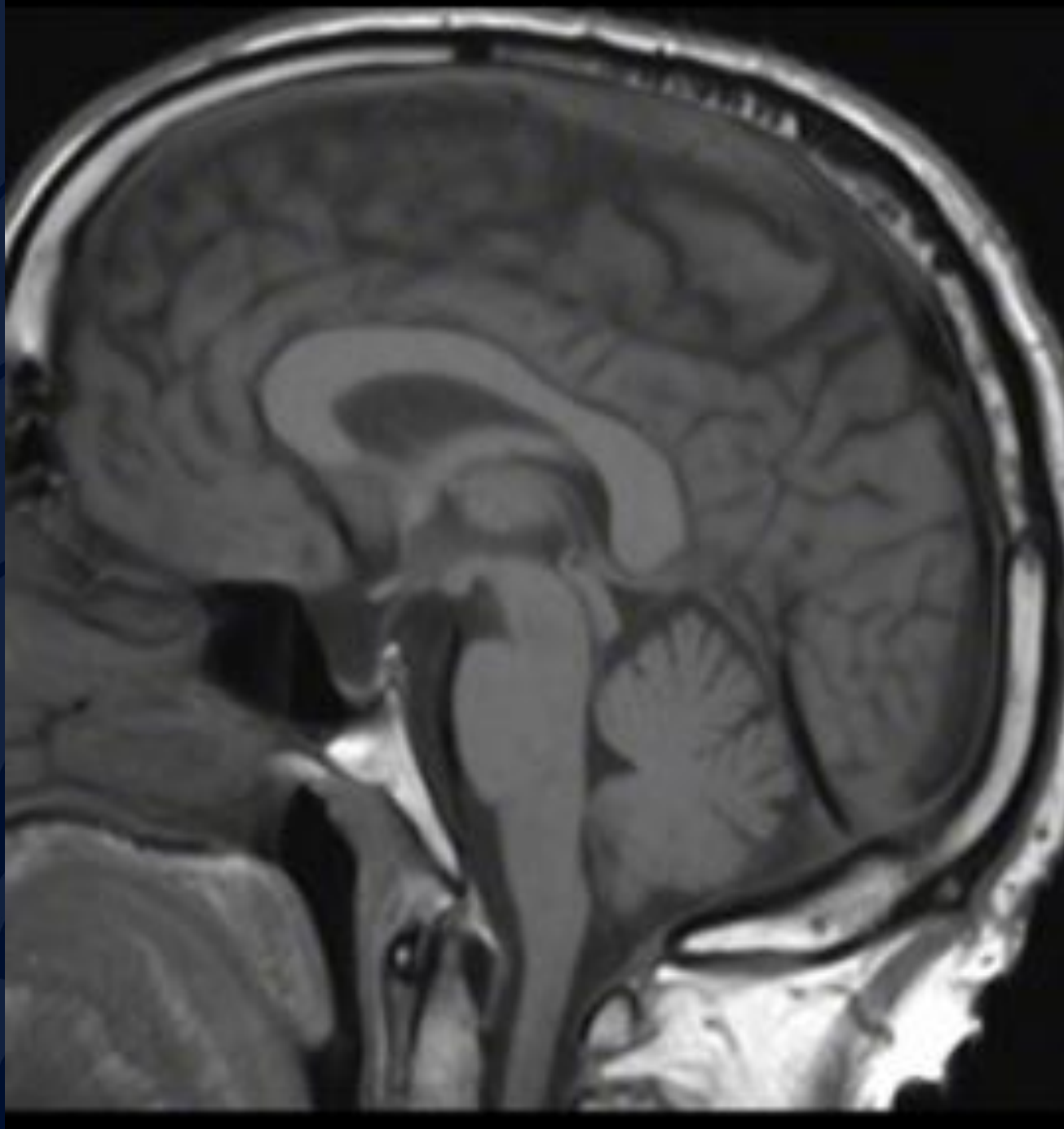


42-year-old female presents with headaches

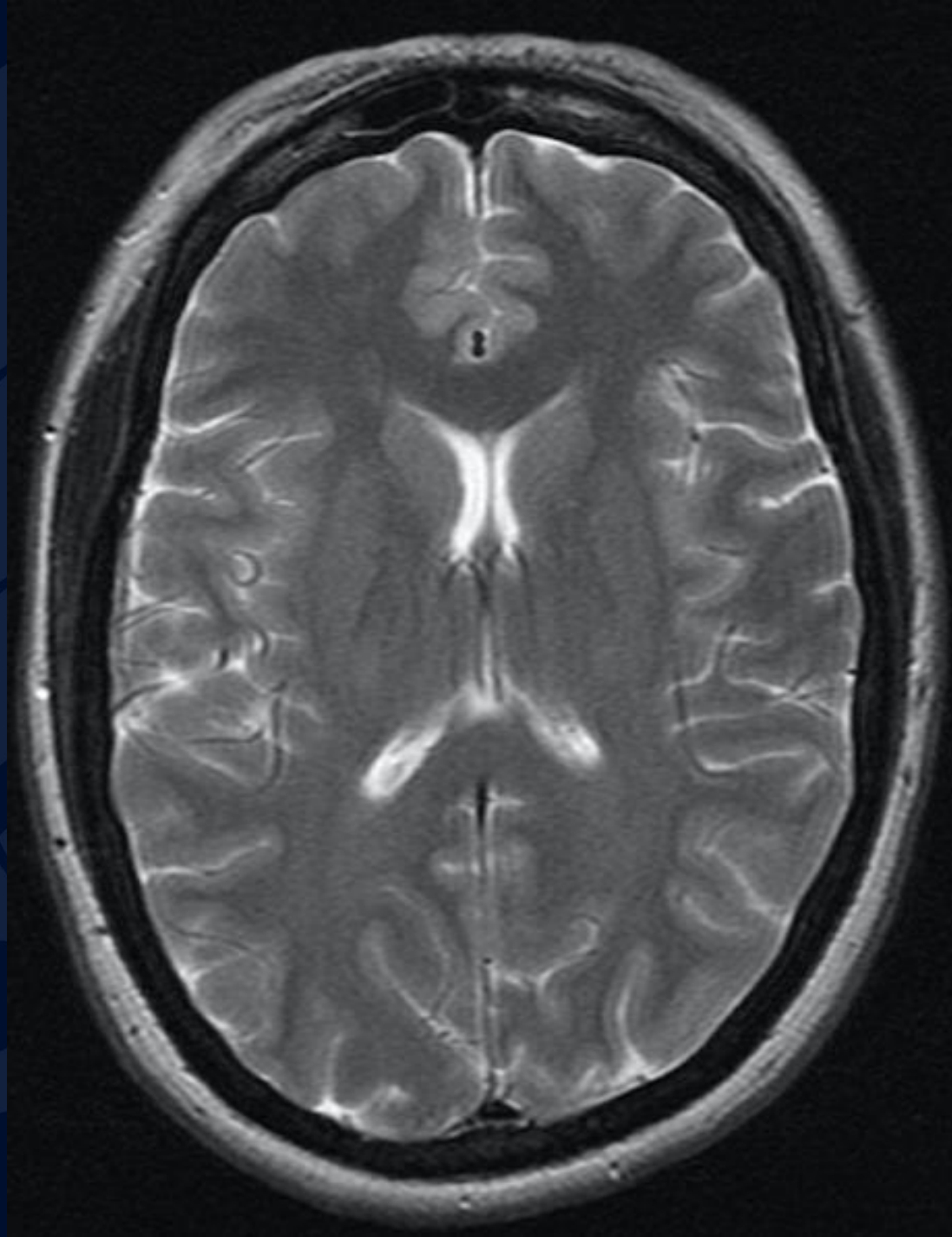
Jignesh Modi, MD



Axial T2



Sagittal T1



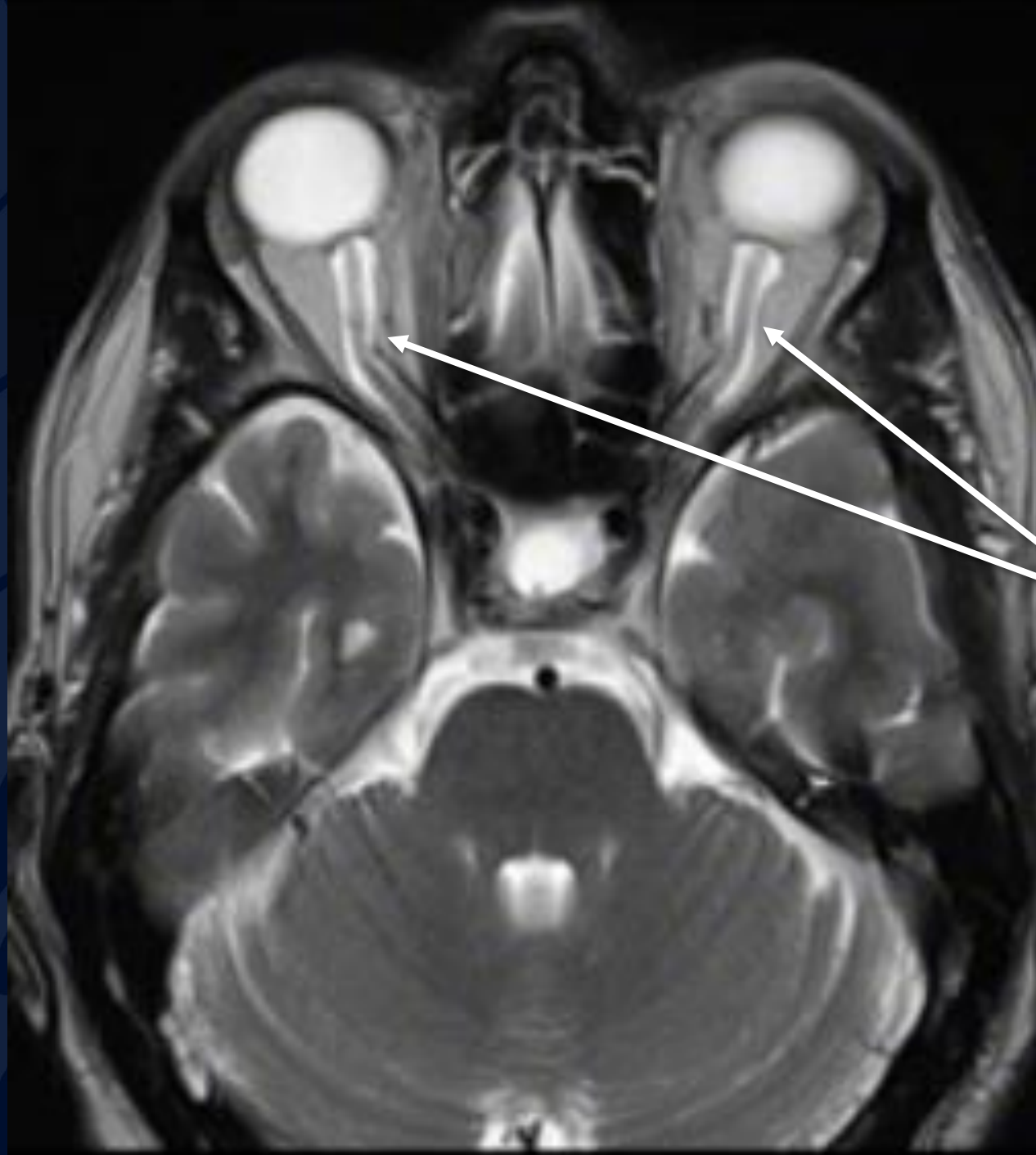
Axial T2



?

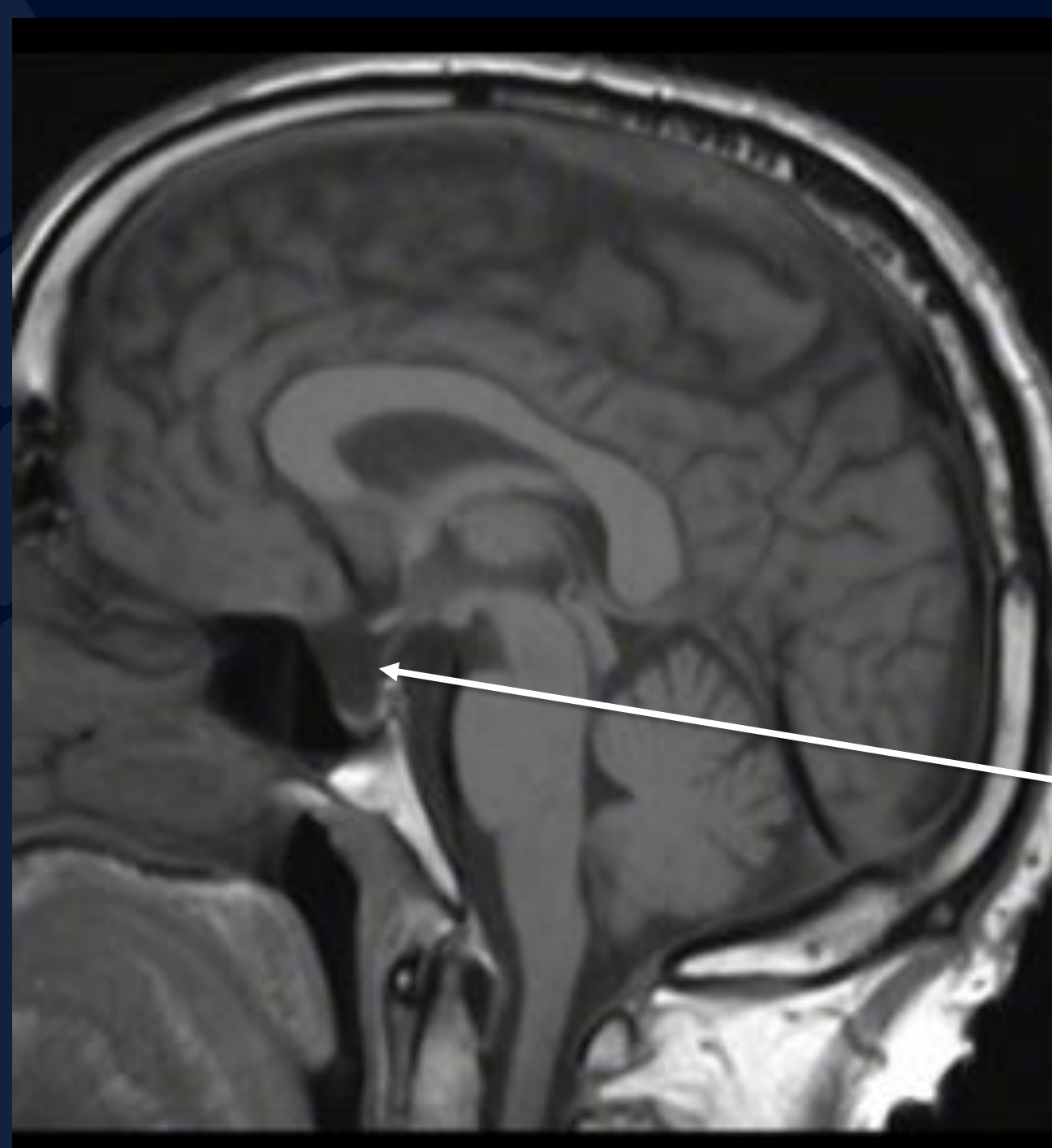
A large, stylized oak leaf graphic in a dark blue color, positioned on the left side of the slide, partially overlapping the title text.

Intracranial Hypertension



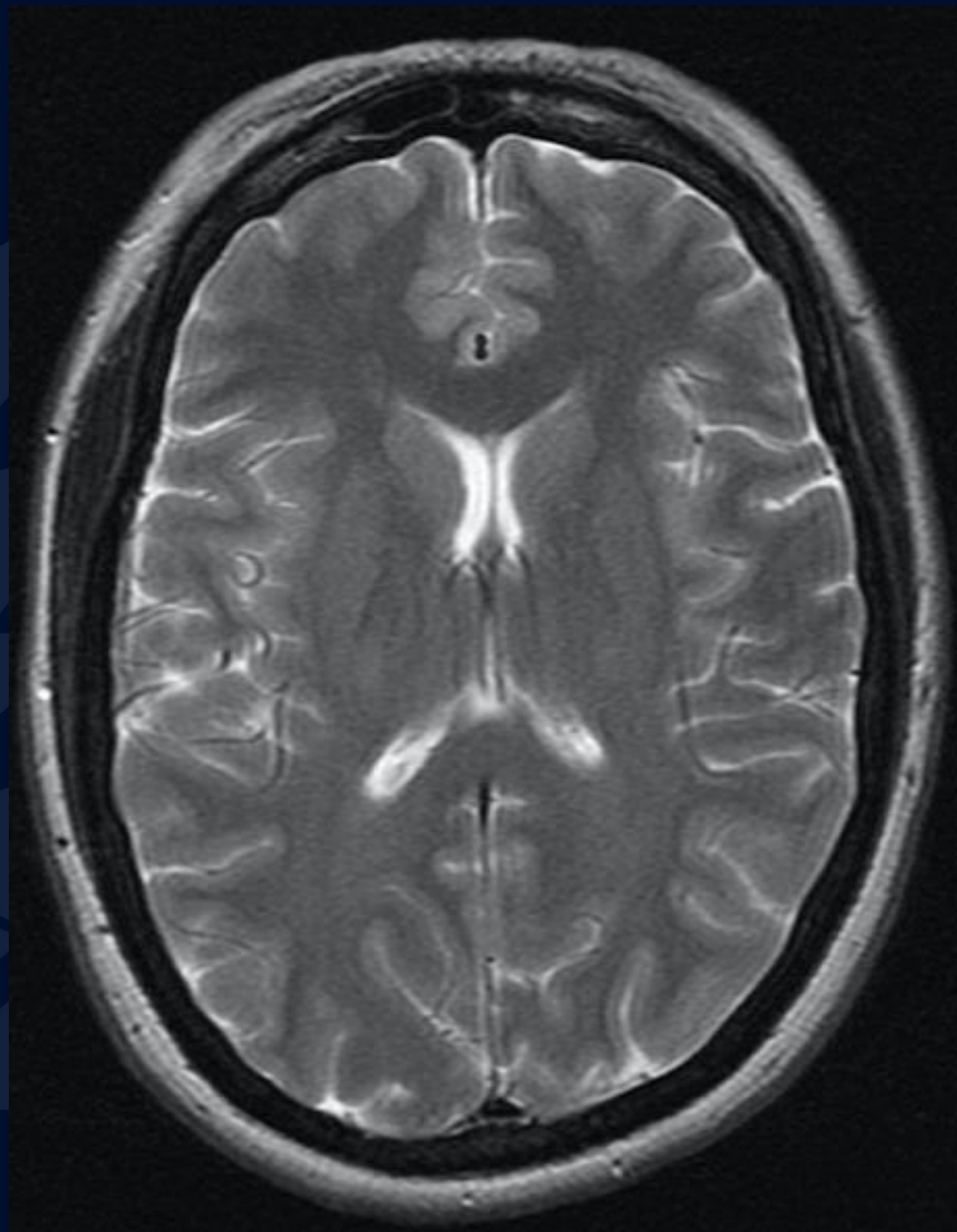
Axial T2

Fluid around optic
nerve sheath
complexes and
protrusion of optic
heads



Sagittal T1

Partial empty sella



Axial T2

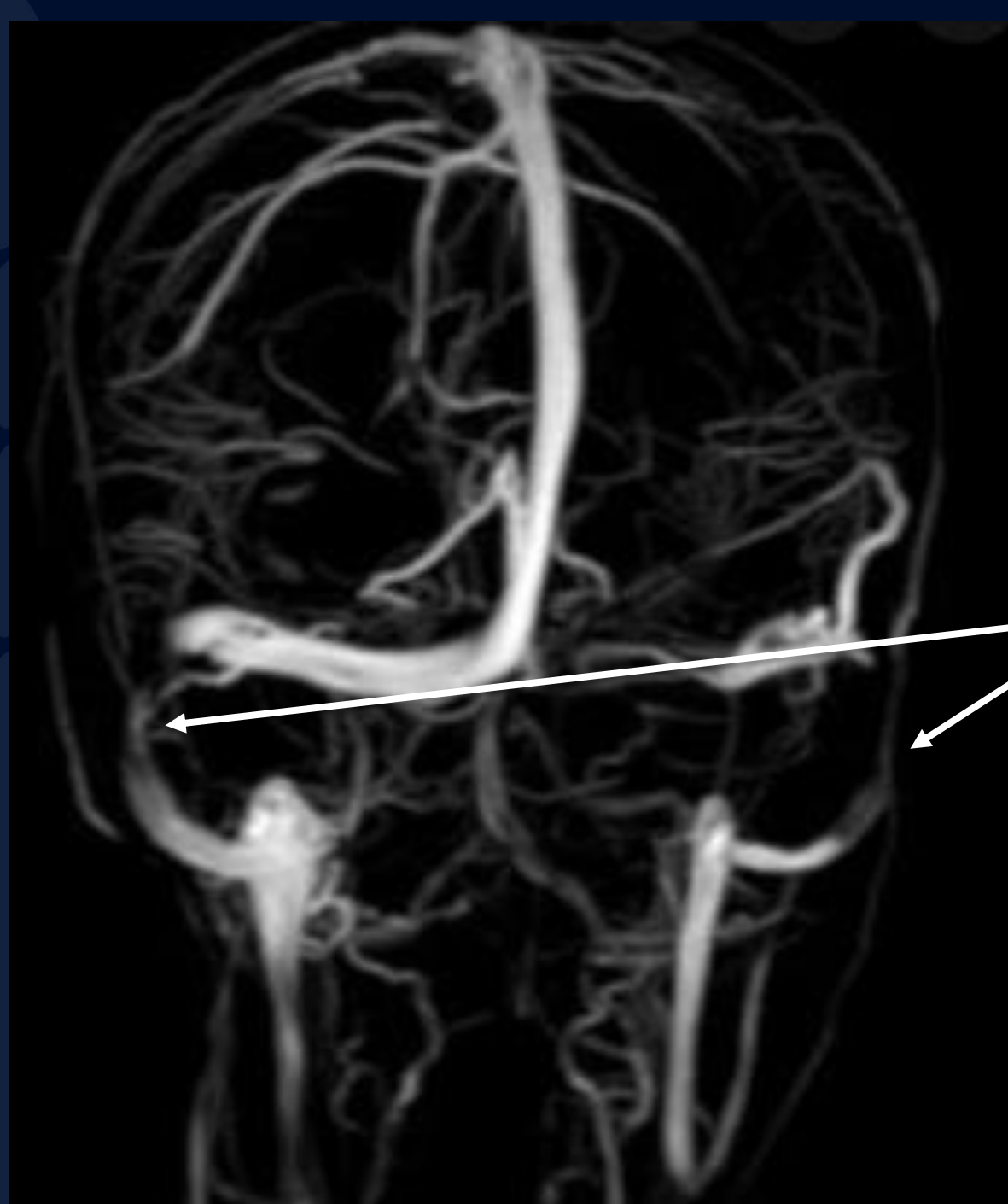
Slit-like ventricles

IDIOPATHIC INTRACRANIAL HYPERTENSION (PSEUDOTUMOR CEREBRI)

- Syndrome with signs and symptoms of increased intracranial pressure, without a causative mass or hydrocephalus identified.
- Clinically presents with headaches, visual problems, tinnitus, papilledema.
- Exact etiology is unknown; association between venous outflow stenosis/obstruction and this entity.
 - Also associated with endocrine disorders, drugs (acne medications), SLE, chronic renal failure, hypervitaminosis in pediatric population
- Most commonly affects middle aged obese females.
- CSF opening pressure measurement plays a key role.

Imaging Features

- Best seen on MRI Brain
 - Slit like ventricles
 - **Optic nerves:** flattening of posterior globe, intraocular protrusion of optic nerve head, enhancement of optic nerves
 - **Enlarged arachnoid outpouchings:** partial empty sella, enlarged Meckel cave, prominent arachnoid pits/ aberrant arachnoid granulations / meningoceles
 - **Most sensitive findings:** Bilateral venous sinus stenosis at lateral segments
 - Acquired tonsillar ectopia



Bilateral transverse sinus thrombosis

Treatment

- Treatment options include CSF letting, acetazolamide and lumboperitoneal shunts. In patients with progressive visual deterioration, optic nerve fenestration may be required to preserve vision.
- Venous sinus stenting has been reported in case series and is also being trialed. It is unclear whether venous sinus stenosis is the cause of the effect of idiopathic intracranial hypertension, therefore this treatment is controversial.

References

- Silbergleit R, Junck L, Gebarski SS et-al. Idiopathic intracranial hypertension (pseudotumor cerebri): MR imaging. *Radiology*. 1989;170 (1): 207-9. *Radiology (abstract)* - Pubmed citation
- Digre KB. Not so benign intracranial hypertension. *BMJ*. 2003;326 (7390): 613-4. doi:10.1136/bmj.326.7390.613 - Free text at pubmed - Pubmed citation
- Zagardo MT, Cail WS, Kelman SE et-al. Reversible empty sella in idiopathic intracranial hypertension: an indicator of successful therapy? *AJNR Am J Neuroradiol*. 17 (10): 1953-6. *AJNR Am J Neuroradiol (abstract)* - Pubmed citation
- Higgins JN, Cousins C, Owler BK et-al. Idiopathic intracranial hypertension: 12 cases treated by venous sinus stenting. *J. Neurol. Neurosurg. Psychiatr*. 2003;74 (12): 1662-6. doi:10.1136/jnnp.74.12.1662 - Free text at pubmed - Pubmed citation
- De Lucia D, Napolitano M, Di micco P et-al. Benign intracranial hypertension associated to blood coagulation derangements. *Thromb J*. 2006;4 : 21. doi:10.1186/1477-9560-4-21 - Free text at pubmed - Pubmed citation
- Suzuki H, Takanashi J, Kobayashi K et-al. MR imaging of idiopathic intracranial hypertension. *AJNR Am J Neuroradiol*. 2001;22 (1): 196-9. *AJNR Am J Neuroradiol (full text)* - Pubmed citation
- Schuknecht B, Simmen D, Briner HR et-al. Nontraumatic skull base defects with spontaneous CSF rhinorrhea and arachnoid herniation: imaging findings and correlation with endoscopic sinus surgery in 27 patients. *AJNR Am J Neuroradiol*. 2008;29 (3): 542-9. doi:10.3174/ajnr.A0840 - Pubmed citation
- Leach J, Fortuna R, Jones B et-al. Imaging of Cerebral Venous Thrombosis: Current Techniques, Spectrum of Findings, and Diagnostic Pitfalls¹. *Radiographics*. 2006;26 (suppl 1): S19-S41. *Radiographics (full text)* - doi:10.1148/rg.26si055174
- Bialer OY, Rueda MP, Bruce BB et-al. Meningoceles in idiopathic intracranial hypertension. *AJR Am J Roentgenol*. 2014;202 (3): 608-13. doi:10.2214/AJR.13.10874 - Free text at pubmed - Pubmed citation
- Ahmed RM, Wilkinson M, Parker GD et-al. Transverse sinus stenting for idiopathic intracranial hypertension: a review of 52 patients and of model predictions. *AJNR Am J Neuroradiol*. 2011;32 (8): 1408-