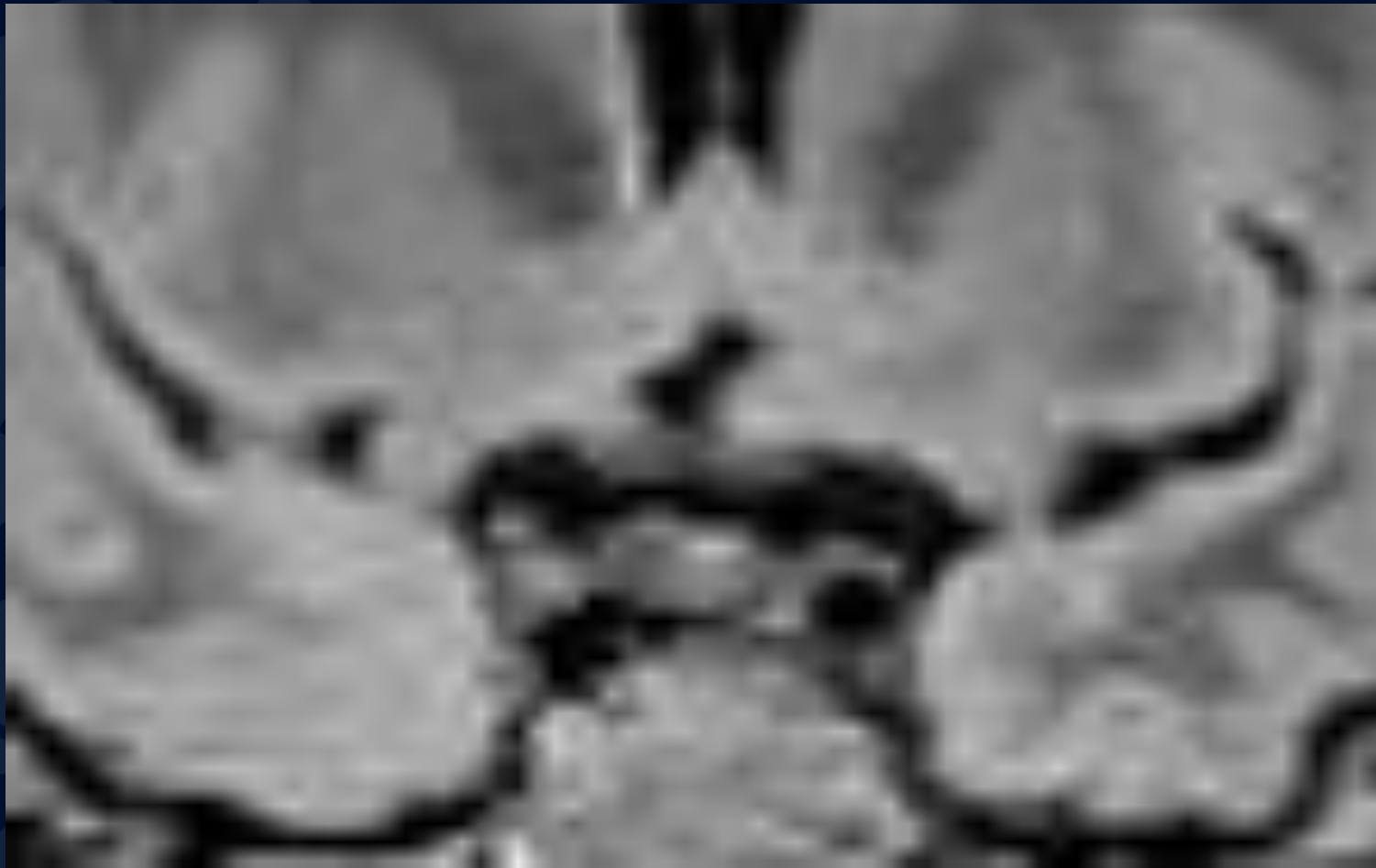

# 45M for w/u of Pituitary Dysfunction

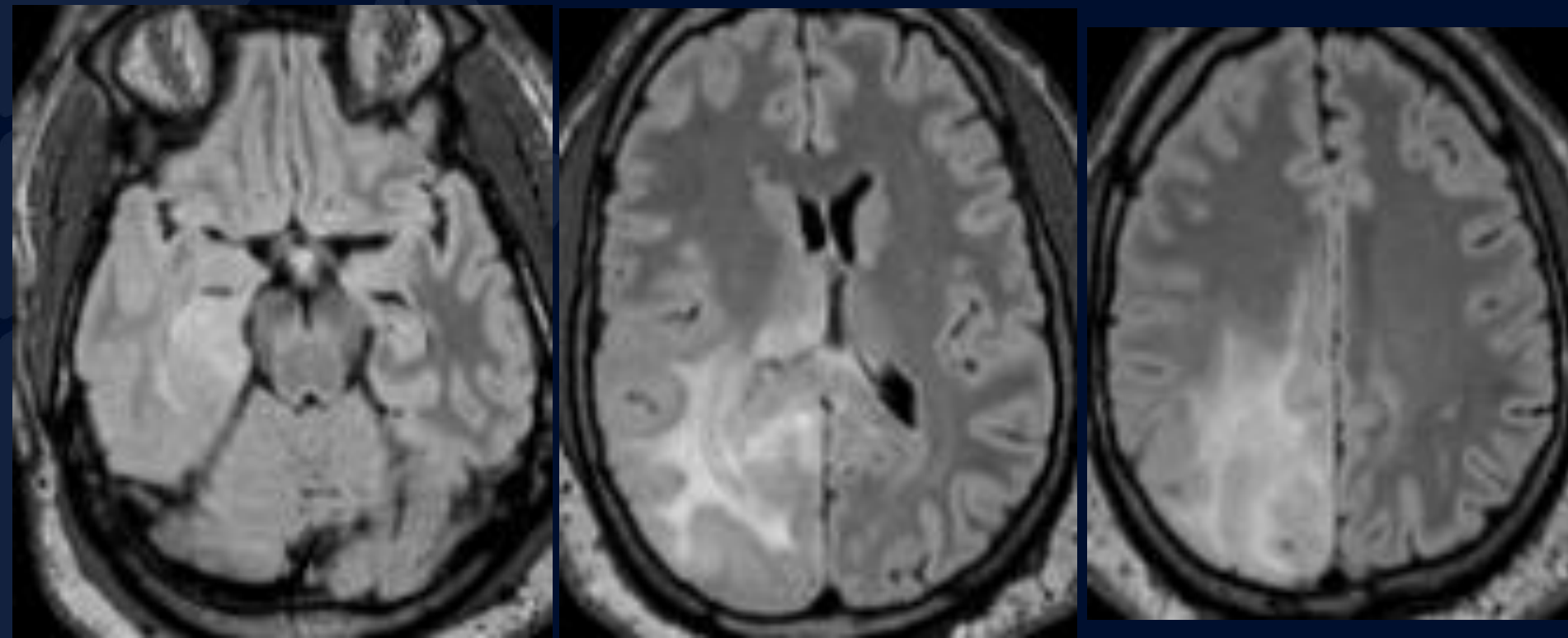
Andrew Klufas, MD

Roman Klufas, MD

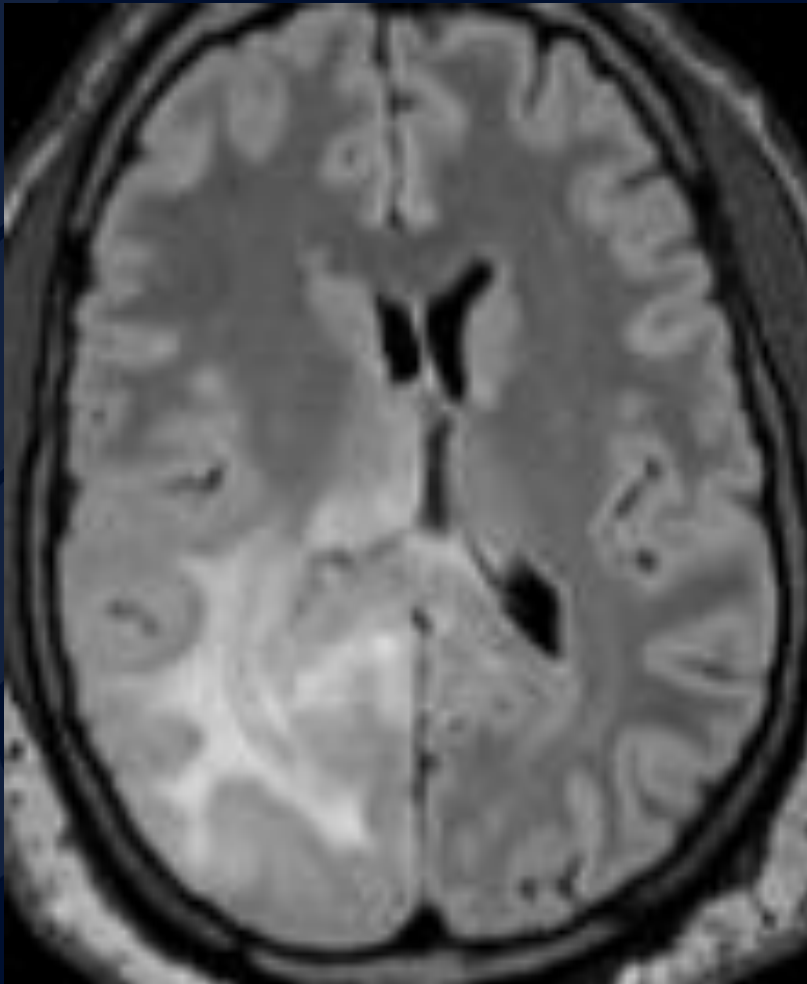
# Coronal FLAIR at the Level of the Pituitary



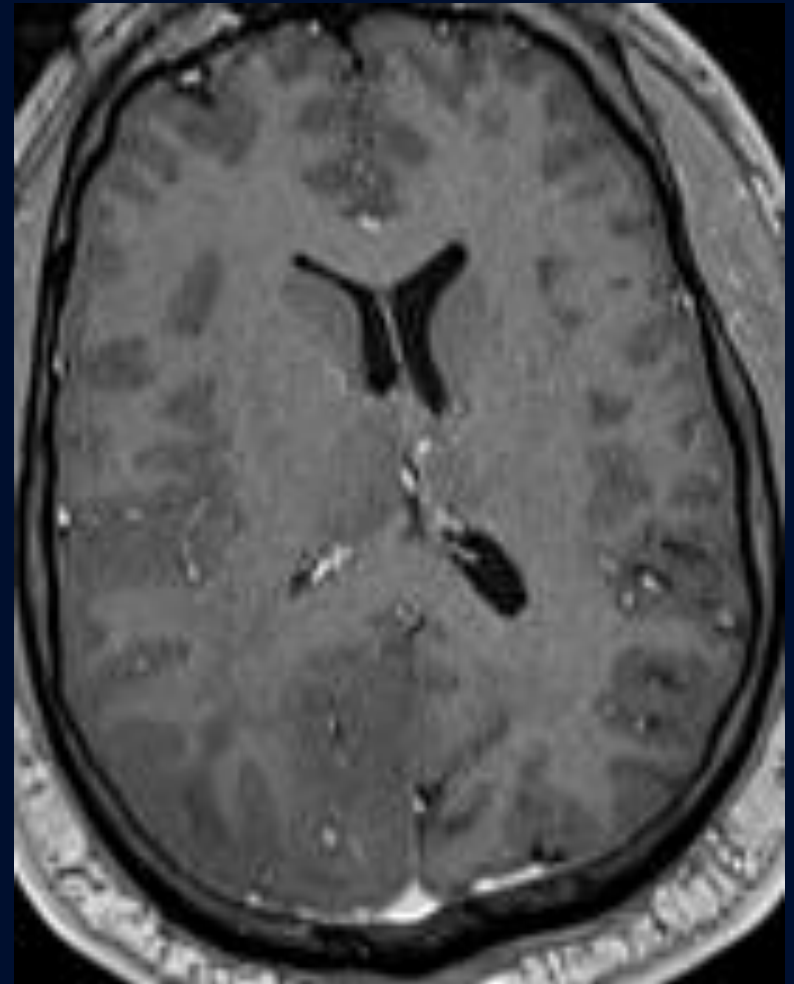
# Axial FLAIR



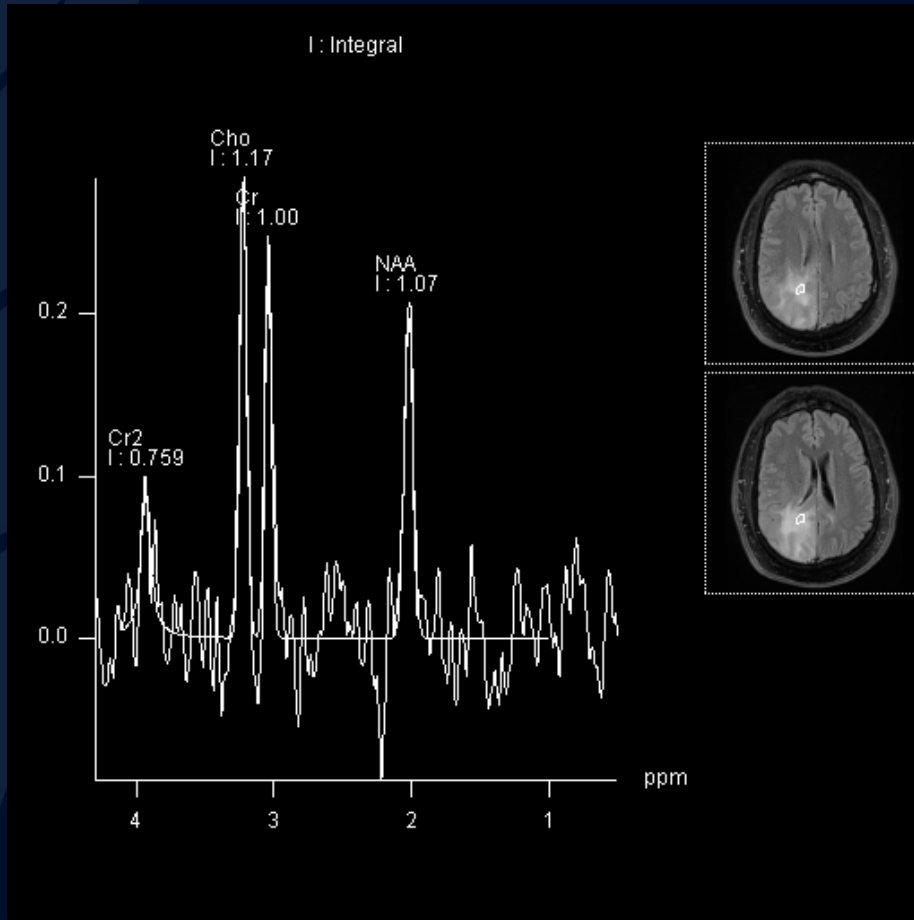
Axial FLAIR



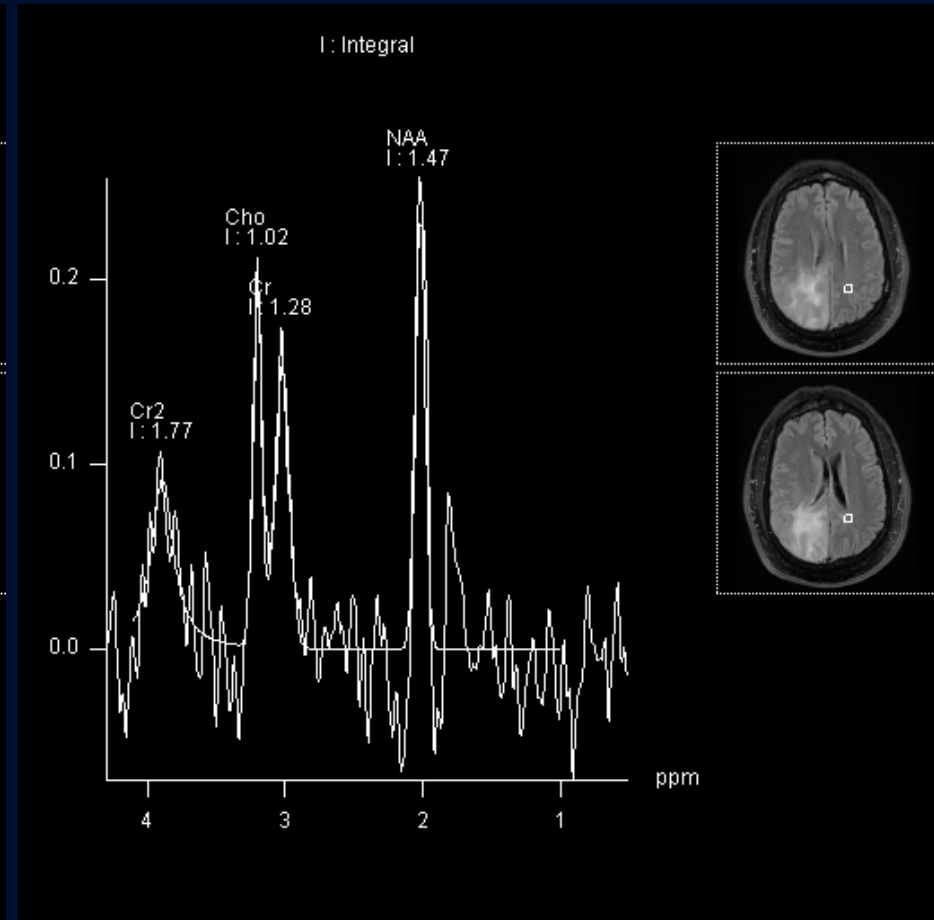
Axial Gd-T1



# MR Spectroscopy (MRS)



Abnormal Brain MRS



Normal Brain MRS



?

A large, stylized oak leaf graphic in a dark blue color, positioned on the left side of the slide, partially overlapping the text.

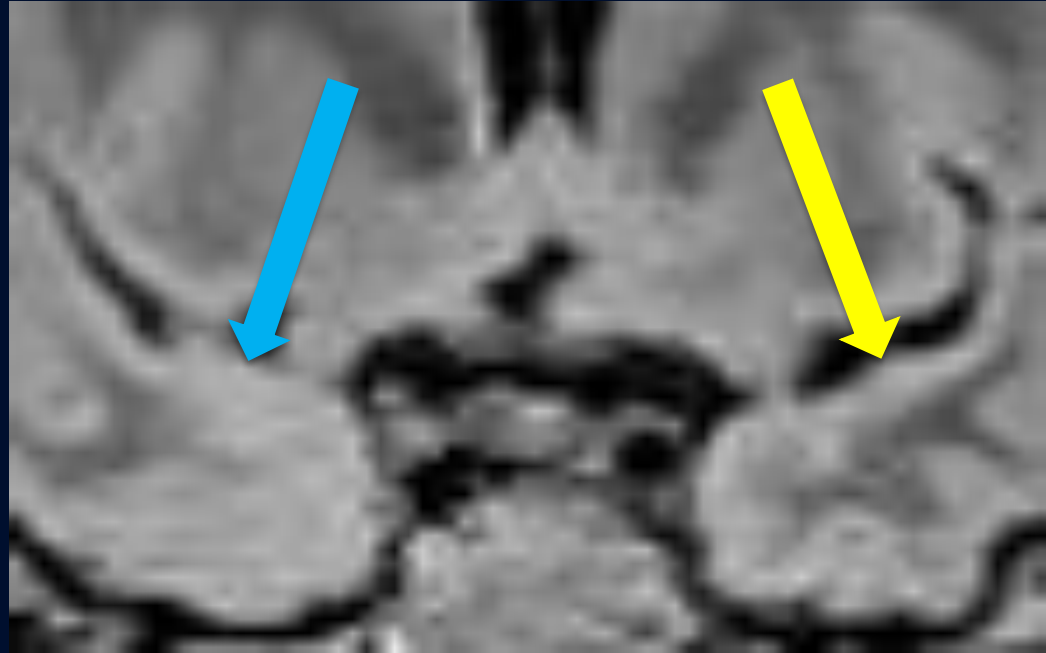
# Infiltrating Glioma

## “Gliomatosis Cerebri”

# Coronal FLAIR at the Level of the Pituitary

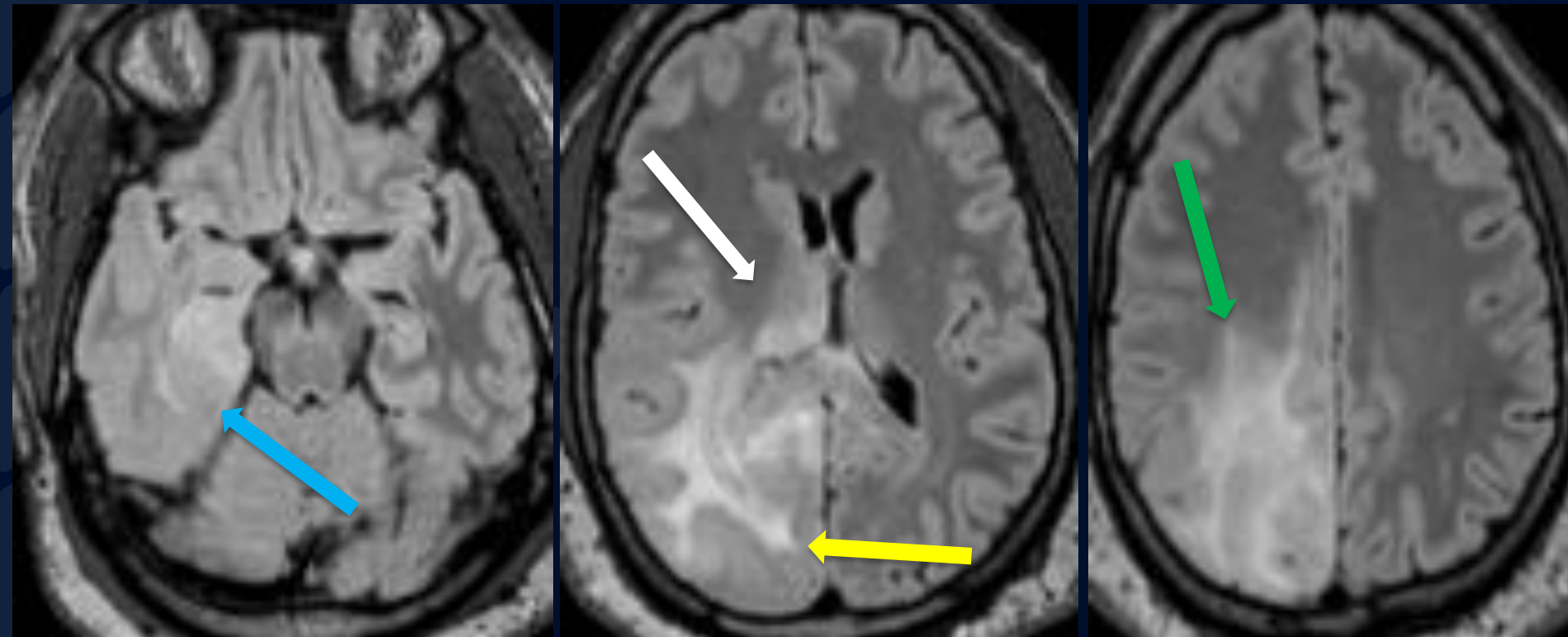
There is thickening of the cortex (blue arrow) and invasion within the right temporal lobe.

- Normal grey matter thickness indicated by yellow arrow



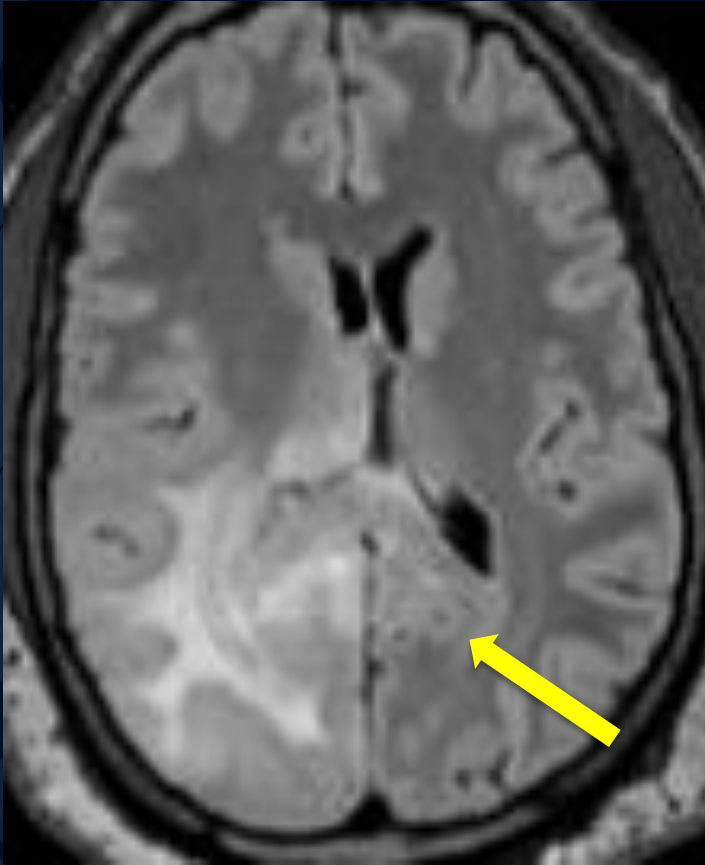


# Axial FLAIR

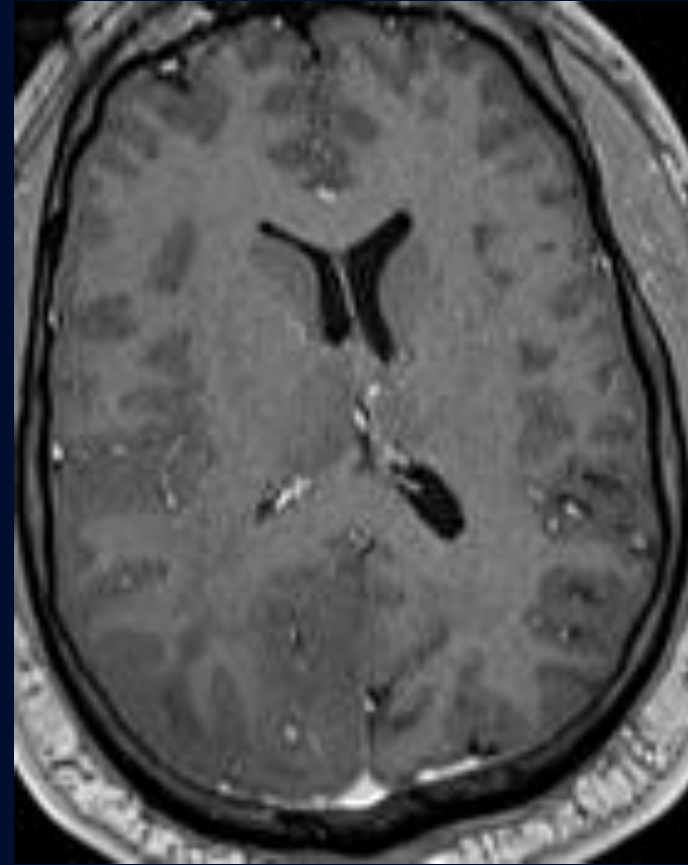


The above images show the glioma involving more white than grey matter of the temporal lobe (blue arrow), right occipital lobe (yellow arrow), parietal lobe (green arrow), & right thalamus (white arrow)

# Axial FLAIR and T1-Gd

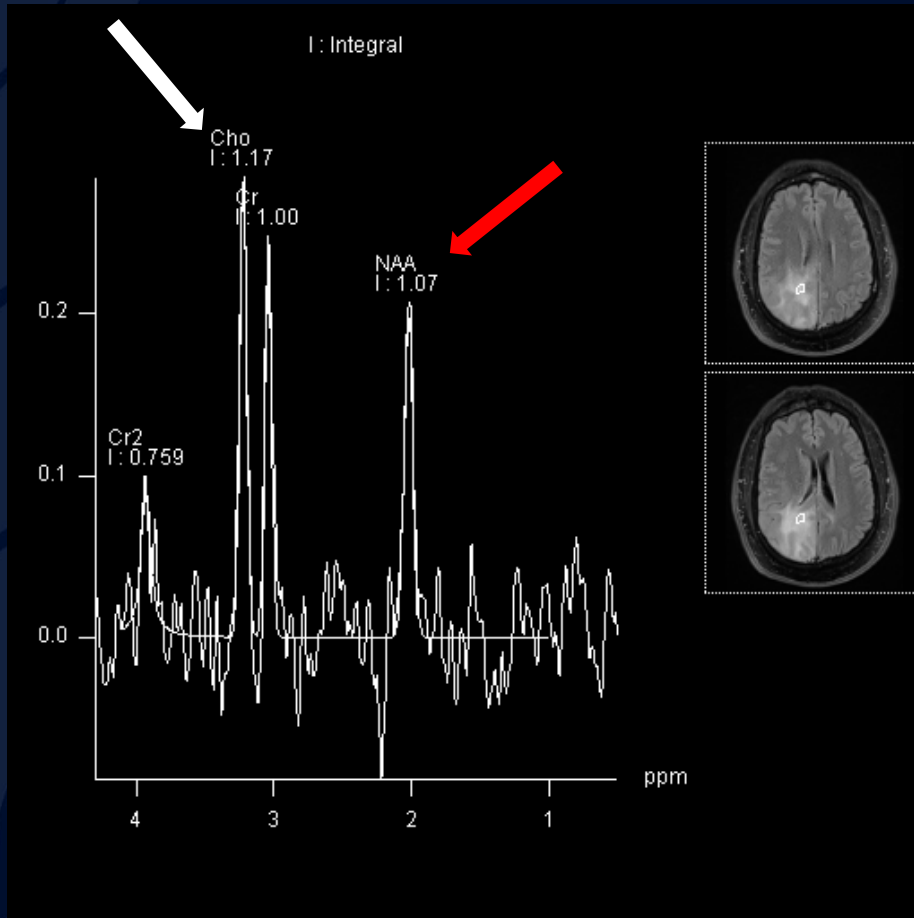


FLAIR hyperintensity crosses the splenium of the corpus callosum to involve the left hemisphere (yellow arrow)

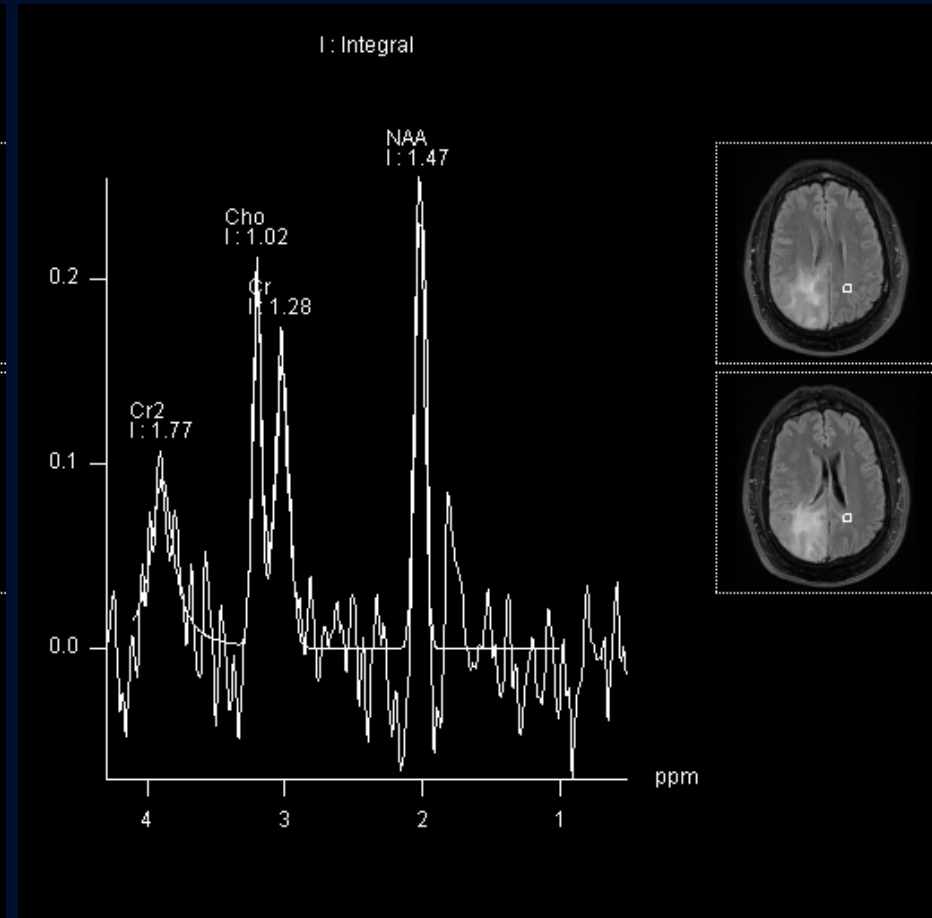


No significant gadolinium enhancement is identified

# MRS of both Normal & Abnormal Brain



MRS of abnormal brain displays significant elevation of choline peak (white arrow) and decrease of NAA peak (red arrow) relative to creatine peak



MRS of normal brain shows no such changes

# Infiltrating Glioma (“Gliomatosis Cerebri”)

**Epidemiology:** Most often occurs between 20-40 years of age and affects males slightly more than females (1.5:1). Prognosis is poor with 26-52% of patients surviving less than 1 year.

**Classification:** Can be unclear but is generally organized by histological, clinical, and radiographic features

- Primary Gliomatosis Cerebri includes any *de novo* tumors and can be subdivided into Type 1 (no discrete mass) and Type 2 (discrete mass with diffuse CNS involvement)
  - Further subcategorization can be done with respect to IDH-gene classification (mutant vs. wildtype) and molecular grade
- Secondary Gliomatosis Cerebri follows the same classification structure above

# Infiltrating Glioma (“Gliomatosis Cerebri”)

## Imaging:

- **MRI:**
  - T1 shows hypo- or iso-intensity to grey matter and does not enhance with gadolinium administration
  - T2 shows hyperintensity to grey matter
  - MR Spectroscopy will show elevated Choline:Creatine and decreased Choline:NAA ratios relative to normal brains as well as elevated myoinositol levels
- **FDG-PET:**
  - Hypometabolism will be present in affected areas
- **CT:** Can often be normal due to isodensity of lesions relative to surrounding brain parenchyma
  - Mass effect can still be seen with Type 2 Gliomatosis Cerebri however an MRI would be required for further investigation
  - Hypoattenuation may be evident however it has been shown to be quite subtle if present

## Other Possible Diagnoses

- Progressive Multifocal Leukoencephalopathy
- Multifocal/Multicentric Glioblastoma
- Primary CNS Lymphoma
- Encephalitis

# References:

- Ranjan S, Warren KE. “Gliomatosis Cerebri: Current Understanding and Controversies.” *Frontiers in oncology* vol. 7 165. 7 Aug. 2017, doi:10.3389/fonc.2017.00165
- Gaillard F, Stewart M. “Gliomatosis cerebri.” Reference article, Radiopaedia.org. <https://doi.org/10.53347/rID-1389>
- Citation: Klufas A, Klufas R, Gliomatosis Cerebri “Infiltrating Glioma.” Radiology Online. 2021