

33-year-old female triathlete who presented with bilateral lower extremity claudication

Nicholas Bellas, MS3

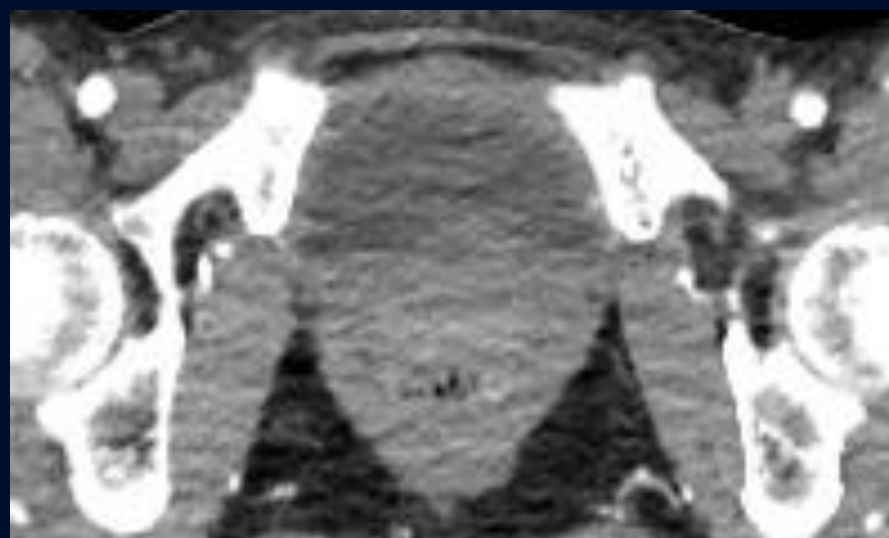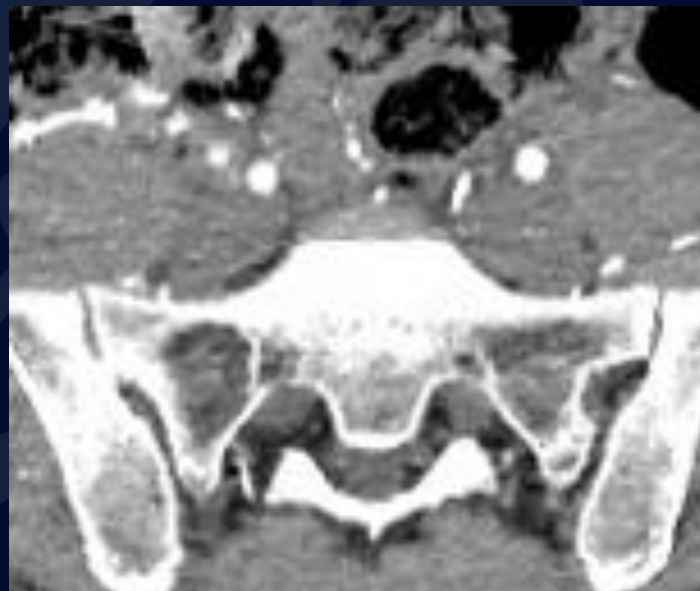
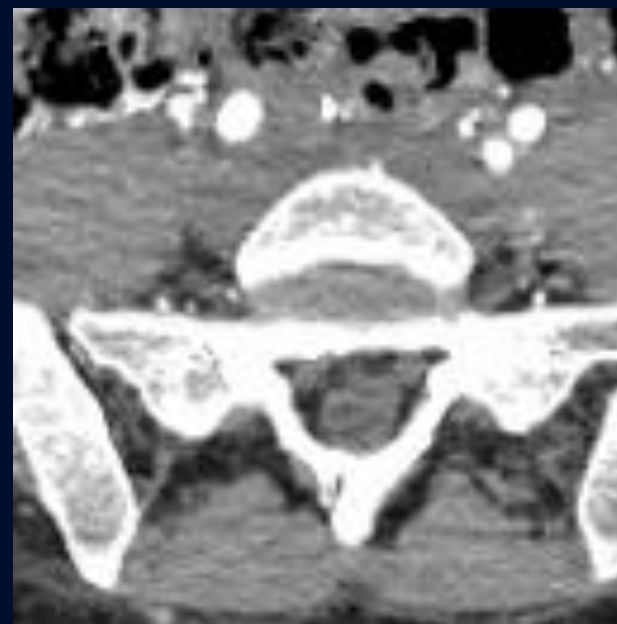
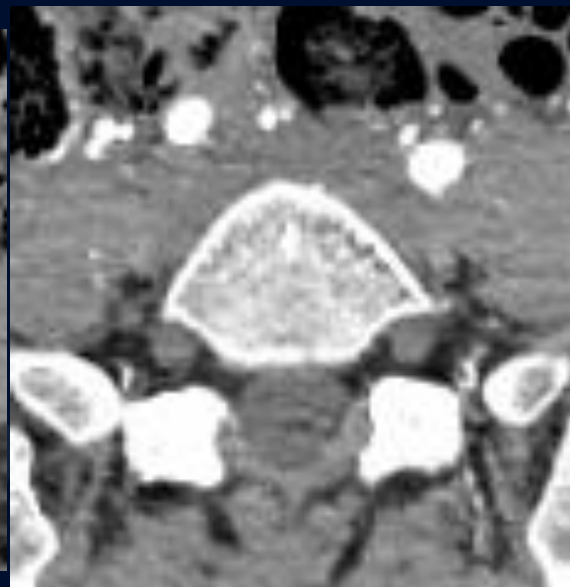
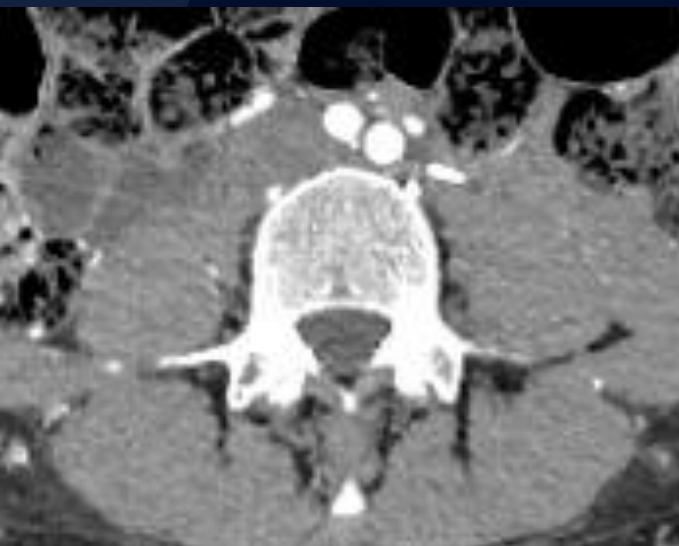
Edward Gillis, DO

Brad Kincaid, MD



UConn
HEALTH
RADIOLOGY

Sequential images from CTA Aorta with Run-off

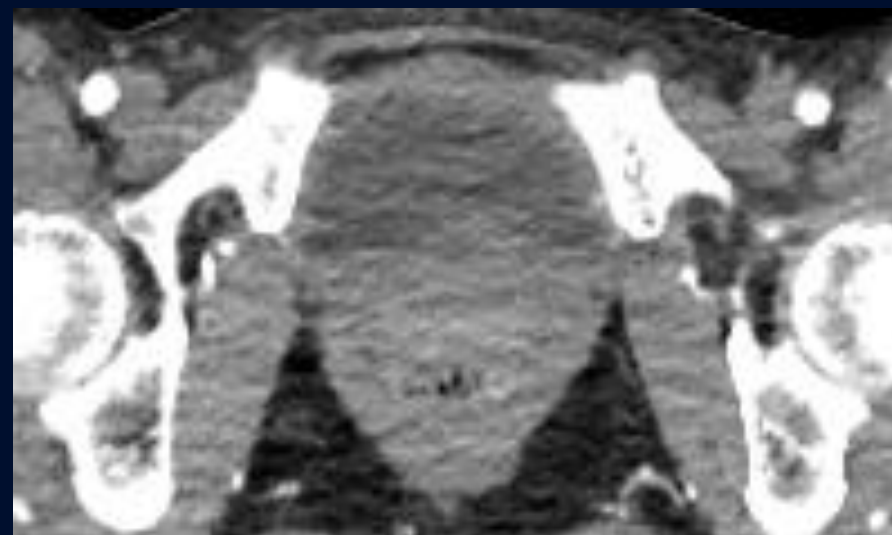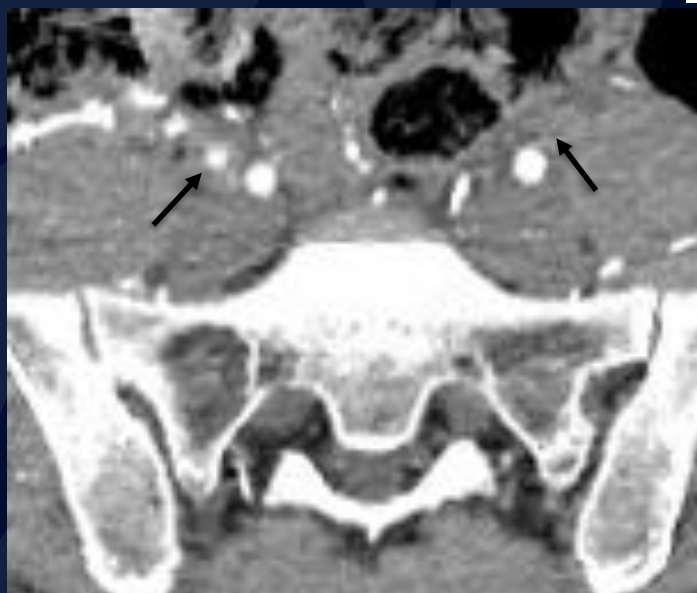
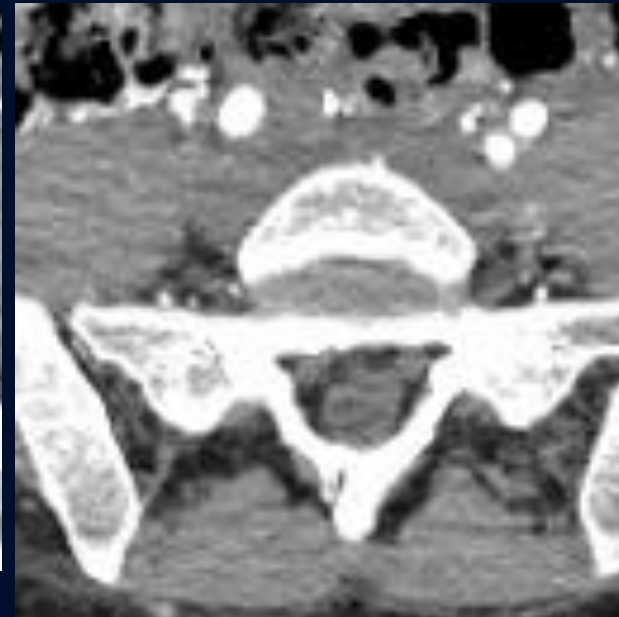
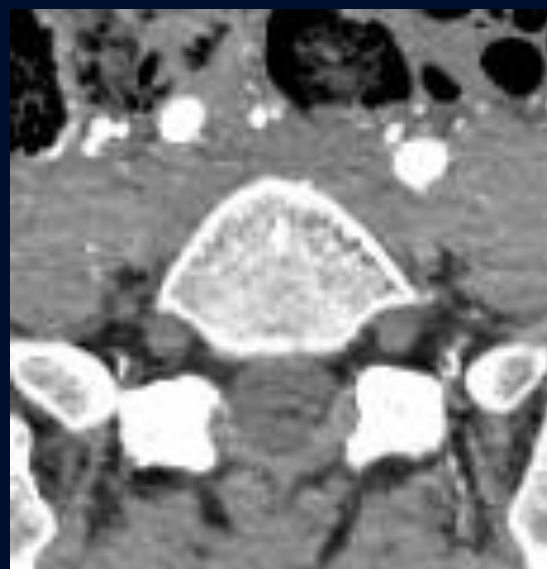

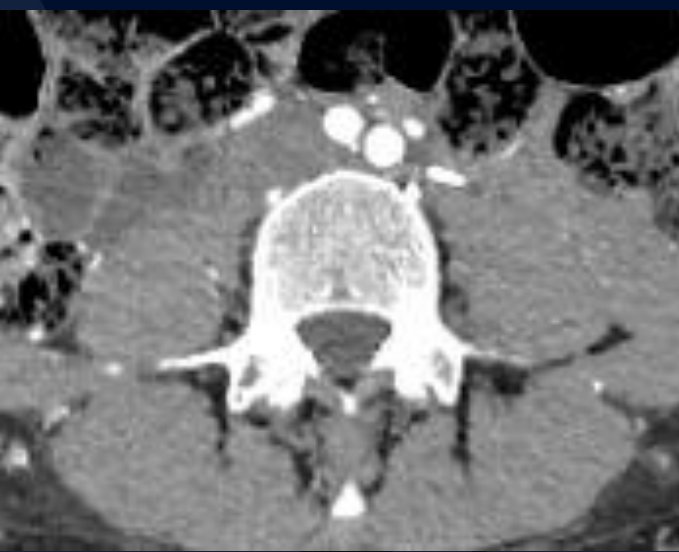
NN
TH

A large, stylized oak leaf graphic in a dark blue color, positioned on the left side of the slide. It features detailed vein patterns and a lobed edge.

?

Bilateral External Iliac Artery Endofibrosis



Sequential axial CTA runoff images show narrowing of the right external iliac artery and total occlusion of the left external iliac artery (bottom, left)

External Iliac Artery Endofibrosis

Epidemiology

- Rare disease seen primarily in young, otherwise healthy, endurance athletes
- Approx. 10-15% of patients have bilateral disease upon presentation
- Less than 5% have claudication due to a localized dissection or thrombosis

Etiology

- The disorder is characterized by fibrosis and hypertrophy of the intimal layer of the artery wall
- The etiology of EIAE has been postulated to be due to trauma from one or a combination of the following:
 - “kinking” during repetitive hip flexion
 - psoas muscle hypertrophy compressing the artery
 - excessive and tortuous vessel length
 - increased cardiac output with adaptive hypertension

External Iliac Artery Endofibrosis

Radiology Findings and Evaluation:

- CTA Aorta to evaluate vessel patency or evidence of thrombosis.
- The arterial stenosis usually occurs in the first 2-6cm of the external iliac artery.
- Common iliac artery or deep femoral artery can also be affected.

Treatment

- Surgical: Vein patch angioplasty, saphenous vein bypass, release from psoas muscle.

References

1. Ford, S. J., Rehman, A., & Bradbury, A. W. (January 01, 2003). External iliac endofibrosis in endurance athletes: a novel case in an endurance runner and a review of the literature. *European Journal of Vascular and Endovascular Surgery: the Official Journal of the European Society for Vascular Surgery*, 26, 6, 629-34.
2. Giannoukas AD, Berczi V, Anoop U, *et al.* Endofibrosis of iliac arteries in high-performance athletes: diagnostic approach and minimally invasive endovascular treatment. *Cardiovasc Intervent Radiol*, 29 (2006), pp. 866-869.
3. Wilson TD, Revesz E, Podbielski FJ, Blecha MJ. External iliac artery dissection secondary to endofibrosis in a cyclist. *J Vasc Surg* 2010;52(1):219-21.
4. Bellas, N., Gillis E., Kincaid, B., Bilateral External Iliac Artery Endofibrosis. Radiology Online 2020. University of Connecticut Health.