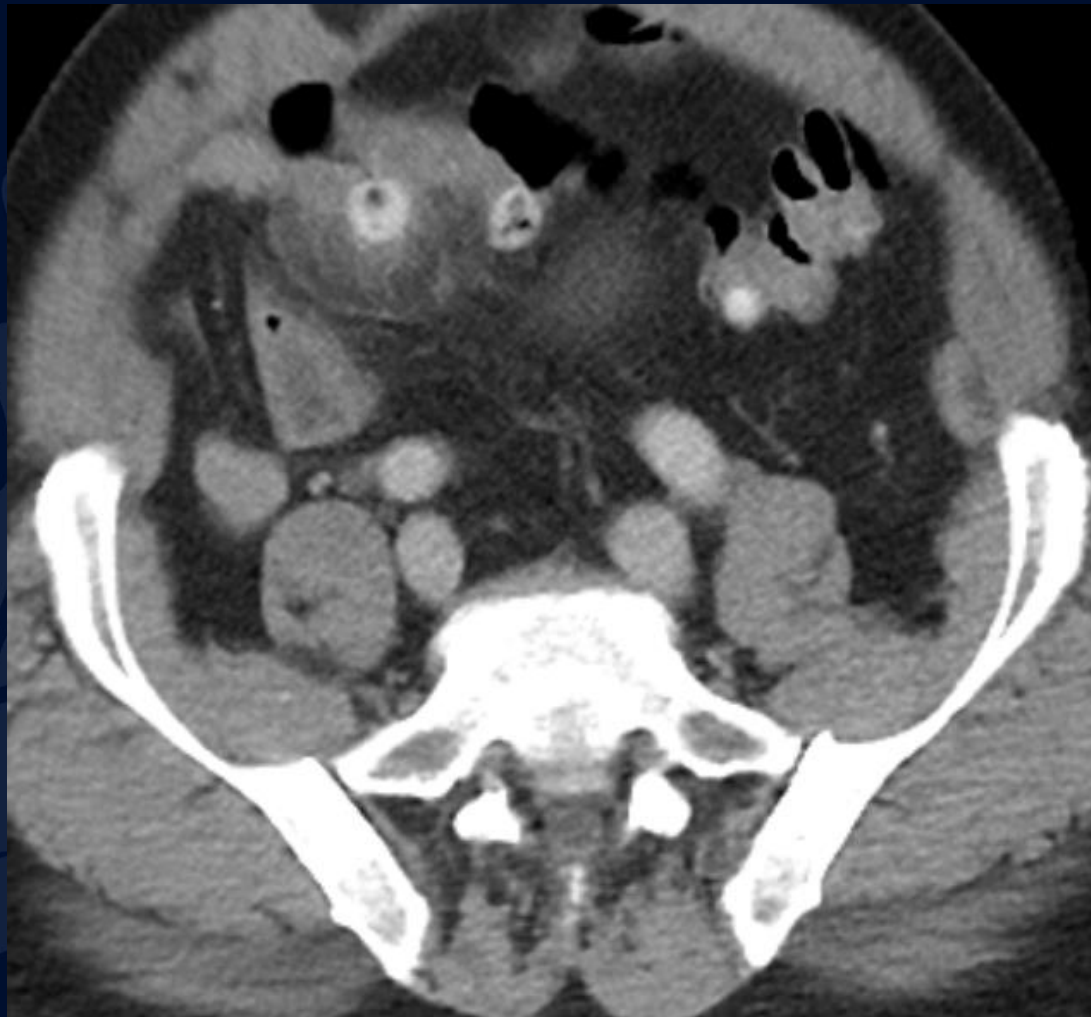
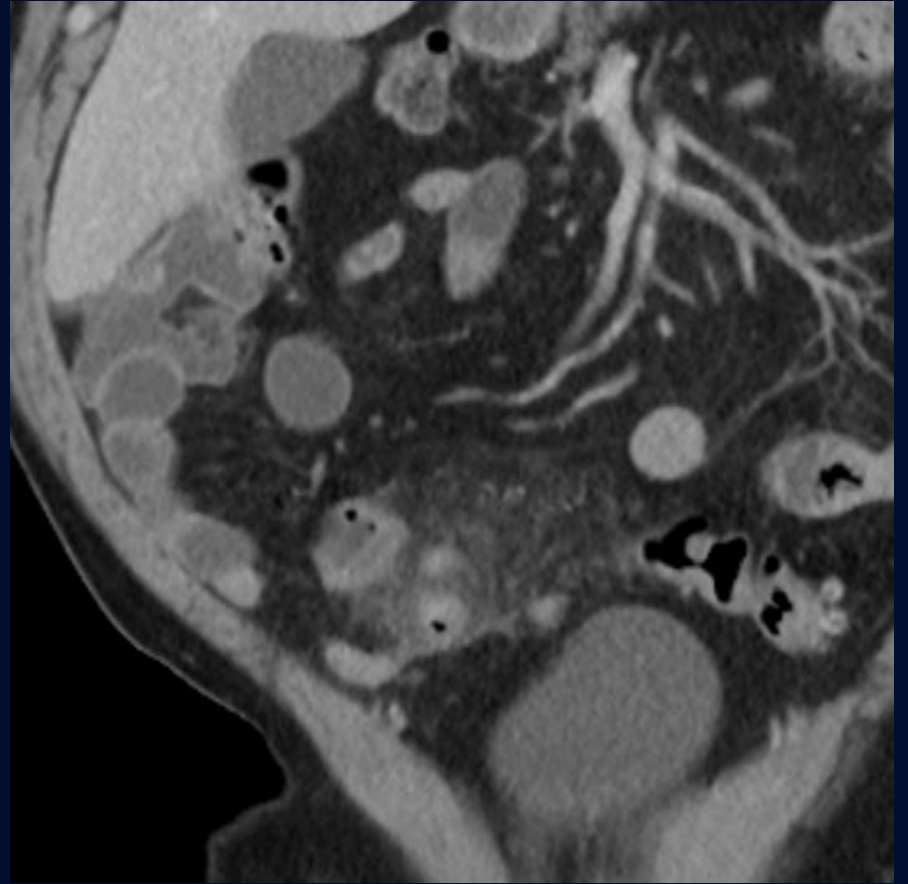
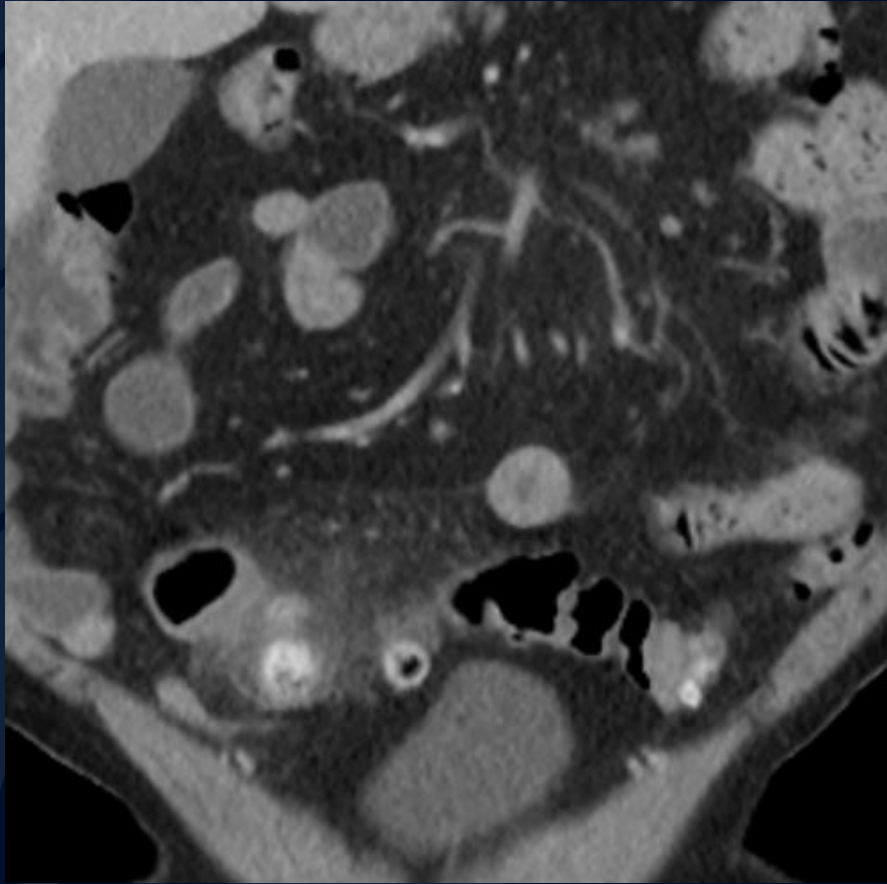


66-year-old male with fever and bilateral lower quadrant abdominal pain

Joseph Ryan, MS4
Edward Gillis, MD
David Karimeddini, MD



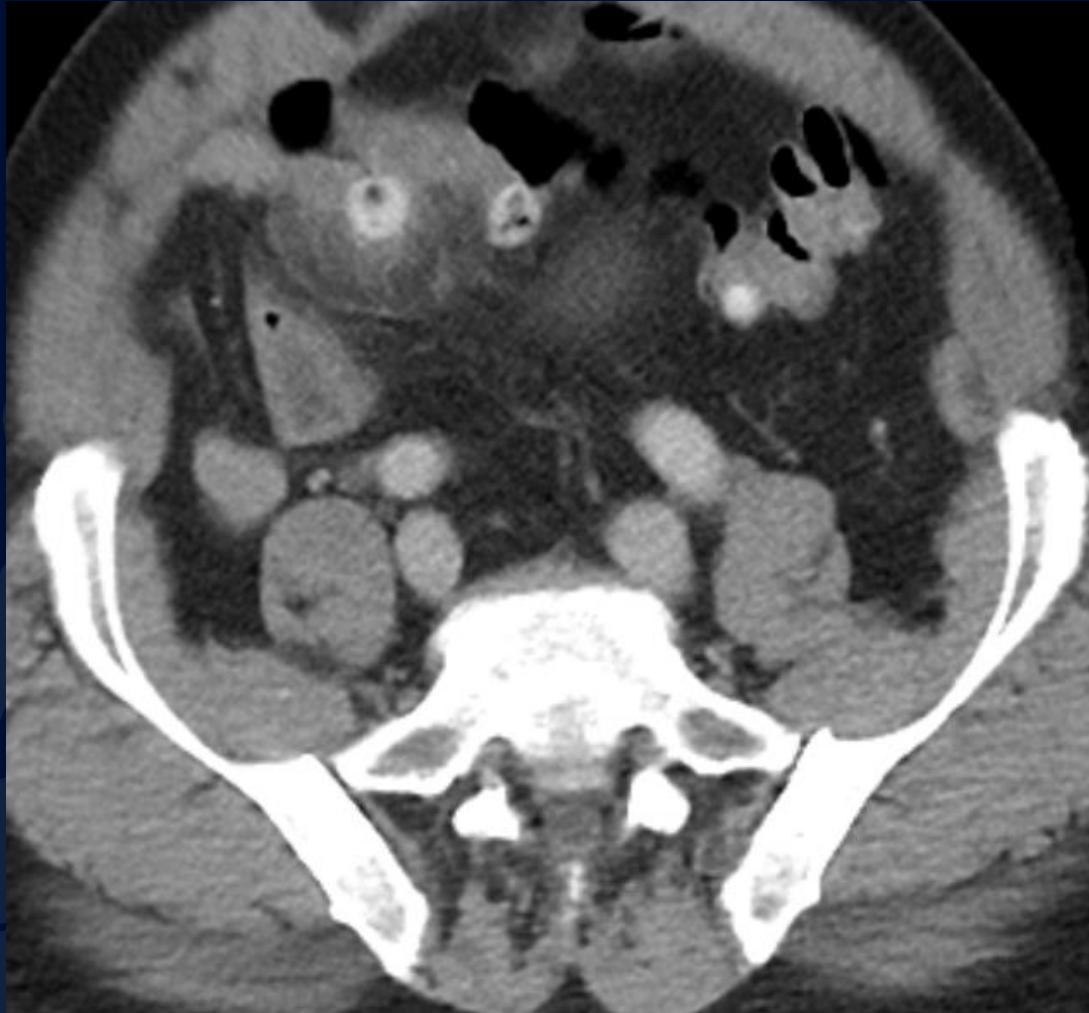

A large, stylized oak leaf graphic in a dark blue color, positioned on the left side of the slide. It features detailed vein patterns and a lobed edge.

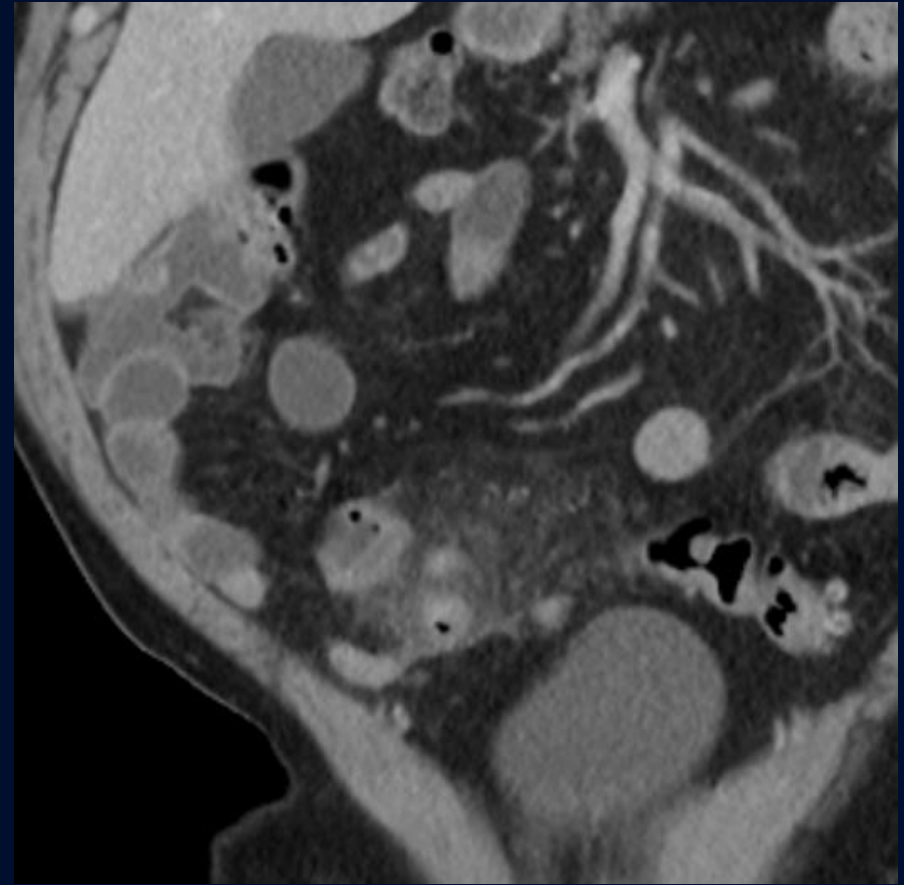
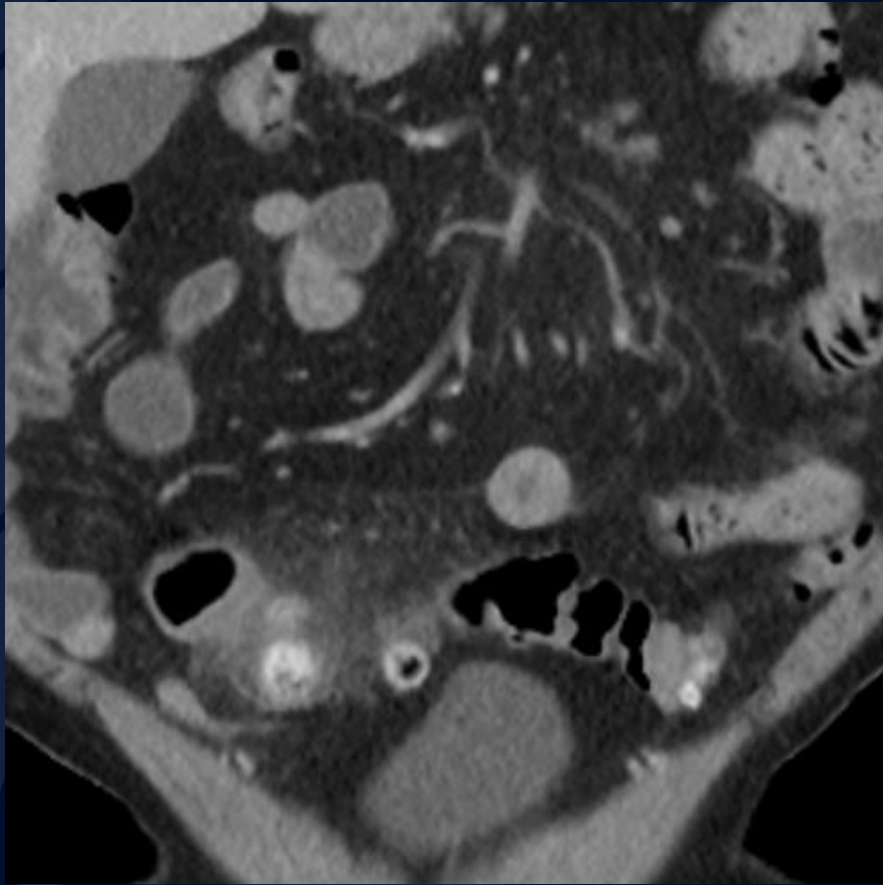
?



Acute sigmoid colon diverticulitis



Axial CECT image shows inflamed sigmoid colon diverticula with adjacent stranding and edema.



Coronal CECT images demonstrating inflamed sigmoid colon diverticula with adjacent stranding and edema.

Background

- Colonic diverticula are sac-like protrusions of the colon wall
 - mucosa pushing through muscular layer defects (as opposed to outpouching of all layers)
 - Associated with increased intraluminal pressures
- Diverticulosis describes the presence of multiple diverticula
 - Predominantly left-sided in the Western hemisphere
 - Prevalence rates of 5 to 45%; most commonly seen in elderly
- Diverticulitis is inflammation in the setting of diverticulosis, usually due to fecalith obstruction and infection leading to micro- or macro-perforation of a diverticulum
 - Occurs in ~4% of patients with diverticulosis
 - Acute complications occur in ~25% of patients
 - Complications can include bowel obstruction, abscess formation, peritonitis and fistula formation

Diagnosis

- Patients typically present with lower abdominal pain and tenderness
 - Left-sided in ~85% of cases; often gradually becomes more generalized
 - Symptoms resemble “left-sided appendicitis”
 - Other symptoms can include fever, nausea, vomiting, constipation and diarrhea
 - Peritoneal signs and palpable mass (“inflammatory phlegmon”) may be present
 - May have a mild leukocytosis (~55%)
- CT is the imaging modality of choice
 - Will show presence of diverticula and any associated inflammation
 - Can also help differentiate uncomplicated vs complicated diverticulitis
 - Specific findings for *uncomplicated* diverticulitis:
 - Bowel wall thickening
 - Fat stranding adjacent to diverticula
 - Extraluminal fluid
 - Specific findings for *complicated* diverticulitis:
 - Intrapertitoneal free air/fluid indicating perforation
 - Abscess
 - Fistula formation

Management

- Treatment can be medical or surgical, depending on severity
- Uncomplicated diverticulitis is typically treated medically
 - IV fluids, antibiotics, pain medications and NPO
 - Clinical improvements after 2-3 days
 - Antibiotics are typically continued for 7-14 days
 - Patients without recurrence should have colonoscopy to rule out cancer
 - Patients with persistent symptoms should have surgical eval
 - 16-42% of medically managed patients will develop recurrent diverticulitis, and overall 15-20% will require surgery at some point
- Surgical approaches depend on degree of perforation and peritoneal contamination, hemodynamic stability and surgeon preference
 - Stable patients should have the involved colonic segment(s) resected
 - Unstable patients may require limited resection and/or abscess drainage
 - Primary anastomosis with or without protective ostomy for localized perforations
 - Larger perforations may require a Hartmann's procedure

References

- 1) <https://radiopaedia.org/articles/diverticulitis?lang=us>
- 2) Pemberton JH. Colonic diverticulosis and diverticular disease: Epidemiology, risk factors, and pathogenesis. Friedman LS and Grover S, ed. UpToDate. Waltham, MA: UpToDate Inc. <https://www.uptodate.com> (Accessed on 5/14/19)
- 3) Pemberton JH. Clinical manifestations and diagnosis of acute diverticulitis in adults. Lamont JT and Grover S, ed. UpToDate. Waltham, MA: UpToDate Inc. <https://www.uptodate.com> (Accessed on 5/14/19)
- 4) Pemberton JH. Acute colonic diverticulitis: Medical management. Weiser M and Chen W, ed. UpToDate. Waltham, MA: UpToDate Inc. <https://www.uptodate.com> (Accessed on 5/14/19)
- 5) Pemberton JH. Acute colonic diverticulitis: Surgical management. Weiser M and Chen W, ed. UpToDate. Waltham, MA: UpToDate Inc. <https://www.uptodate.com> (Accessed on 5/14/19)