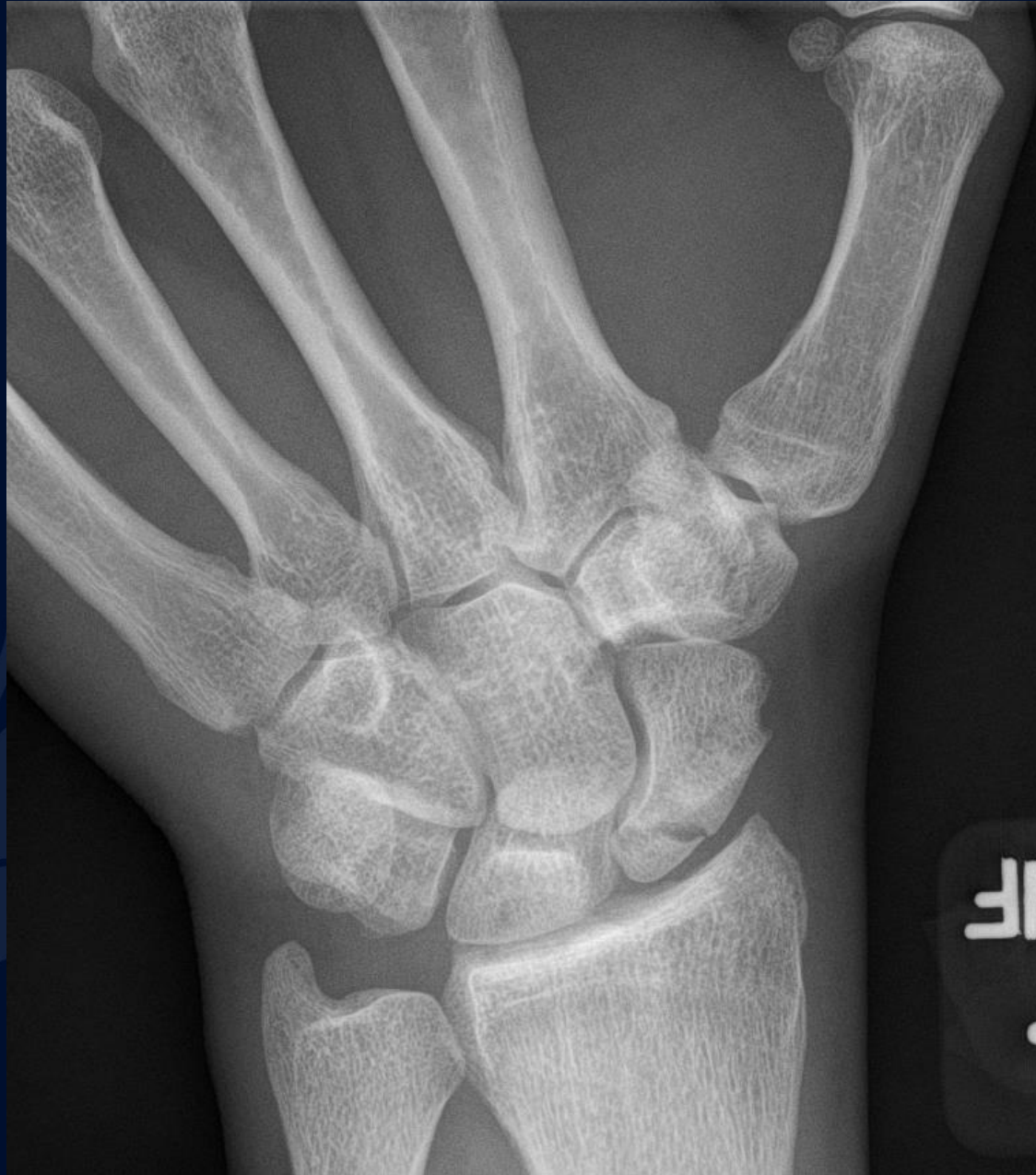

# 30 y/o male with acute left wrist pain

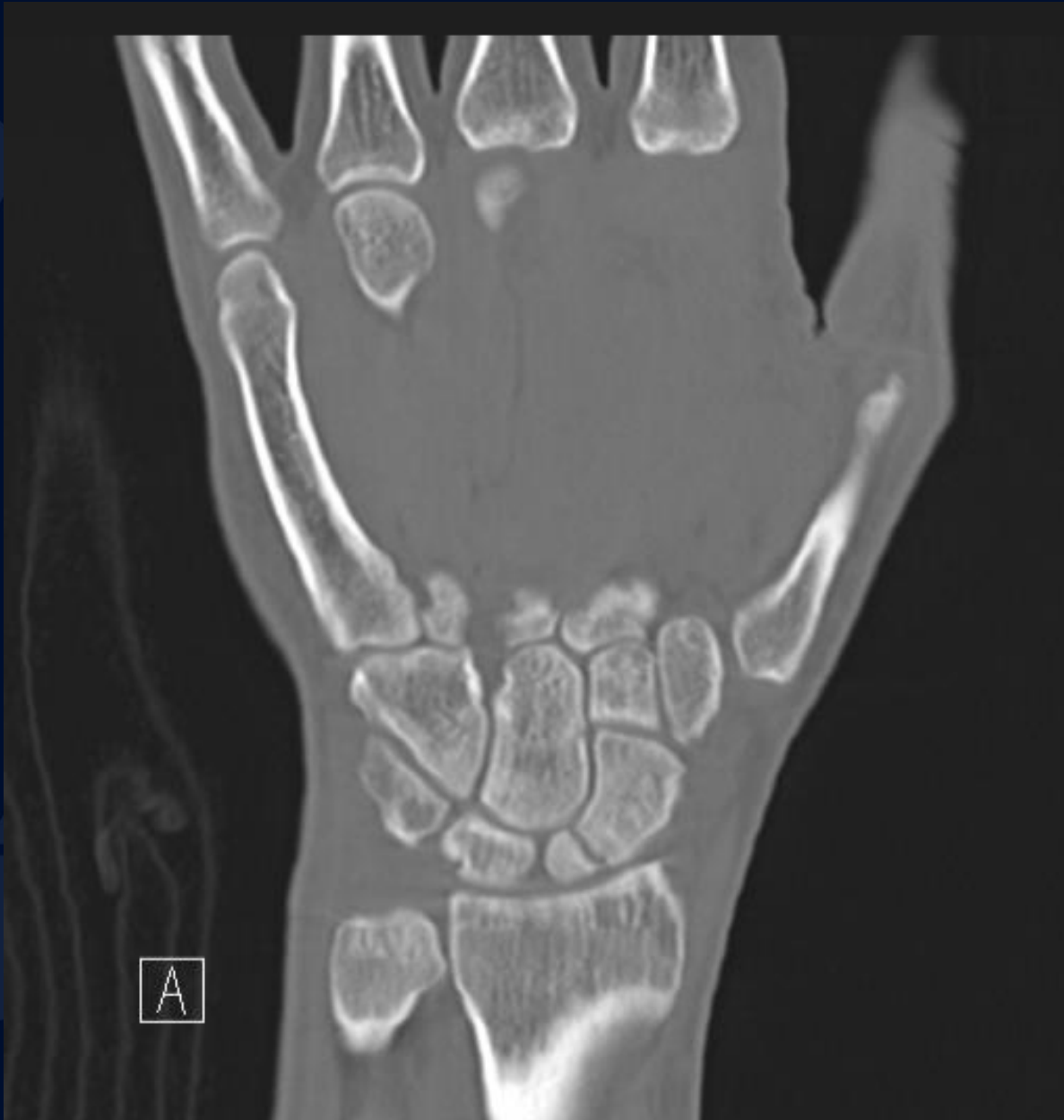Student Name....None was listed

Atul Kumar, MD, MS

# PA Radiograph



# Non Contrast Coronal CT

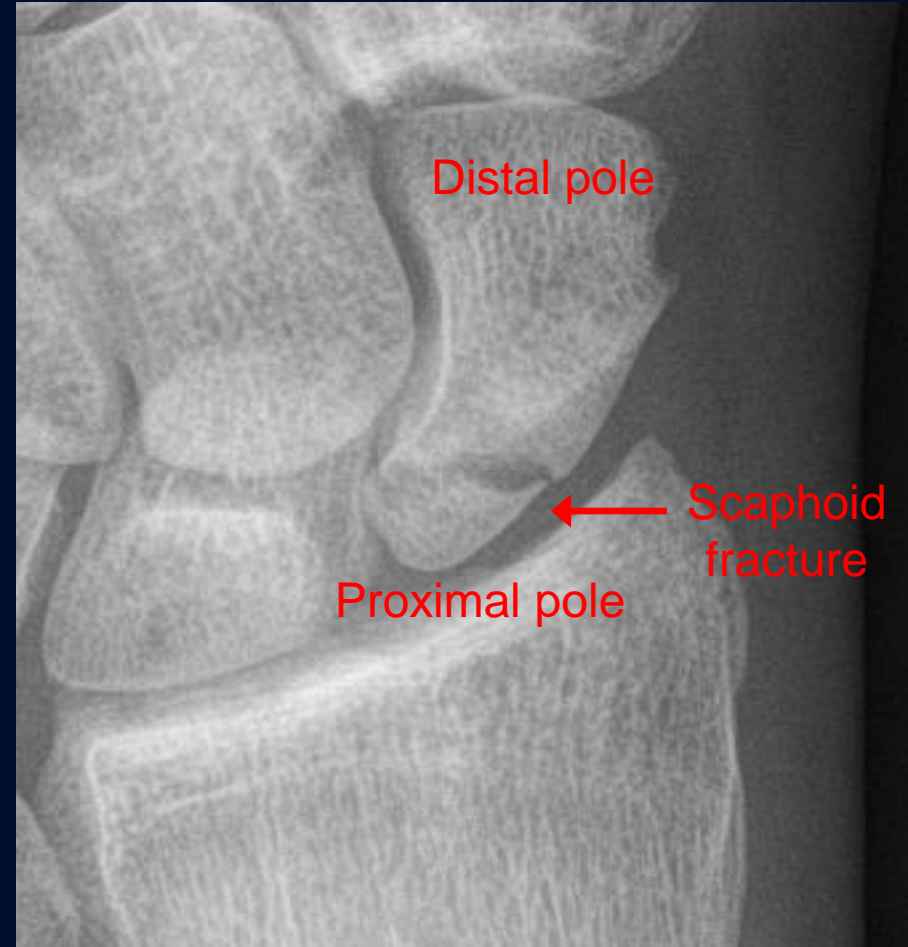
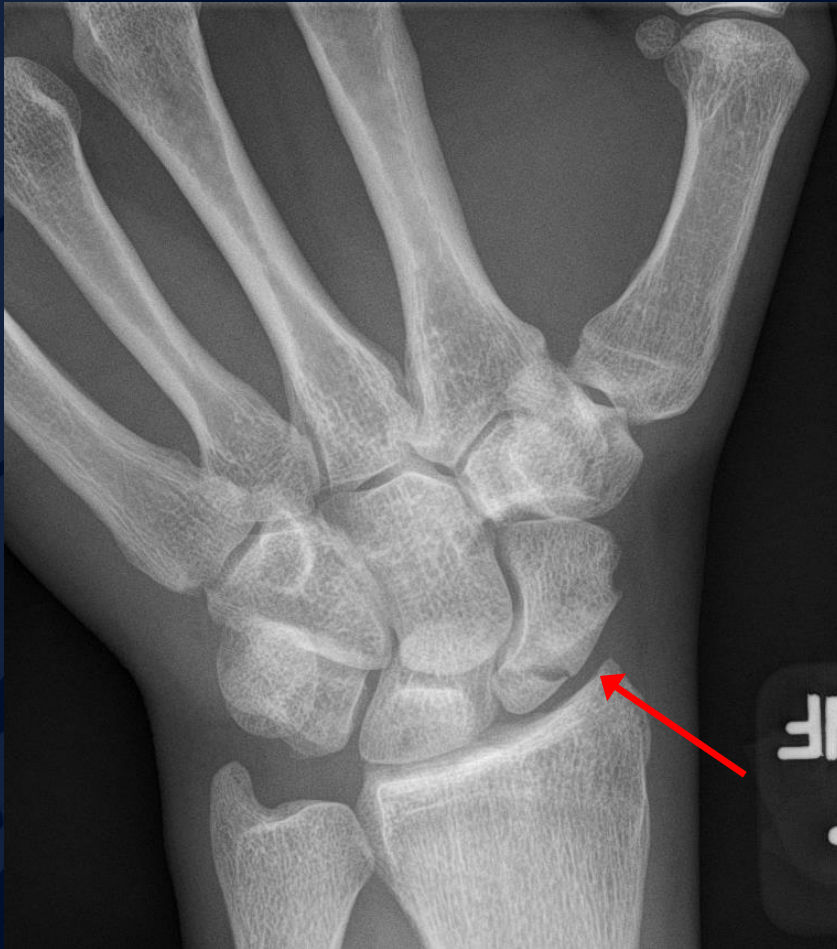
A large, stylized oak leaf graphic in a dark blue color, positioned on the left side of the slide. It features detailed vein patterns and a lobed edge.

?

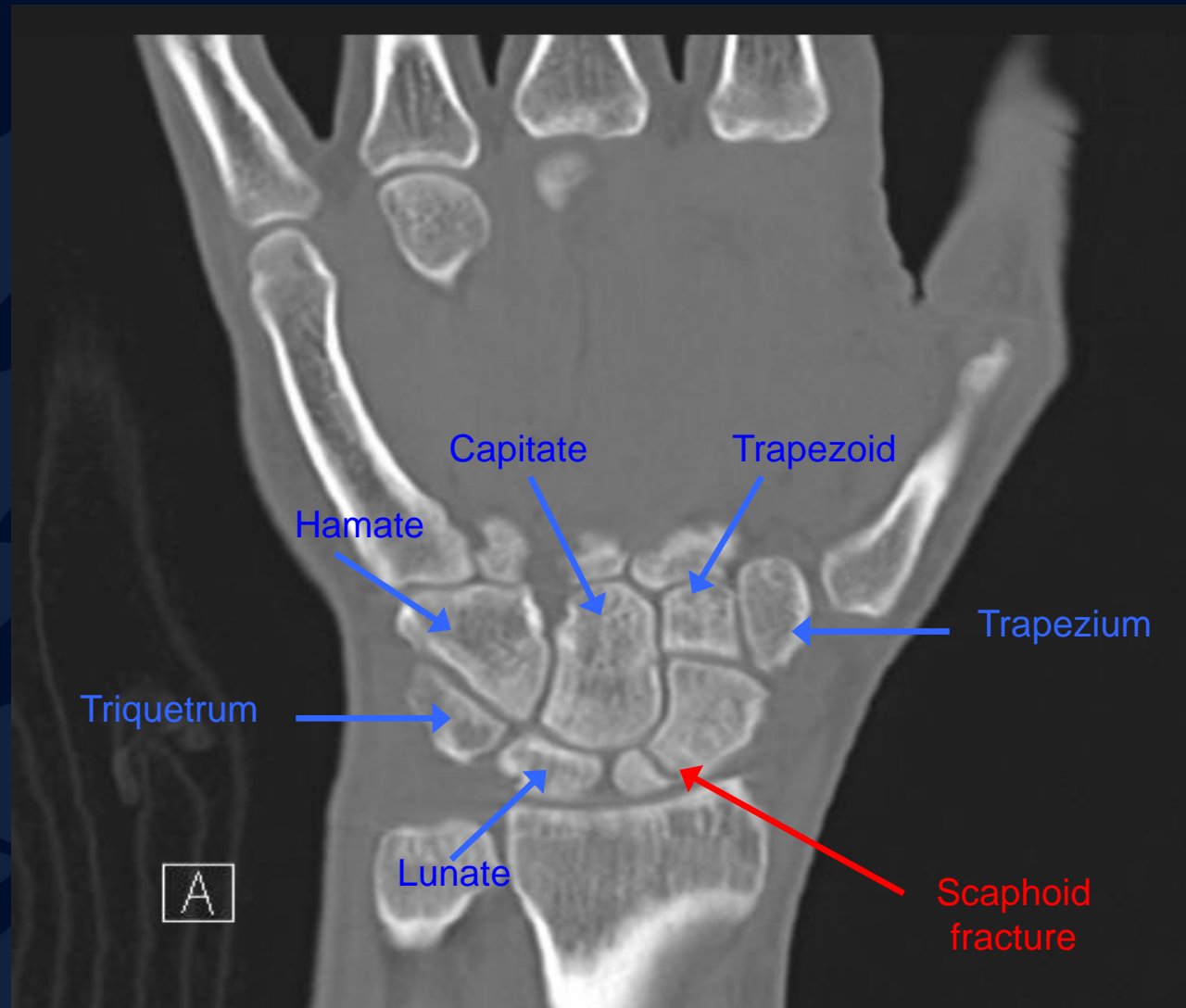
# Scaphoid Fracture

# PA radiograph



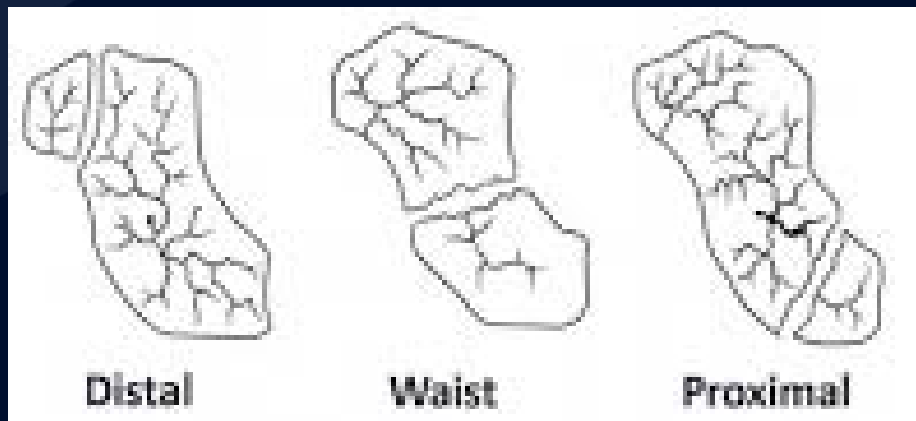
- PA x-ray showing transverse scaphoid fracture.

# Non Contrast Coronal CT



# Scaphoid Fracture

- Mechanism: direct axial compression or with hyperextension (fall onto an outstretched hand).
- Symptoms: pain localized at the radial aspect of wrist often associated with swelling and reduced grip strength.
  - Pain in anatomic snuffbox suspicious for waist fracture, which is the most common type.
- Because scaphoid fractures are often radiologically occult, any tenderness in the anatomic snuffbox should be treated as a scaphoid fracture.
- Scaphoid blood supply (palmar carpal branch of the radial artery) runs from the distal to the proximal pole. Transverse fracture of the proximal pole can lead to osteonecrosis and nonunion due to disruption of blood flow.

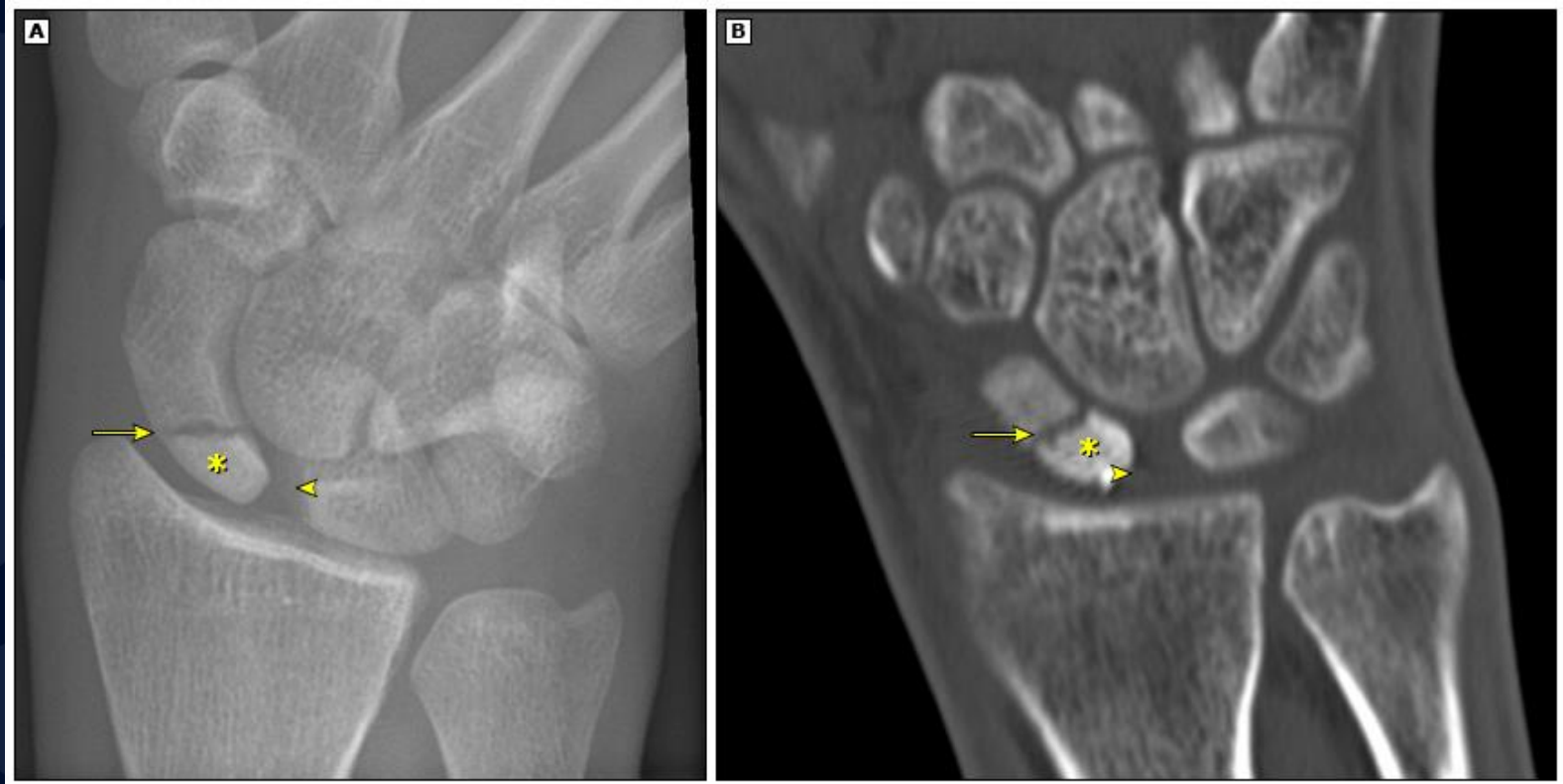



# Scaphoid Fracture

- Differential diagnosis: distal radius fracture, wrist sprain, and other carpal injuries other than scaphoid.
- In suspected scaphoid fractures, plain radiographs (including PA, true lateral, oblique, and scaphoid views) are ordered as the first diagnostic step.
- However, the false negative rate for radiographs taken immediately after injury up to 20-54%.
- Definitive diagnosis can be made by MRI or CT scan. They have a comparable diagnostic accuracy and do not result in overtreatments.

# Avascular necrosis/Nonunion



Scaphoid view radiograph (A) and CT scan (B) showing nonunion (arrow) and avascular necrosis (asterisk) and the Terry Thomas sign – scapholunate ligament injury (arrowhead).

# Reference

- deWeber K. Scaphoid fractures. Uptodate, accessed on 11/19/2018.  
[https://www.uptodate.com/contents/scaphoid-fractures?search=scaphoid%20fracture&source=search\\_result&selectedTitle=1~26&usage\\_type=default&display\\_rank=1#H1510267](https://www.uptodate.com/contents/scaphoid-fractures?search=scaphoid%20fracture&source=search_result&selectedTitle=1~26&usage_type=default&display_rank=1#H1510267)
- Taljanovic, Mihra, et al. “Imaging and Treatment of Scaphoid Fractures and Their Complications.” *Seminars in Musculoskeletal Radiology*, vol. 16, no. 02, 2012, pp. 159–174., doi:10.1055/s-0032-1311767.