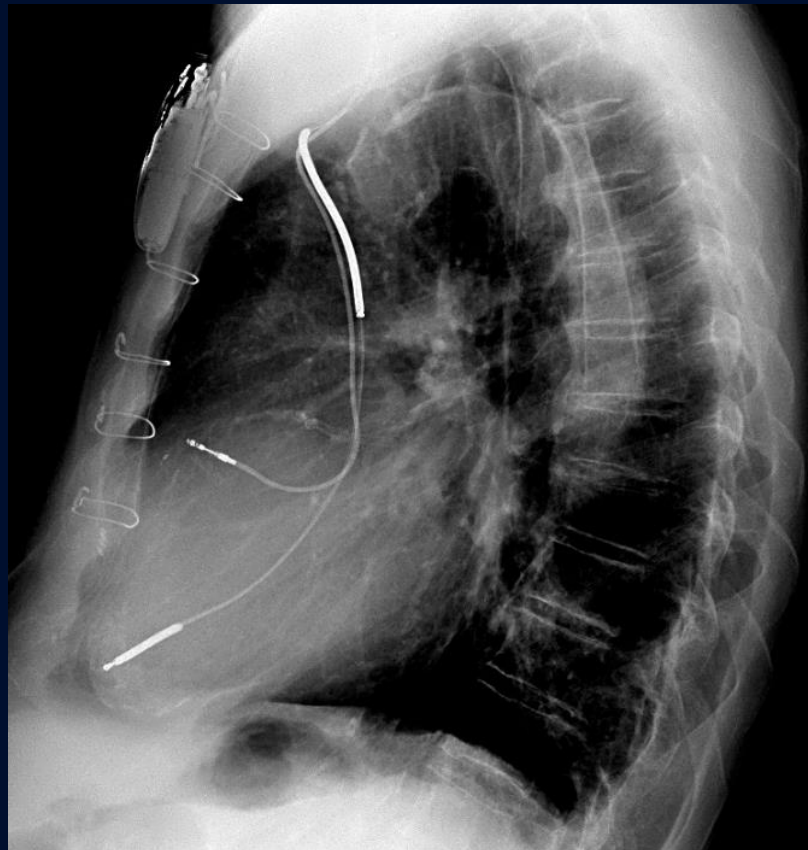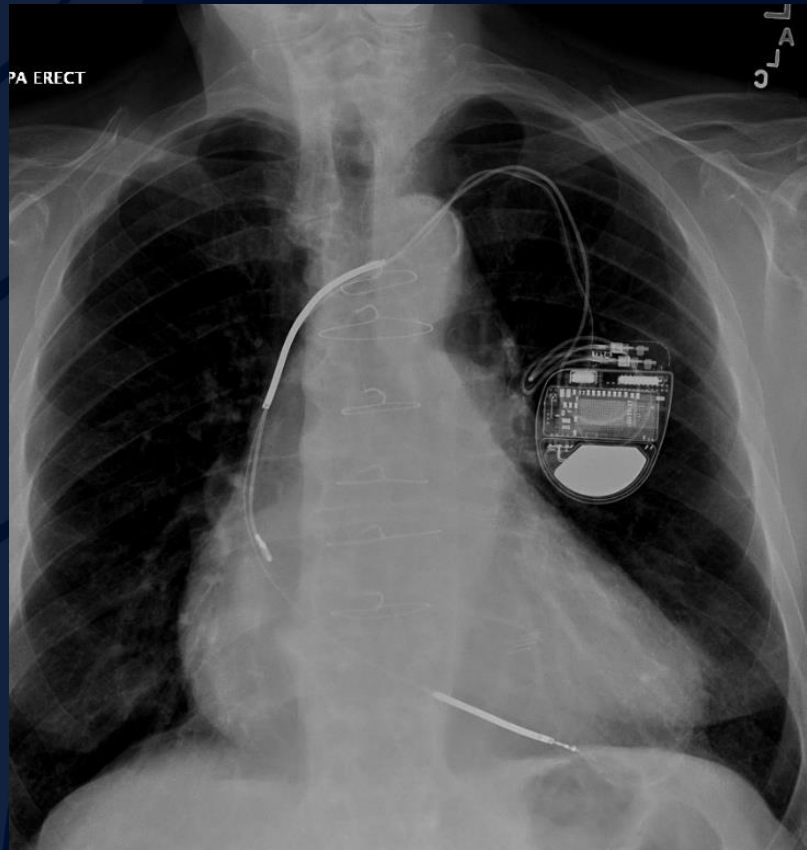
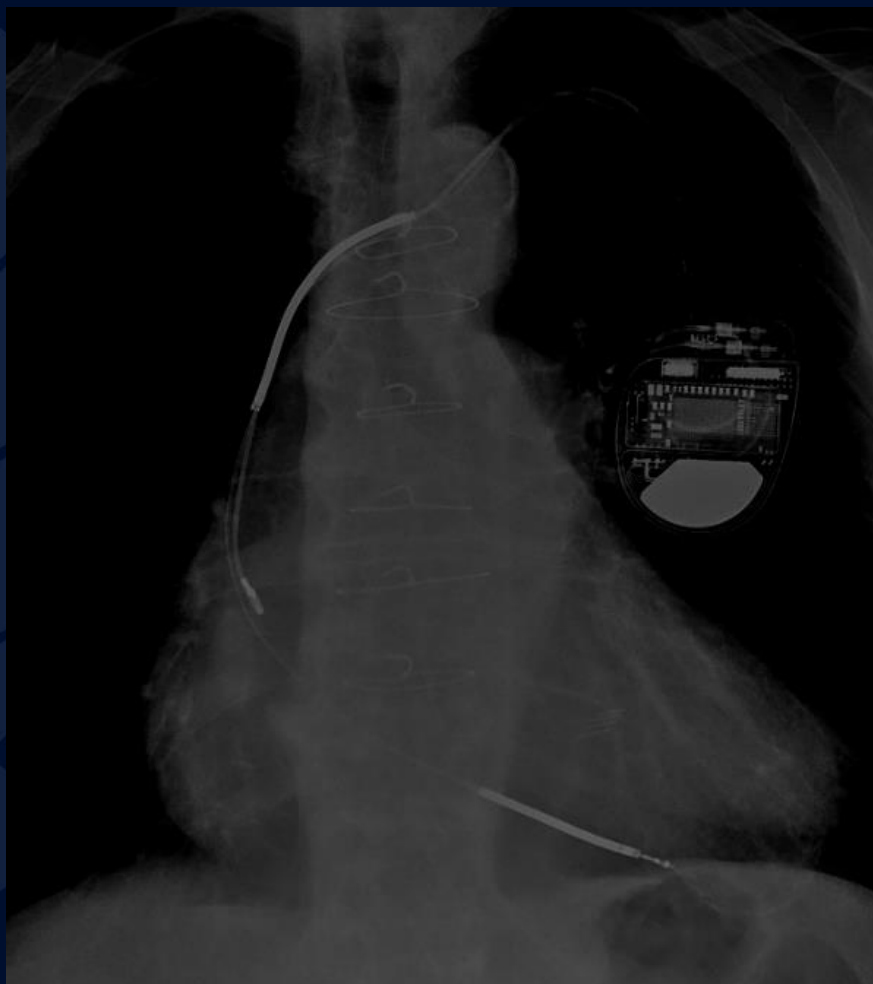


83 year old male with cough  
and chest pain.

Edward Gillis, DO



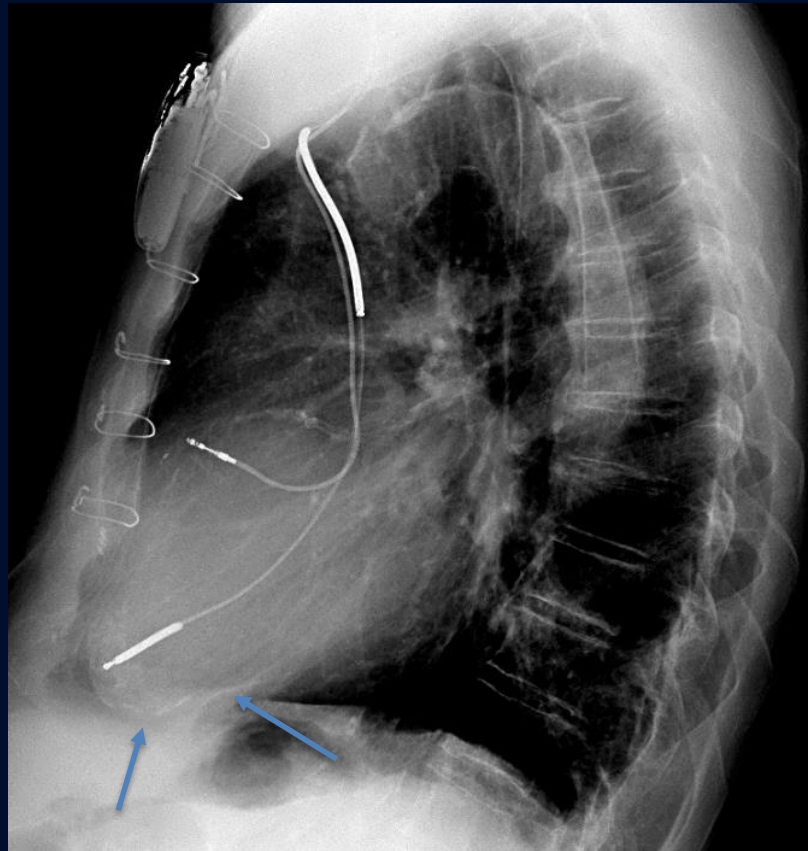
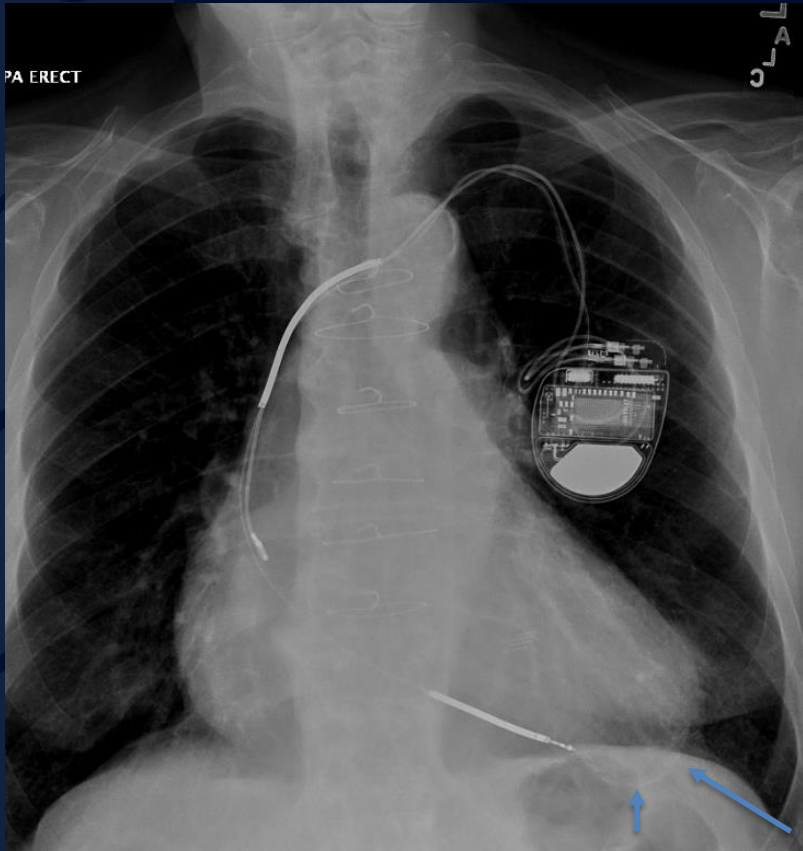


A large, stylized oak leaf graphic in a dark blue color, positioned on the left side of the slide. The leaf has a prominent central vein and several smaller veins branching off it. The leaf's edge is serrated.

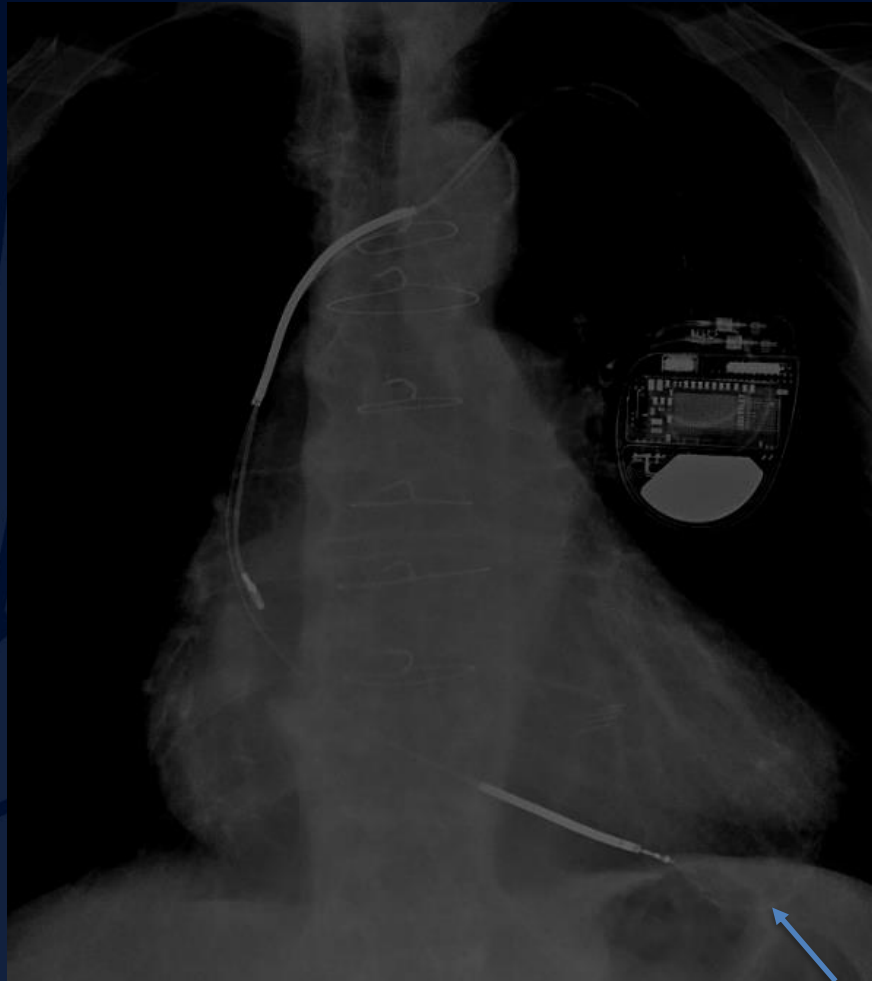
?

A large, stylized oak leaf graphic in a dark blue color, positioned on the left side of the slide. The leaf has a prominent central vein and several smaller veins branching off it. The background of the slide is a solid dark blue.

# Calcified Left Ventricular Aneurysm



PA and lateral views of the chest show a globally enlarged heart with a left chest wall ICD and median sternotomy wires. Faintly visible are curvilinear calcifications present along the apex of the left ventricle, compatible with calcified LV aneurysm after remote myocardial infarction.



PA radiograph windowed down more clearly shows the curvilinear calcifications along the LV apex.

# Calcified LV Aneurysm

## Imaging Features

- Calcifications along ventricular contour
- L > R ventricle
- Thin or thick calcifications that are curvilinear in orientation
- May see an abnormal, lobulated configuration of the ventricle
- CT
  - True aneurysm: Wide neck – generally along the apex or anterolateral wall
  - Pseudoaneurysm: Narrow neck – along the posterior, lateral, or diaphragmatic walls



# Calcified LV Aneurysm

## General Features

- True aneurysm – weakening of the ventricular myocardium after infarct resulting in a focal outpouching. Has a wide neck.
- Pseudoaneurysm – discontinuation of ventricular wall due to weakening after infarct. Rupture contained by epicardium or pericardium. Narrow aneurysmal neck compared to aneurysm sac.
- Calcification generally develops ~6 years post infarction
- Calcified infarction increases risk of sudden death
- Pseudoaneurysms are at increased risk of rupture due to defect in ventricular wall

# References

1. Gowda RM et al: Calcifications of the heart. Radiol Clin North Am. 42(3):603-17, vi-vii, 2004
2. Ferguson, E.C. et al: Cardiac and pericardial calcifications on chest radiographs. Clinical Radiology, 65(9):685-694, 2009