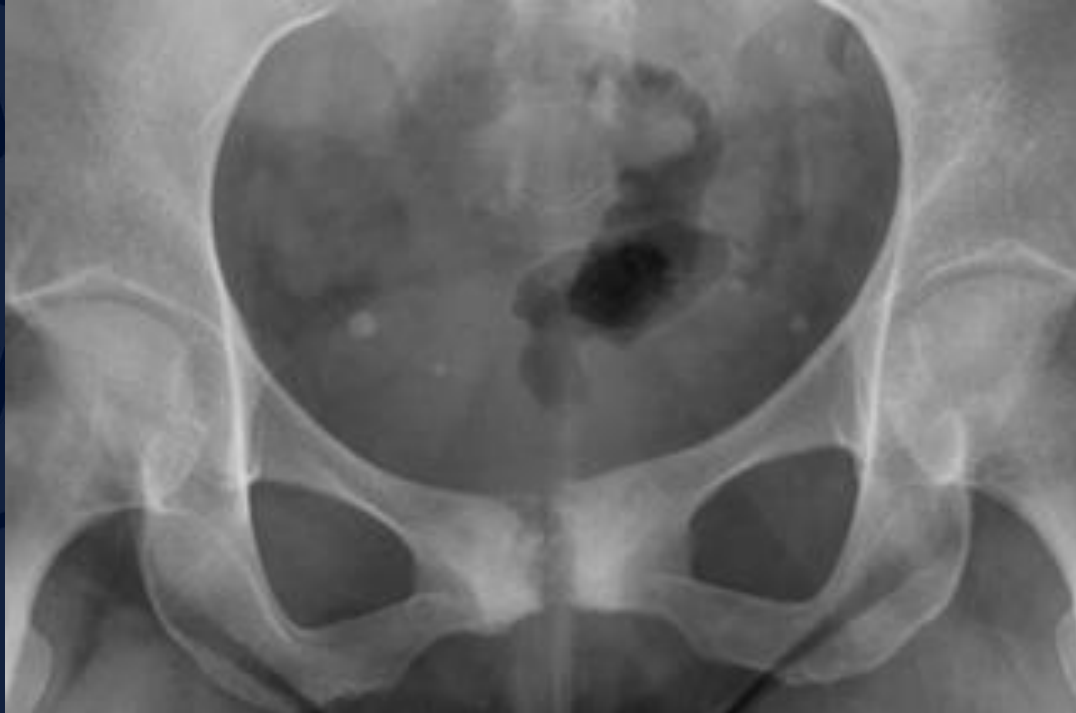

A large, stylized oak leaf graphic in a dark blue color, positioned on the left side of the slide, partially overlapping the main text area.

32 year old female runner with hip pain.

Allan Zhang DO
Daniel E. Marrero, MD



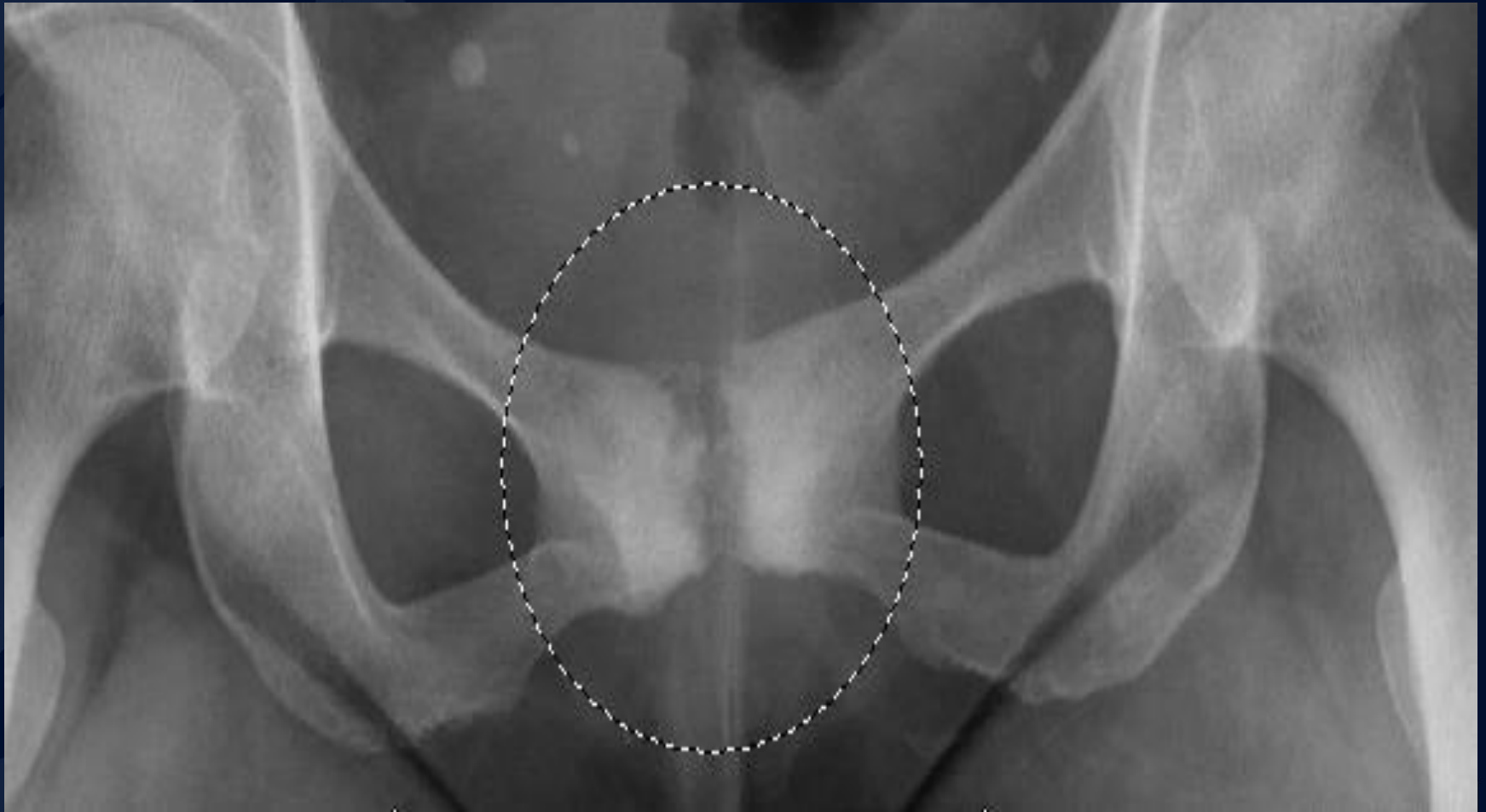


?

A large, stylized oak leaf graphic in a dark blue color, positioned on the left side of the slide. The leaf has a prominent central vein and several smaller veins branching off it. The leaf's edge is serrated.

Osteitis Pubis

Osteitis Pubis



Osteitis Pubis

- Presentation
 - Unilateral or bilateral groin pain, exacerbated by activity
 - Perineal pain with running
 - Decreased range of motion
- Demographics
 - Young athletic adults
 - Postpartum females of any age
 - Elderly osteoporotic adults
- Radiographic findings
 - Acute: radiographic occult
 - Subacute: subchondral resorption, sometimes unilateral, often asymmetric
 - Chronic: subchondral sclerosis, more prominent erosions

Osteitis Pubis

- Differentials

- Avulsion injury at pubis
- Stress fracture
- Osteomyelitis

- Treatment

- Cessation of activity/Conservative pain control
- Injection of steroids
- Surgical stabilization, only after all exhausted other conservative treatment

References

- Gibbon WW, Hession PR. Diseases of the pubis and pubic symphysis: MR imaging appearances. *AJR Am J Roentgenol.* 1997;169 (3): 849-53.
- Lentz SS. Osteitis pubis: a review. *Obstet Gynecol Surv.* 1995;50 (4): 310-5.