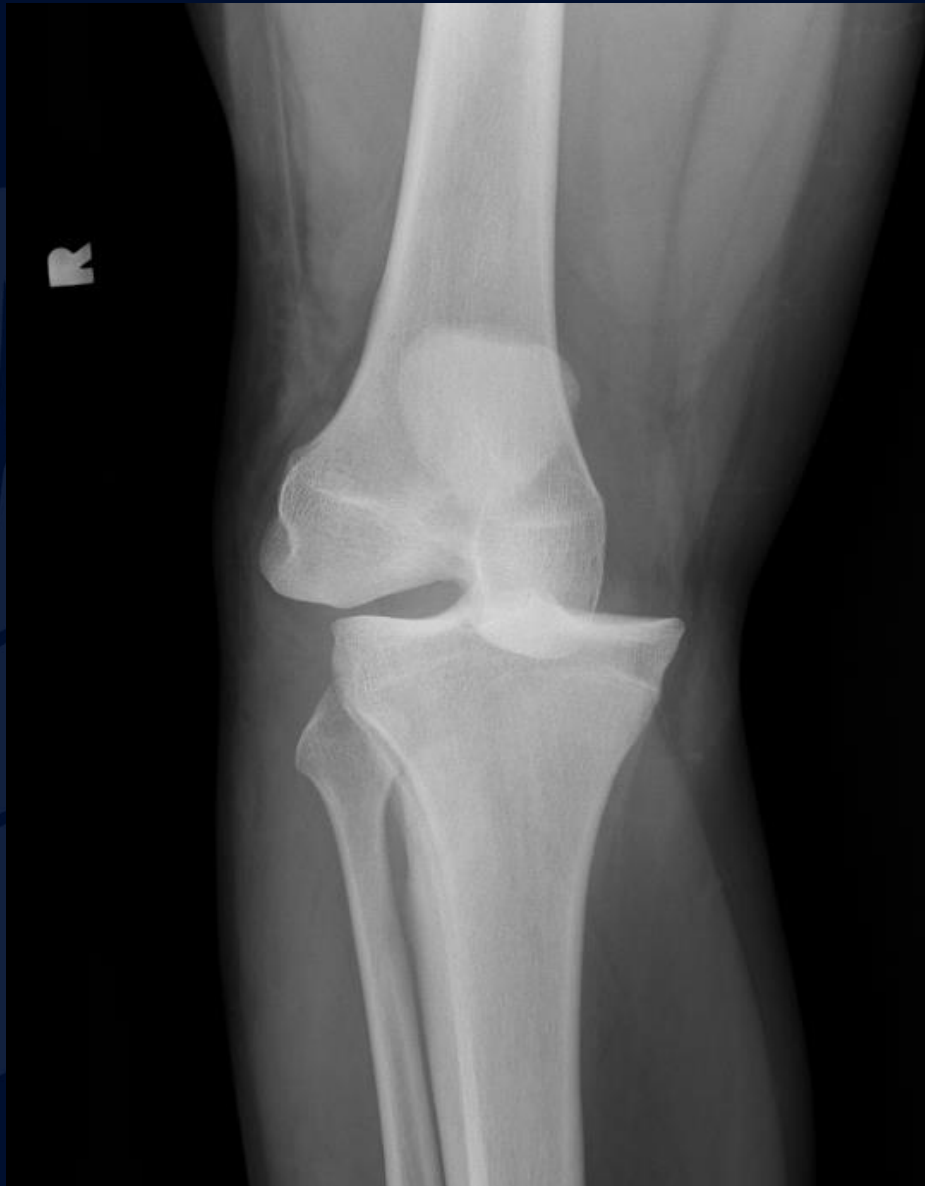
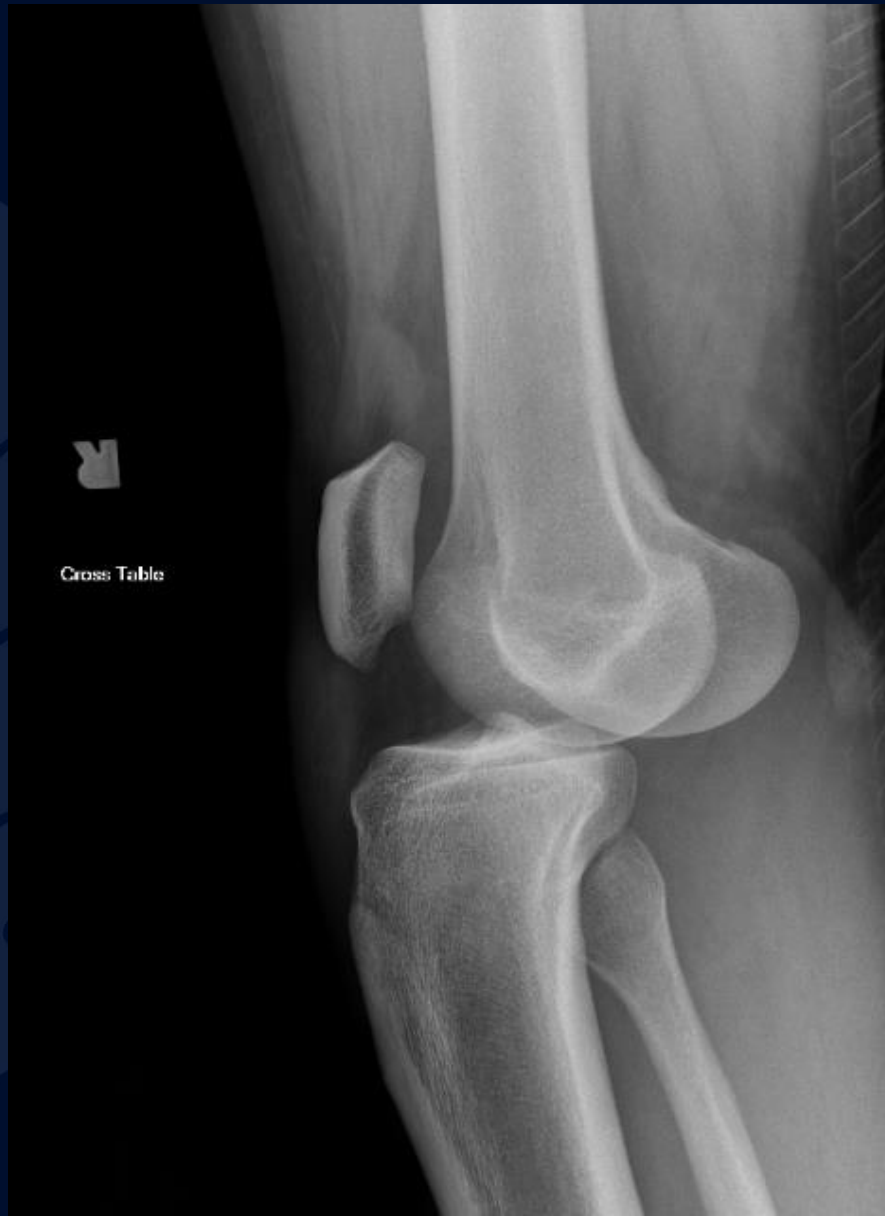
25 y/o M who presents with  
severe acute onset right knee  
pain after fall

Atul Kumar, MD, MS  
Daniel E. Marrero, MD



Frontal View R Knee



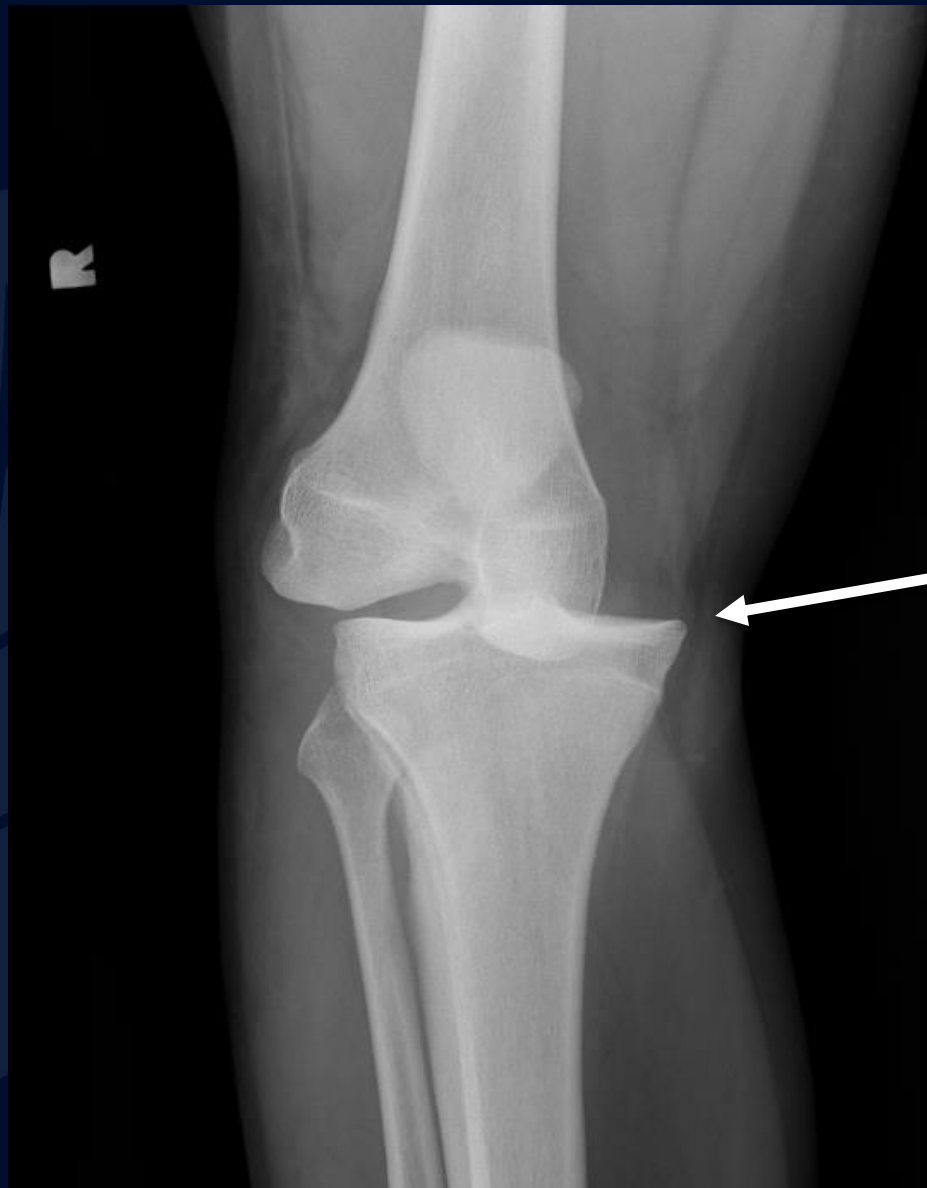
Lateral View R Knee

A large, stylized oak leaf graphic in a dark blue color, positioned on the left side of the slide. It features detailed vein patterns and a lobed edge.

?

# Right Anterior Tibial Dislocation

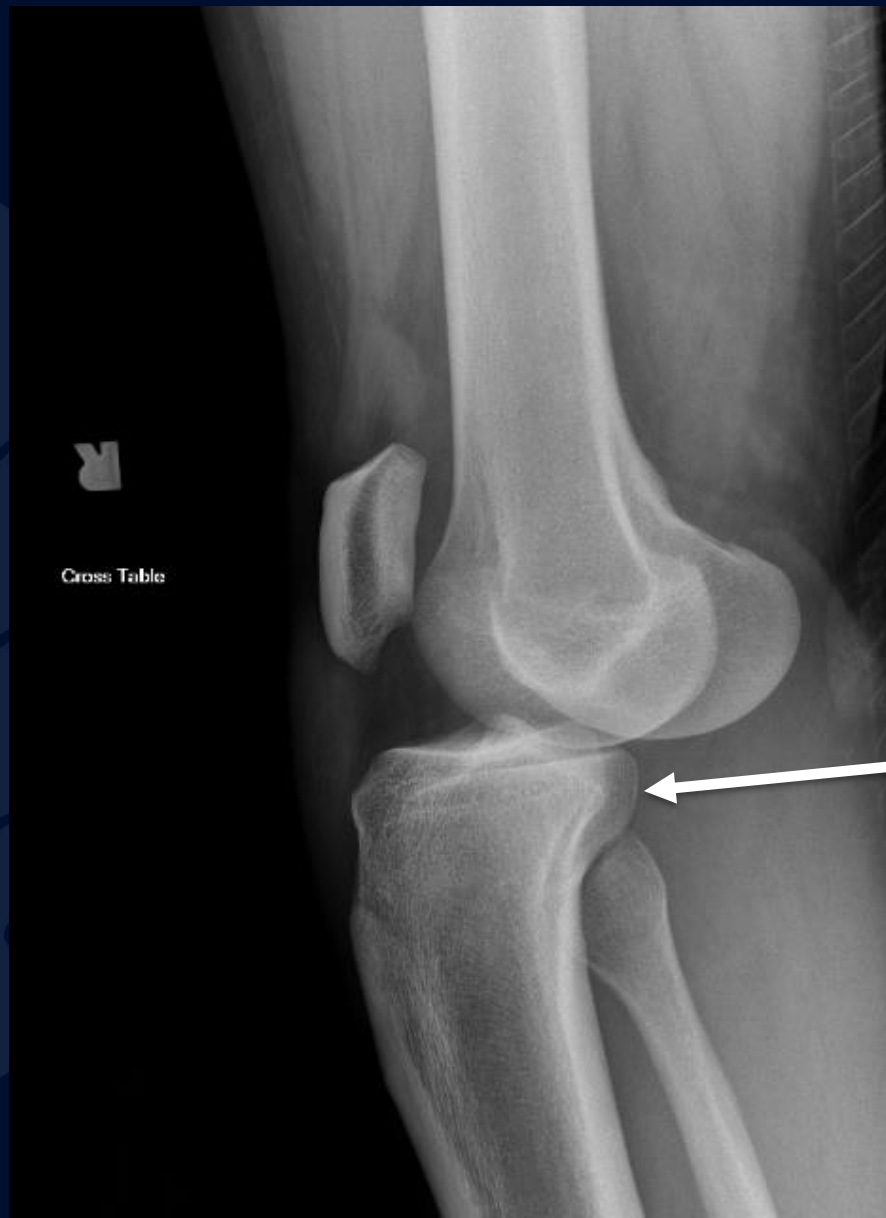
No acute fracture



Medial displacement of tibia in relation to femur

Frontal View R Knee

No acute fracture



Anterior displacement of tibia in relation to femur

Lateral View R Knee

# Knee Dislocation

- Rare, < 0.5% of joint dislocations
- Can be seen with both high (MVA) and low (sports injury) energy trauma
- Often associated with
  - Fracture
  - Ligamentous injury
    - ACL disruption 100% of the time
  - Meniscal tear
  - Vascular injury
    - Evaluate for popliteal artery injury with **CT or MR Angiogram**
  - Peroneal nerve injury



# References

- Walker RE, McDougall D, Patel S et-al. Radiologic review of knee dislocation: from diagnosis to repair. AJR Am J Roentgenol. 2013;201 (3): 483-95. [doi:10.2214/AJR.12.10221](https://doi.org/10.2214/AJR.12.10221)