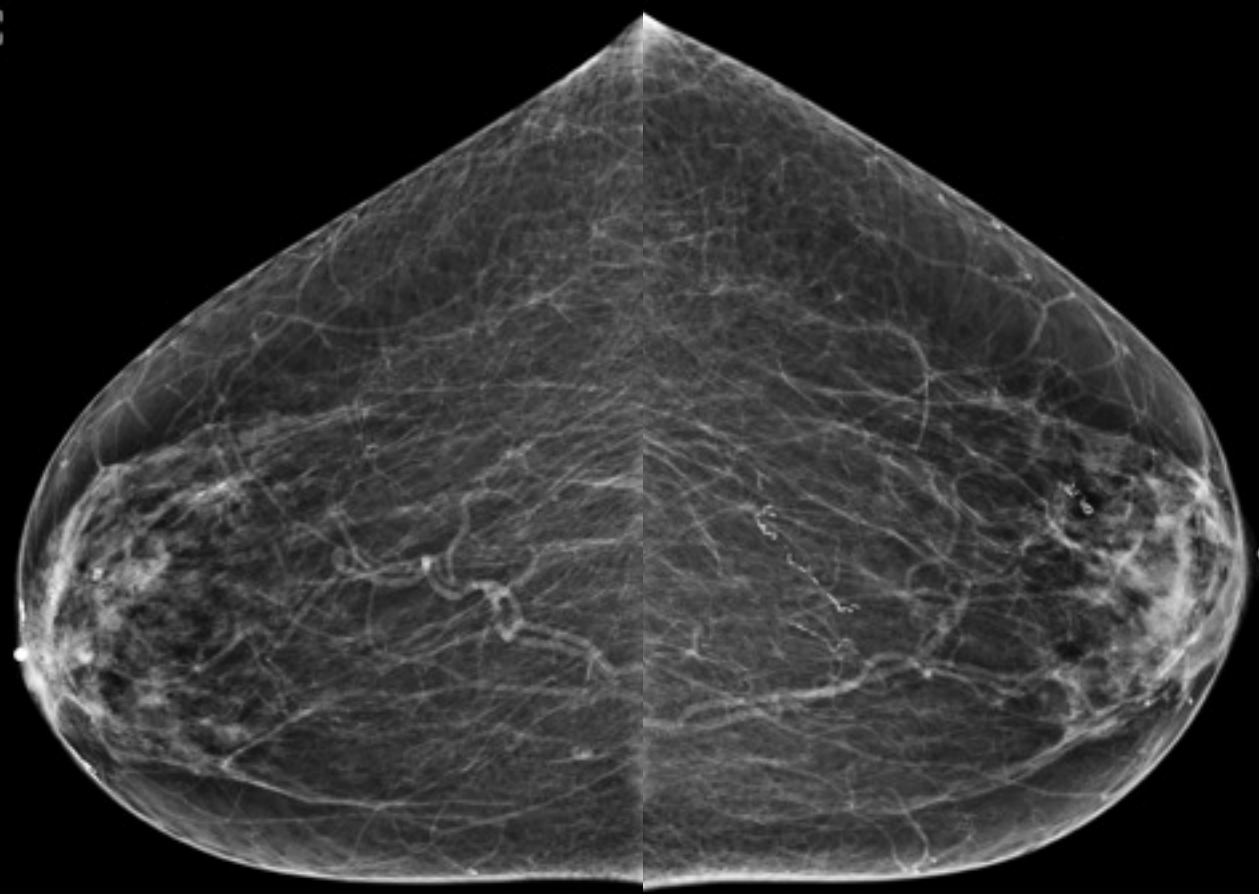


62 year old female of African descent
presents for routine screening mammogram

John A. Cieslak III, MD, PhD
Basil Hubbi, MD
Rutgers NJMS

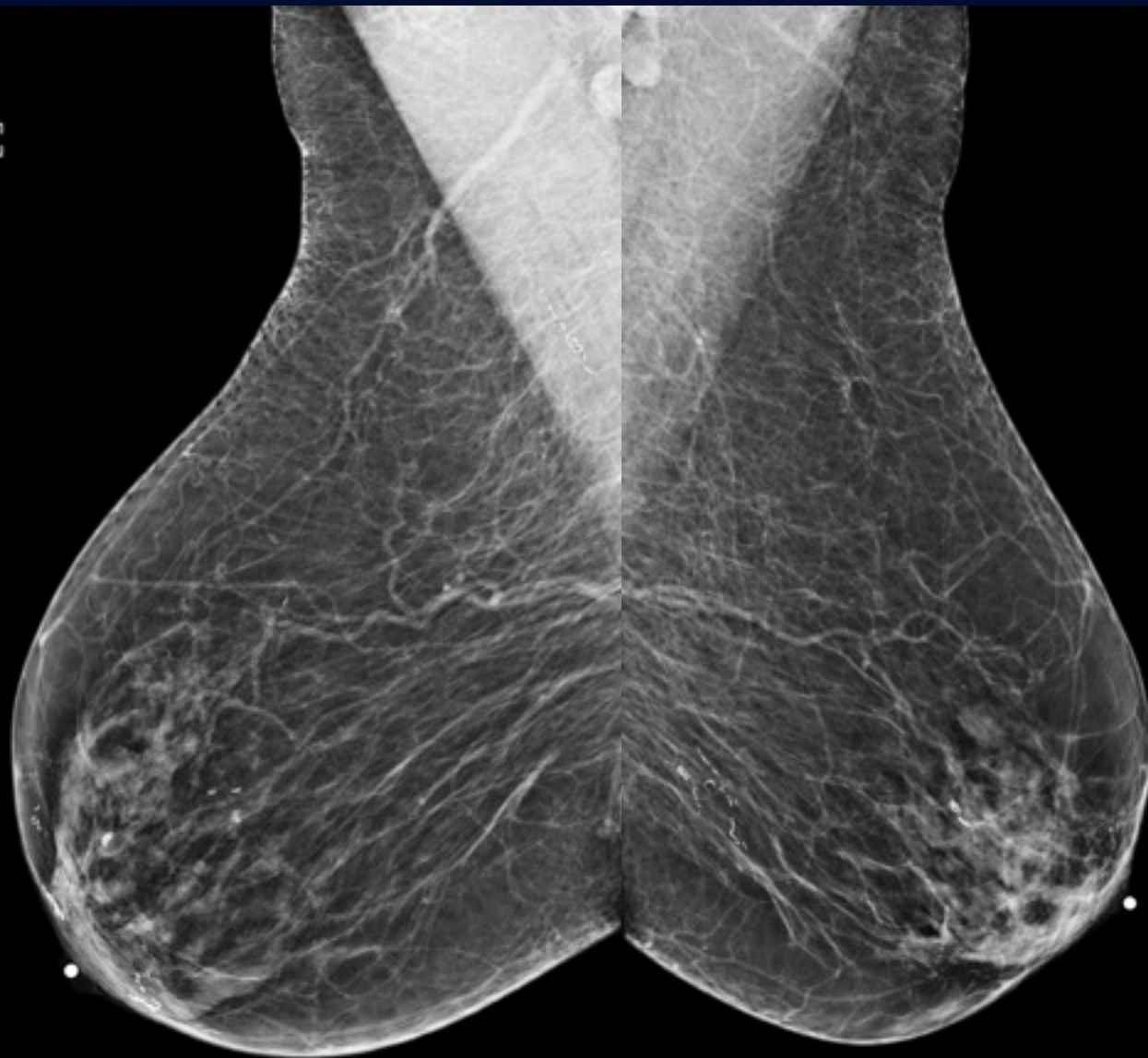RCC

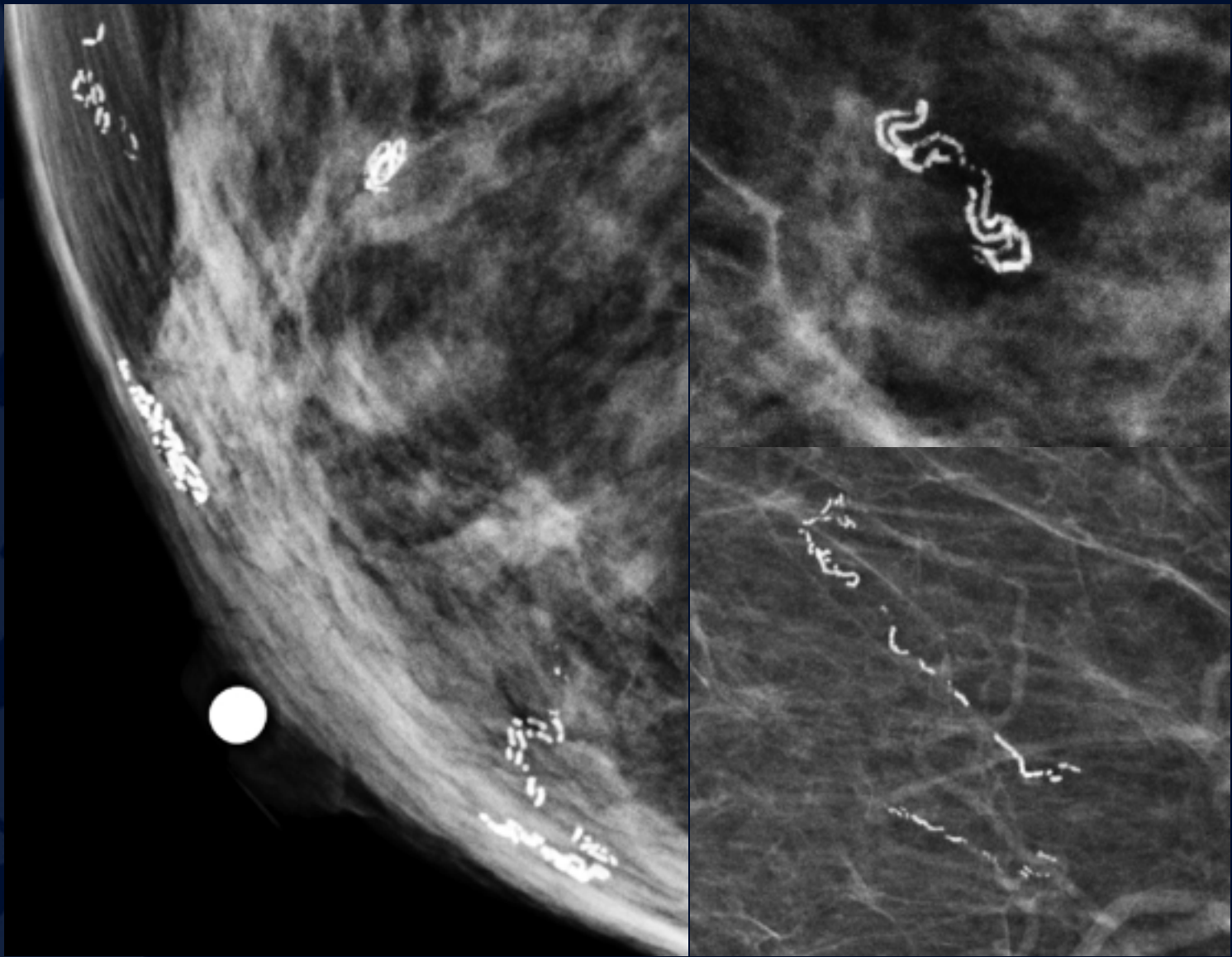
LCC



[R] RMLO

[L] LMLO





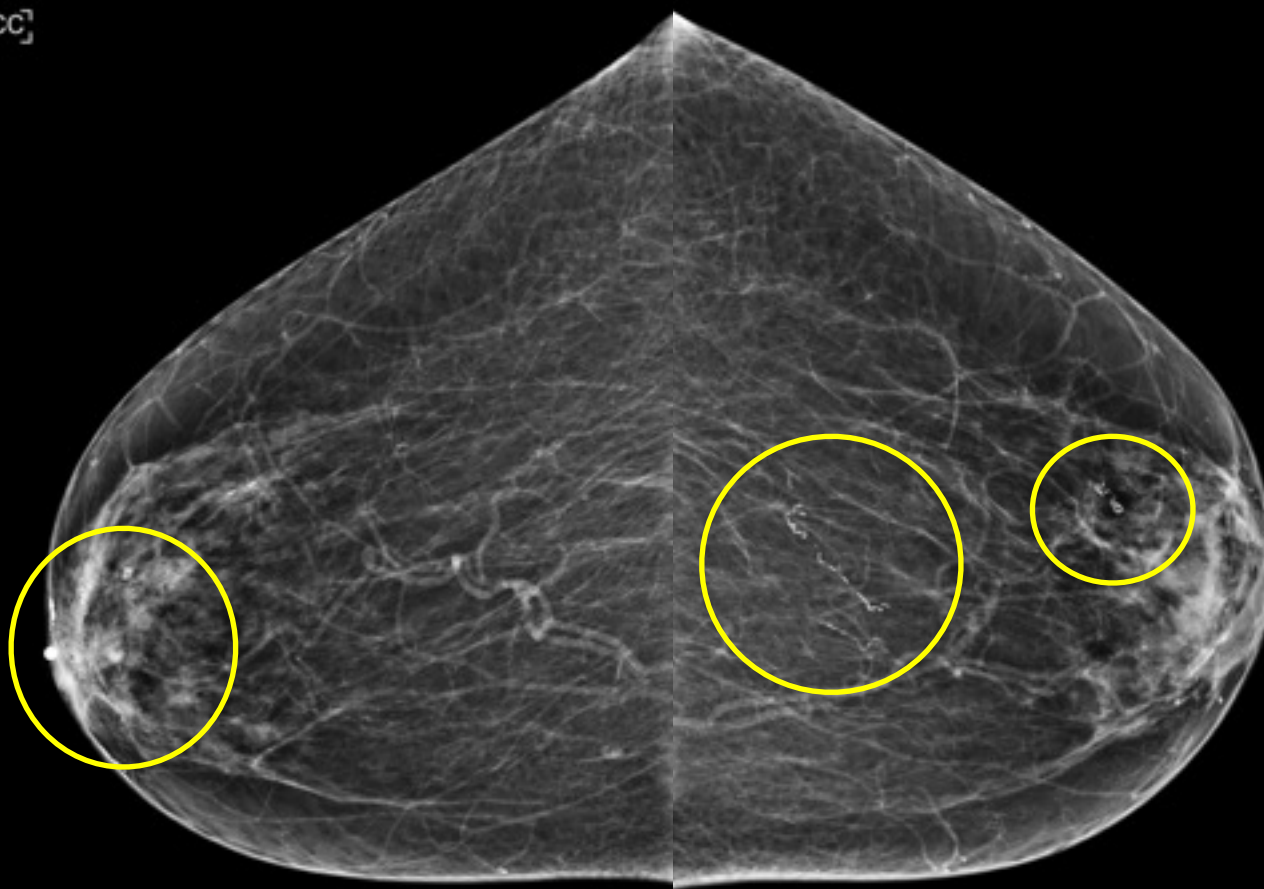


?

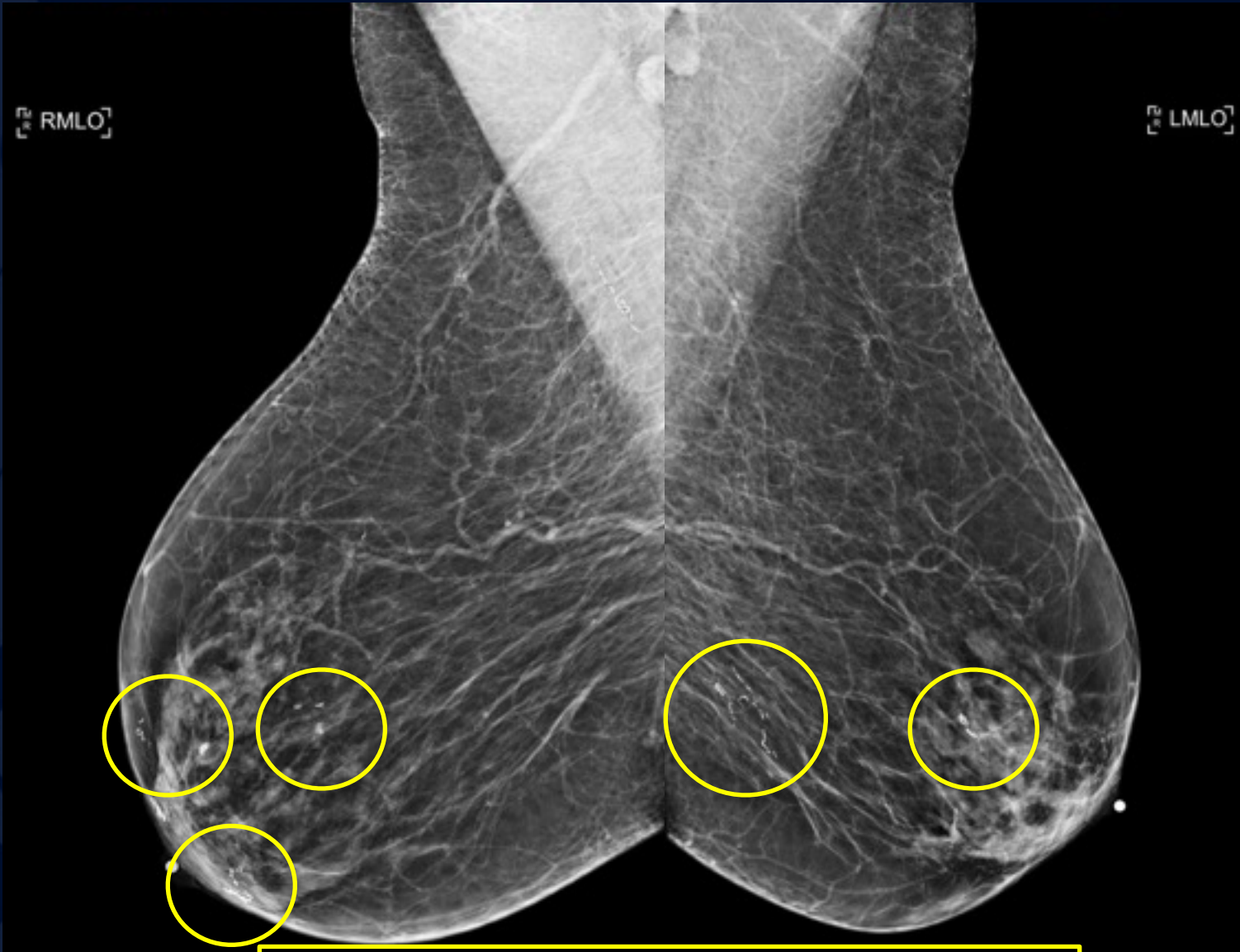
**Dracunculiasis
(Guinea worm disease)
BI-RADS Category 2:
Benign Finding**

RCC

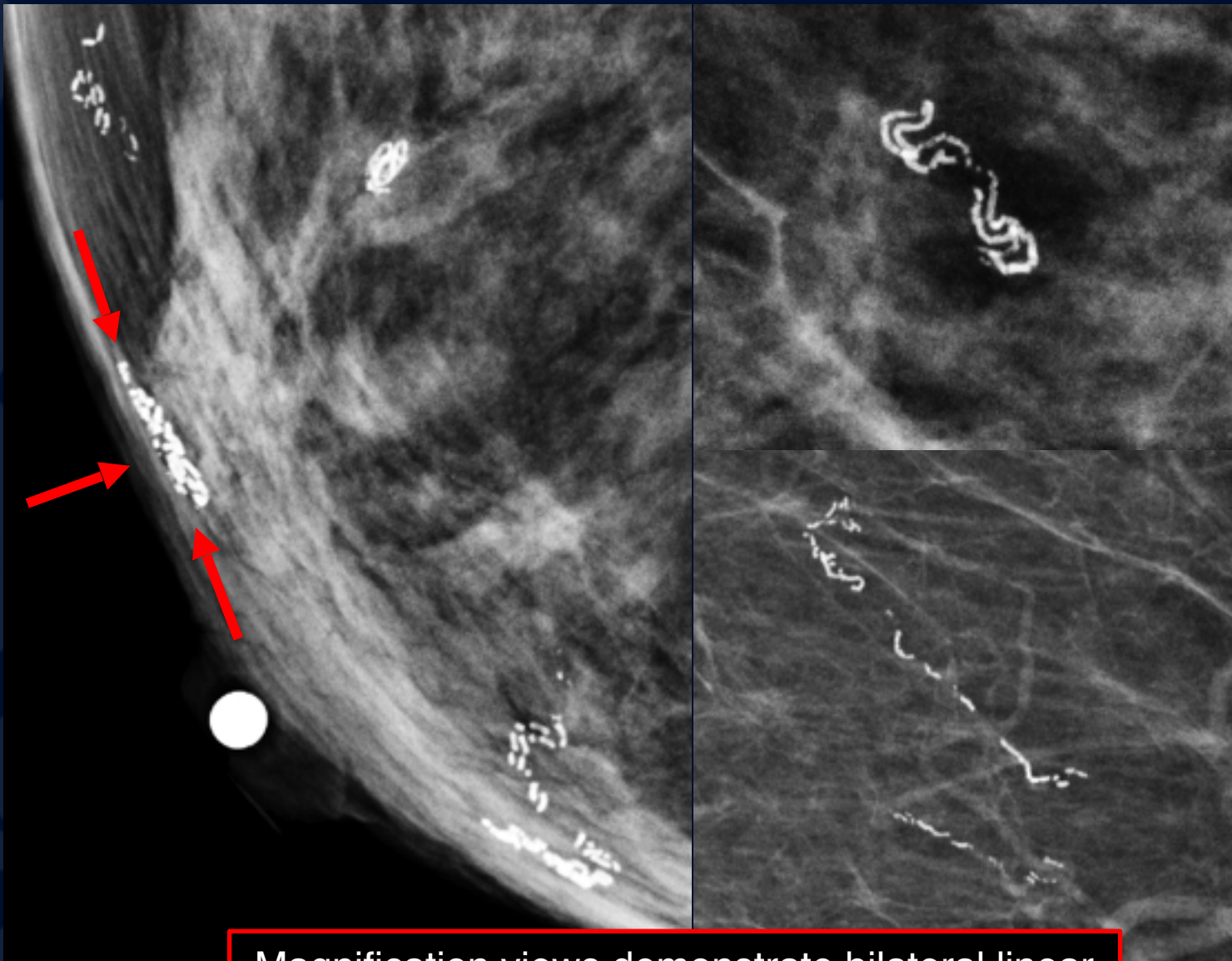
LCC



Cranio-caudal mammogram images demonstrate bilateral course linear serpiginous focal calcifications.

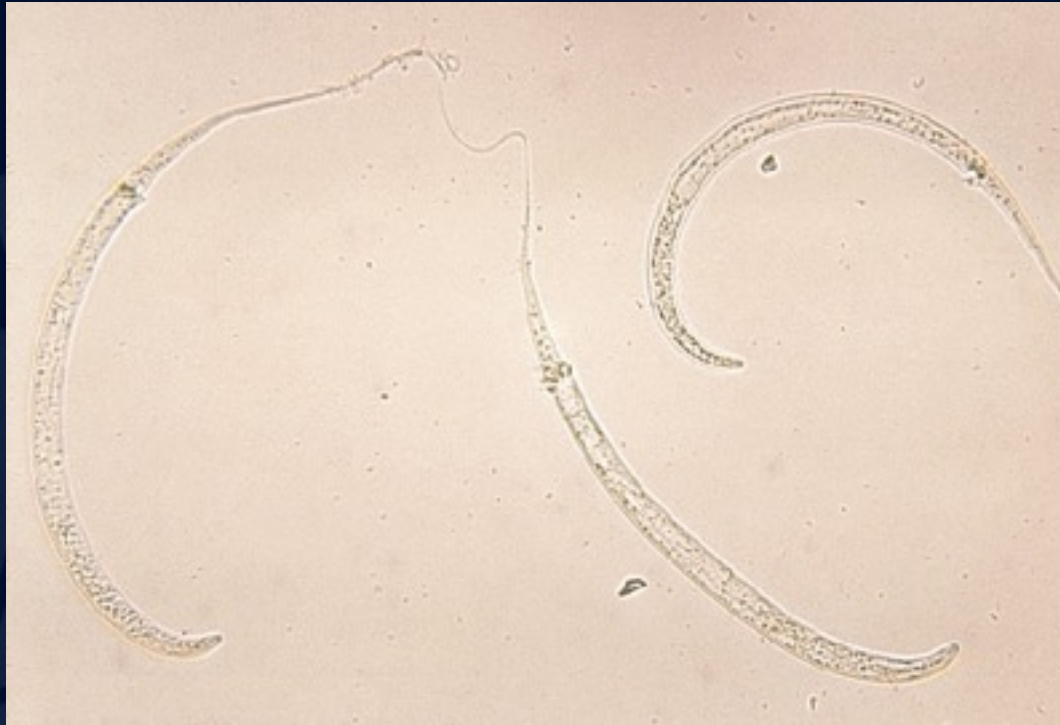

Mediolateral oblique mammogram images demonstrate bilateral course, linear serpinginous focal calcifications.



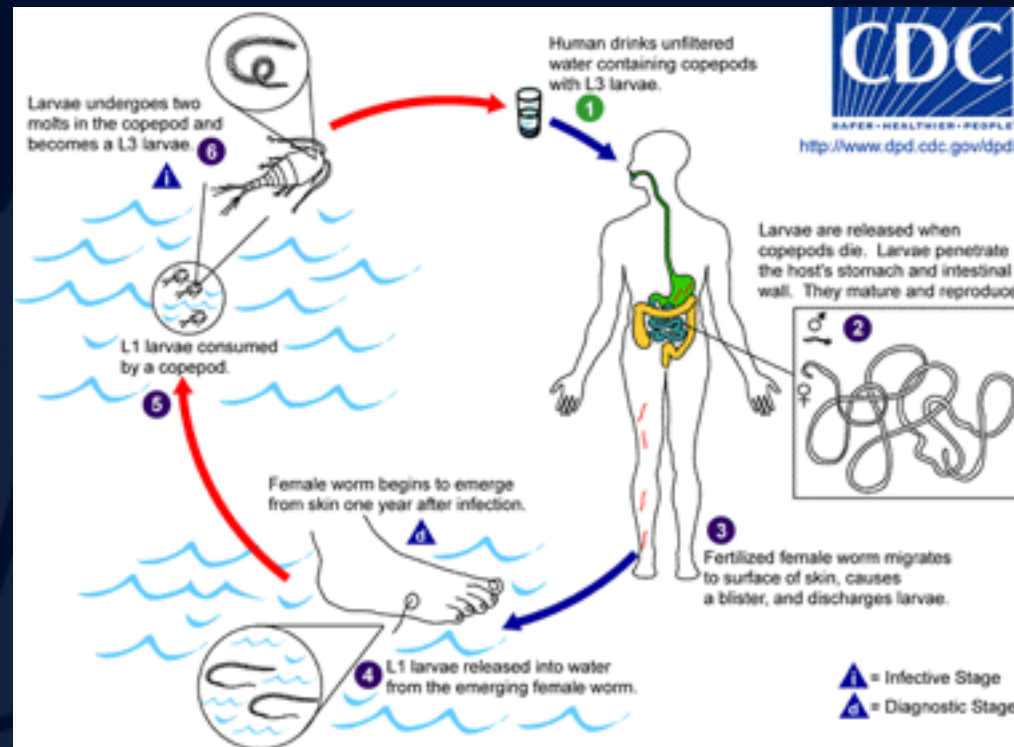
Magnification views demonstrate bilateral linear course, linear, serpiginous focal calcifications. RMLO view localizes the calcifications to the dermis (arrows).

Dracunculiasis (Guinea worm disease)



- *Dracunculus medinensis* (meaning "little worm from Medina")
- Endemic to the Nile Valley, central and western Africa, India, Pakistan, Iran, and other parts of the Arabian peninsula.

Dracunculiasis (Guinea worm disease)



Life Cycle: Infection occurs with the ingestion of water contaminated with larvae, which eventually migrate to the subcutaneous tissues. There, the female larvae become mature worms, mate, and expel their larvae through the skin. If a female worm dies before reaching the skin surface, it may calcify within the subcutaneous tissues. Calcification is the usual fate of the male worm.

Dracunculiasis (Guinea worm disease)

Mammographic Findings:

- Course dermal calcifications with a coiled or serpiginous linear appearance

Symptoms and Prognosis:

- Guinea worm disease is usually asymptomatic. However, the wound where the worm emerges are at risk for developing a secondary bacterial infection.
- Patients may develop fever, and localized pain and swelling as the worms emerge.
- 90% of the worms emerge from the legs and feet.

Treatment:

- There is no vaccine or medicine to treat or prevent Guinea worm disease.

Dracunculiasis (Guinea worm disease)

Differential Diagnosis

1. Arterial/Vascular Calcifications

- Thin linear calcifications involving the entire circumference of arteries in breast. “Tram track” appearance.

2. Intraductal calcifications

- Linear calcifications; often branching with malignancy

3. Prior mastitis/secretory disease

- Intra and peri-ductal linear calcifications; bilateral

4. Oil cyst

- Curvilinear egg shell calcification with a clear center

5. Fibroadenoma

- “Popcorn” calcification with dense center

6. Calcified sutures

- Calcifications of differing morphology, may be serpiginous, note: important to elicit history of prior surgery involving the breast

References:

1. Radiopedia - <https://radiopaedia.org/articles/dracunculiasis>
2. Center for Disease Control Website - https://www.cdc.gov/parasites/guineaworm/gen_info/faqs.html
3. Barry SK, Schucany WG. Dracunculiasis of the Breast: Radiological Manifestations of a Rare Disease. *Journal of Radiology Case Reports*. 2012;6(11):29-33. doi:10.3941/jrcr.v6i11.1137.
4. Hamilton LJ, Evans AJ. Dracunculiasis: a rare cause of breast calcification detected on screening mammography. *Clinical Radiology*. 2004;59(2):205–206.
5. Voelker R. Global Partners Take Two Steps Closer to Eradication of Guinea Worm Disease. *JAMA*. 2011;305(16):1642.