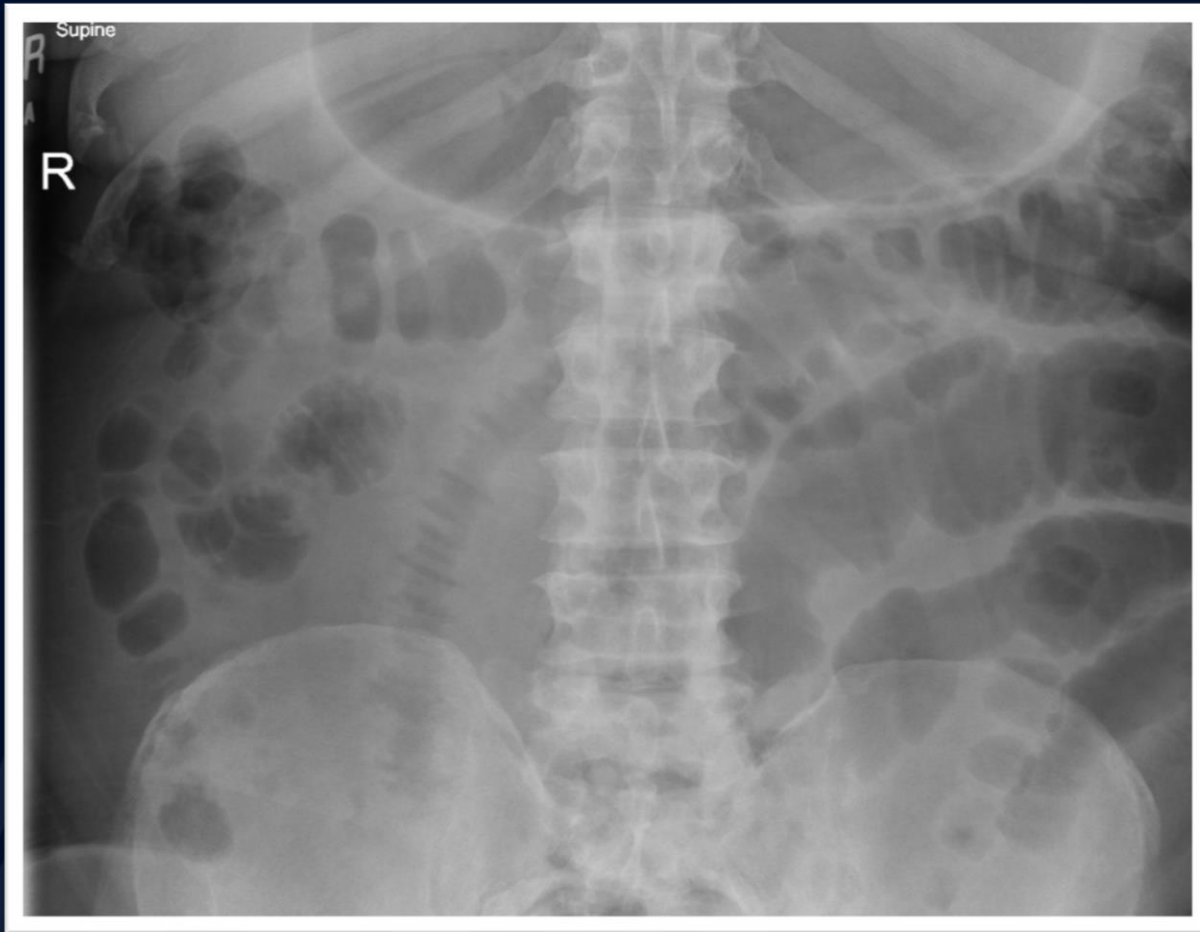


66 y/o male with a history of
vasculitis presents with
abdominal pain and skin rash

Edward Gillis, DO

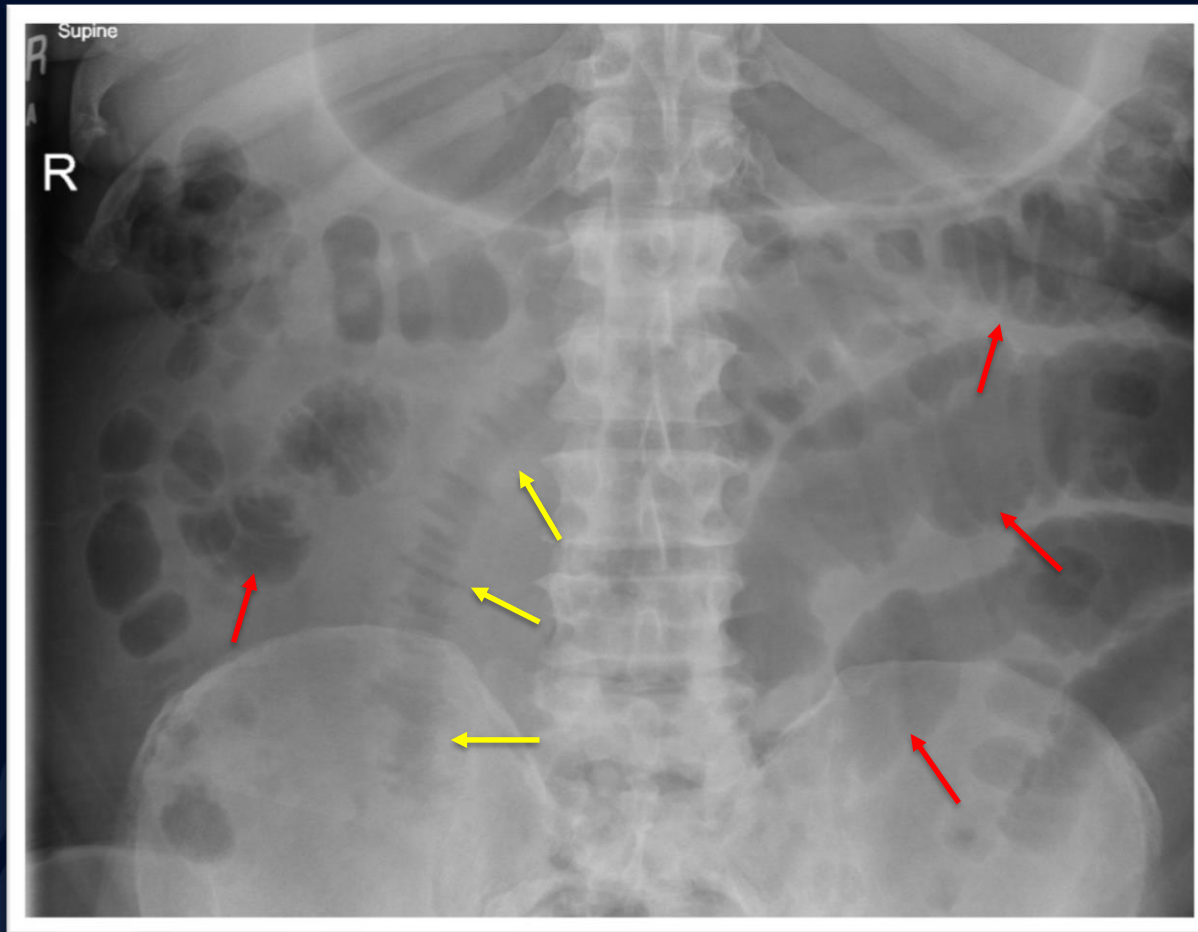


Supine Abdominal Radiograph



?

Small bowel vasculitis



Supine AXR demonstrating multiple loops of dilated small bowel (red arrows). A large segment of small bowel demonstrates uniform, regular thickening of folds with sharp delineation (yellow arrows).

Small Bowel Vasculitis

Imaging Features

- Uniform, regular thickening of folds secondary to edema or hemorrhage
- Sharp delineation of bowel folds with spike-like configuration
- May see separation of bowel loops secondary to bleeding into mesentery.

Small Bowel Vasculitis

General Features

- Inflammation of small bowel vessels due to systemic vasculitides.
- Different vessel sizes affected based on the particular vasculitis, but imaging findings usually overlap.
- Thickening of bowel wall folds is due to hemorrhage, edema, or ischemia.
- Predilection for jejunum.
- Complications
 - Ileus, perforation, ischemia, hemorrhage, stricture, fistula

Small Bowel Vasculitis

- Diseases with uniform, regular bowel wall thickening
 - SLE and other vasculitides
 - Lymphatic obstruction secondary to malignancy
 - Edema from low protein states (cirrhosis, nephrotic syndrome, protein-losing enteropathy)
 - Ischemic bowel disease
 - Anticoagulant therapy
 - Hemophilia
 - Coagulation defects (primary or malignancy related)
 - Hypothrombinemia, leukemia, myeloma, lymphoma, certain carcinomas

References

1. Brant, W. E., & Helms, C. A. (2012). *Fundamentals of diagnostic radiology*. Philadelphia: Wolters Kluwer Health/Lippincott Williams & Wilkins
2. Diagnostic Imaging for Radiology. (n.d.). Retrieved November, 15, 2017, from <http://www.statdx.com/>
3. Eisenberg, R. L. (2009). Thickening of Small Bowel Folds. *American Journal of Roentgenology*, 193(1). doi:10.2214/ajr.09.2762