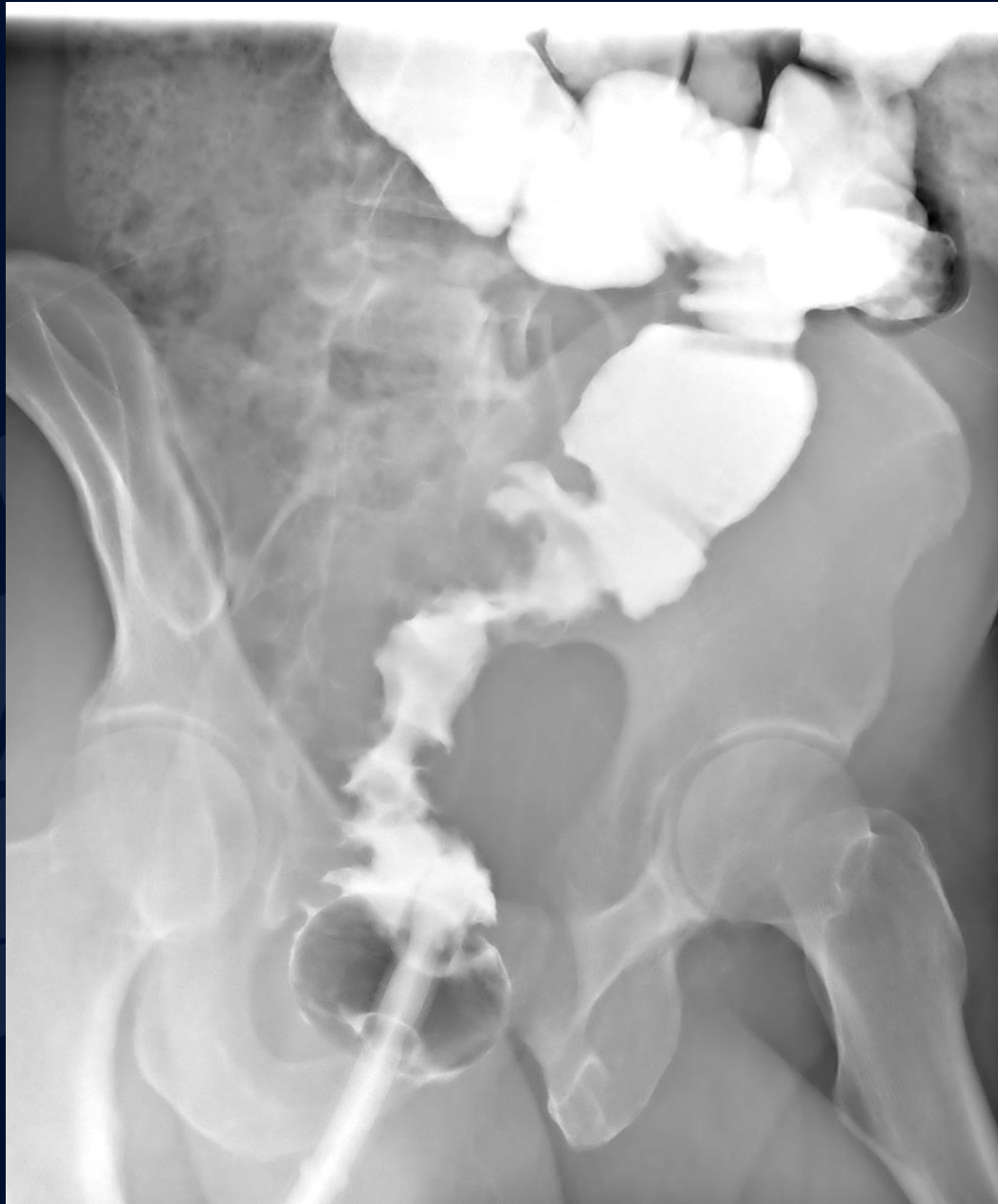

45 yr M, with hematochezia x6 months

Allan Zhang DO



UConn
HEALTH

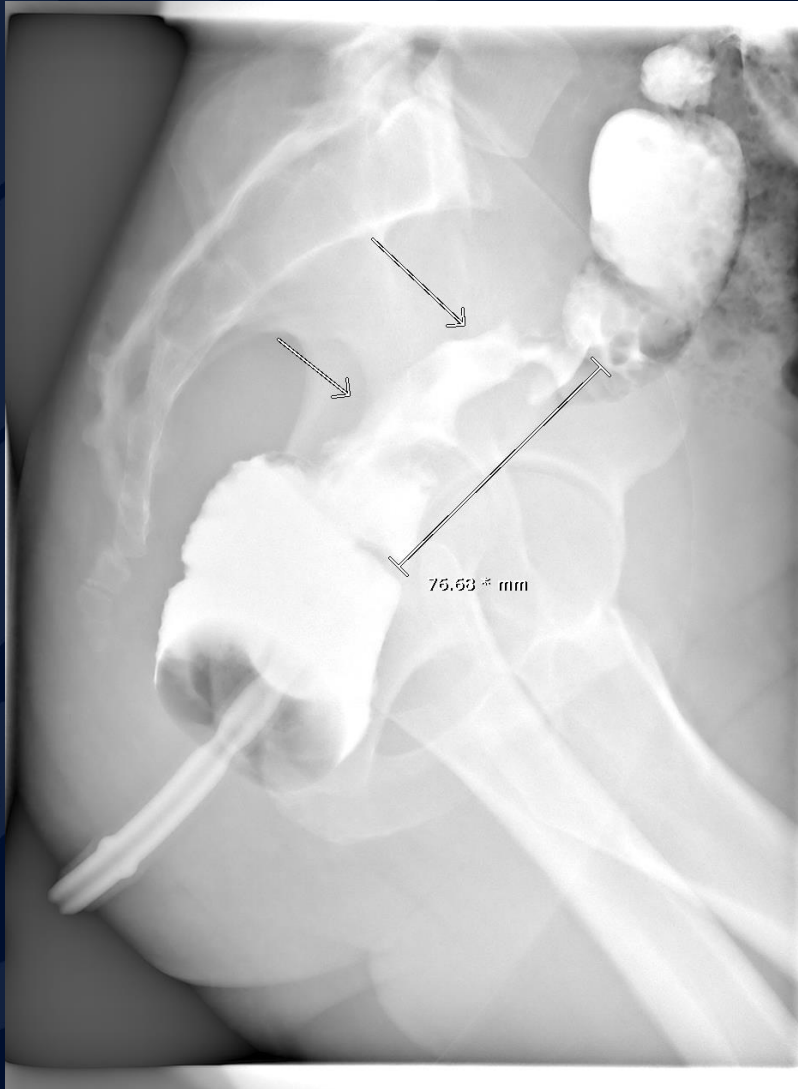
RADIOLOGY

A large, stylized oak leaf graphic in a dark blue color, positioned on the left side of the slide. It features detailed vein patterns and a lobed edge.

?

Sigmoid colon cancer

Sigmoid colon cancer



- Single contrast BE: Focal narrowing of the sigmoid colon with 'over-hanging' shoulders → apple core appearance.
- Preop for rectal stent

Colorectal carcinoma

Common locations:

- recto-sigmoid: 55%
- caecum and ascending colon: ~20%
- ileocaecal valve: 2%
- transverse colon: ~10%
- descending colon: ~5%

Presentation:

- Distal colon: Colonic obstruction and hematochezia
- Proximal colon: Anemia, weight loss, fever

Colorectal carcinoma

- Imaging:
 - Barium enema: early lesions will present as filling defects → luminal narrowing → obstruction/stenosis → perforation
 - CT: asymmetric mural thickening of soft tissue density with irregular surface, usually for staging
- Differentials:
 - Diverticulitis
 - Colitis (infectious vs ischemic vs inflammatory)\
- Treatment:
 - Complete surgical resection (≥ 5 cm on each side of tumor) with removal of lymphatic drainage vessels.