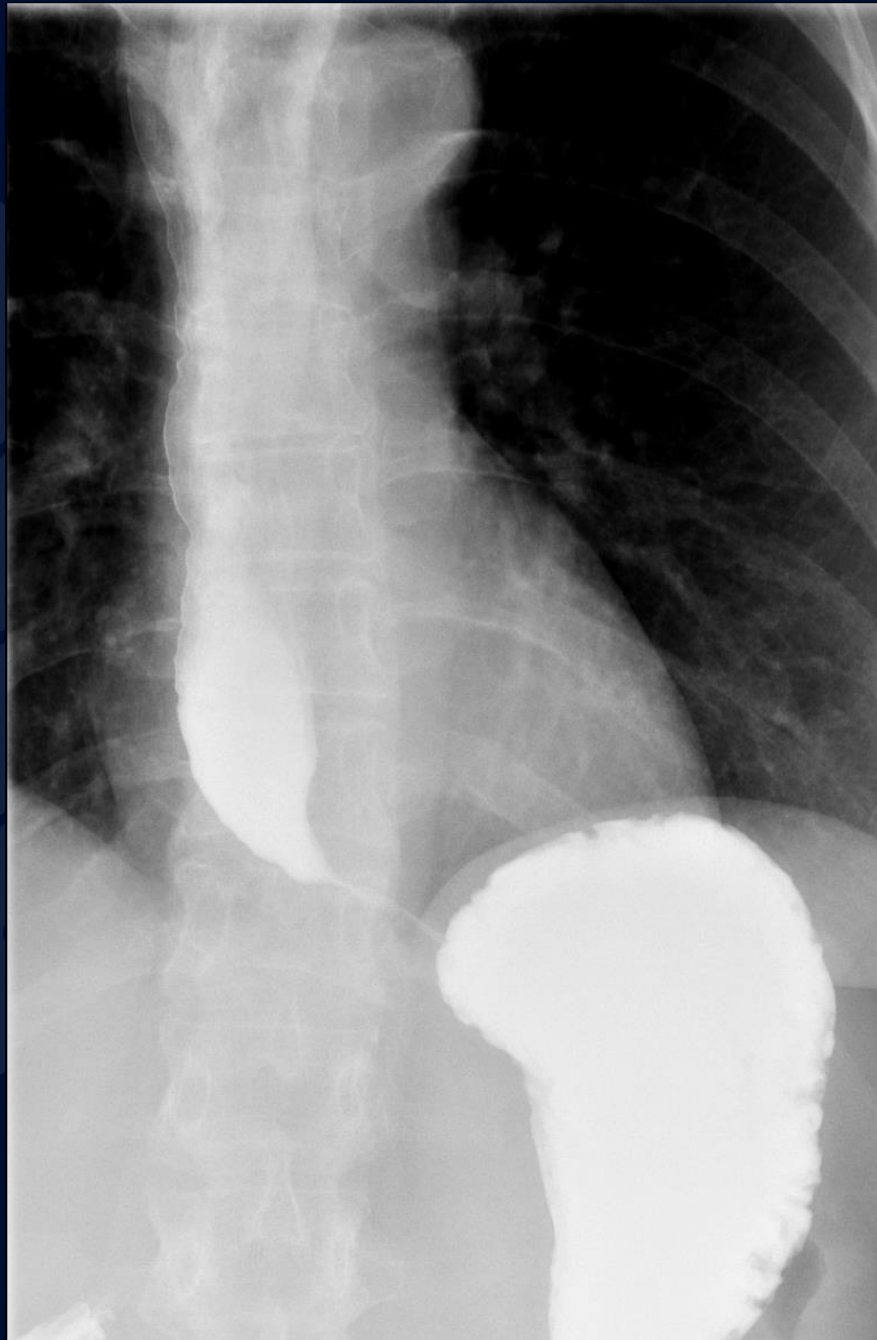


59 year old female, with dysphagia to
solids and liquids, x3 months

Allan Zhang DO



UConn
HEALTH

RADIOLOGY

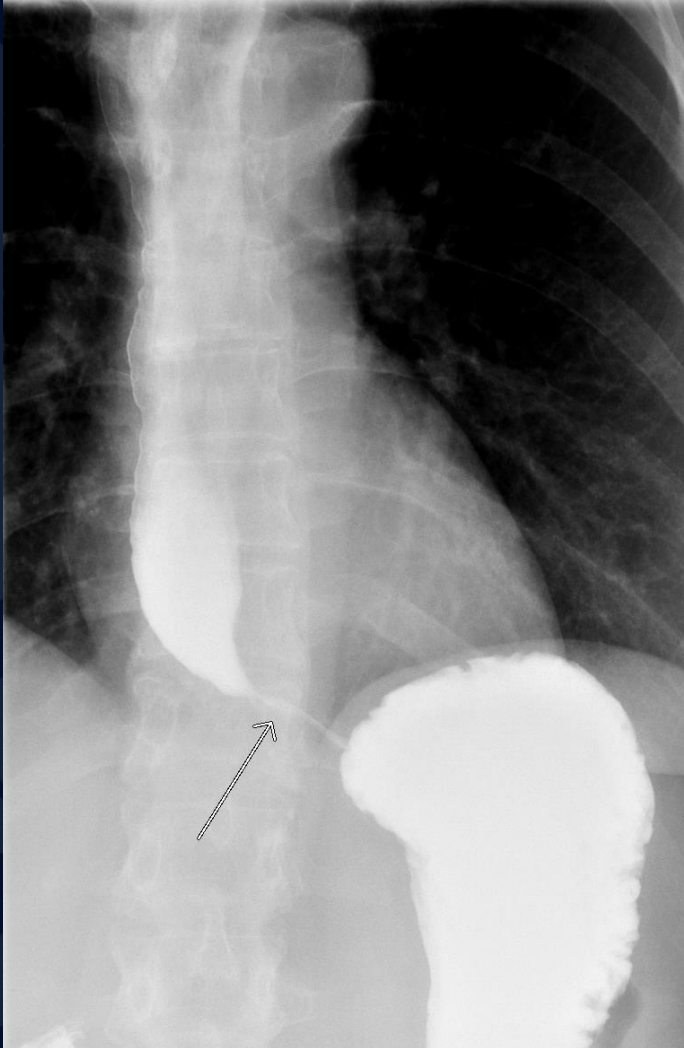


?

A large, stylized oak leaf graphic in a dark blue color, positioned on the left side of the slide. The leaf has a prominent central vein and several smaller veins branching off, with a scalloped edge.

Achalasia

Achalasia



- Single contrast UGI
- Uniform dilatation of the esophagus to the level of the gastroesophageal junction, where a smooth fixed narrowing is present.
- Results in stasis of ingested contrast material

Achalasia

- Form of esophageal dysmotility characterized by loss of distal esophageal peristalsis and failure of lower esophageal sphincter relaxation ¹
- Symptoms include dysphagia to both liquids and solids, difficulty belching, weight loss.

Achalasia

- Usually idiopathic, failure of DES to relax
- Pseudoachalsia → pathologic causes of esophageal dysmotility i.e. malignancy, amyloid, scleroderma, etc
- Treated by:
 - Nitrates, CCB → relaxation of DES
 - Pneumatic dilatation
 - Surgical myotomy