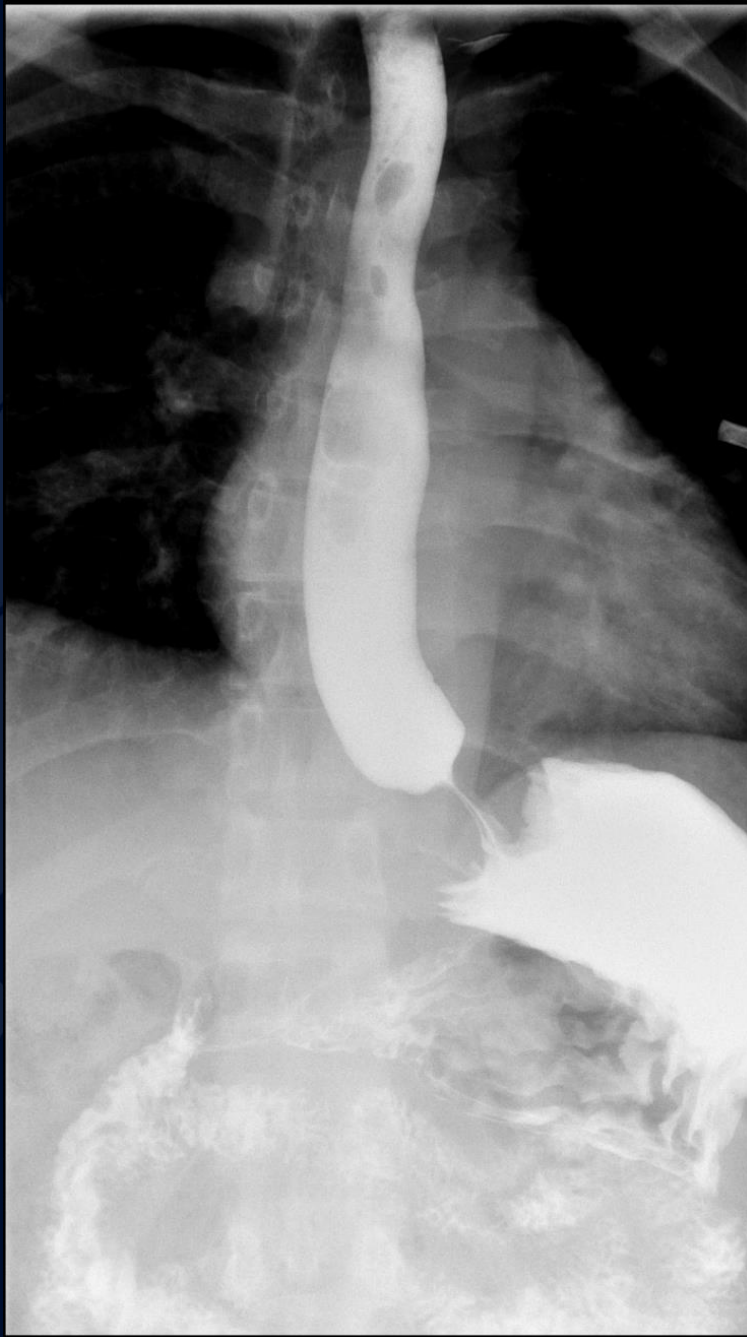


38 year old female, with hx of severe reflux, s/p Nissen 3 months ago, presents with dysphagia



**UConn**  
**HEALTH**

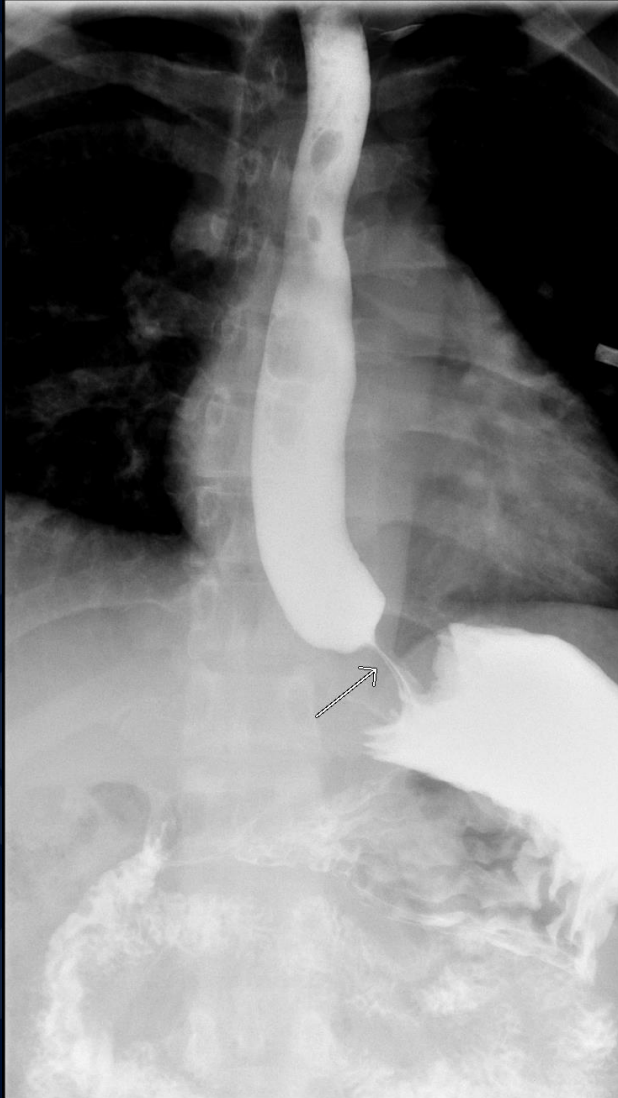
RADIOLOGY



?

# Tight Nissen Fundoplication

# Tight Nissen Fundoplication



- Single contrast UGI
- Smooth narrowing of a short segment of distal esophagus along the fundoplication site
- Delayed transit of contrast

# Tight Nissen Fundoplication

- A tight Nissen fundoplication refers to obstruction of the distal esophagus due to a fundoplication wrap that is too tight or too long (more than 2 cm)
- Symptoms include dysphagia, bloating, and regurgitation of undigested food and persist several weeks after the procedure.

# Tight Nissen Fundoplication

- Barium examination shows a smooth narrowing of the distal esophagus, with proximal luminal dilatation and delayed esophageal clearance.
- Treated by esophageal dilation; if unsuccessful, the fundoplication should be revised surgically