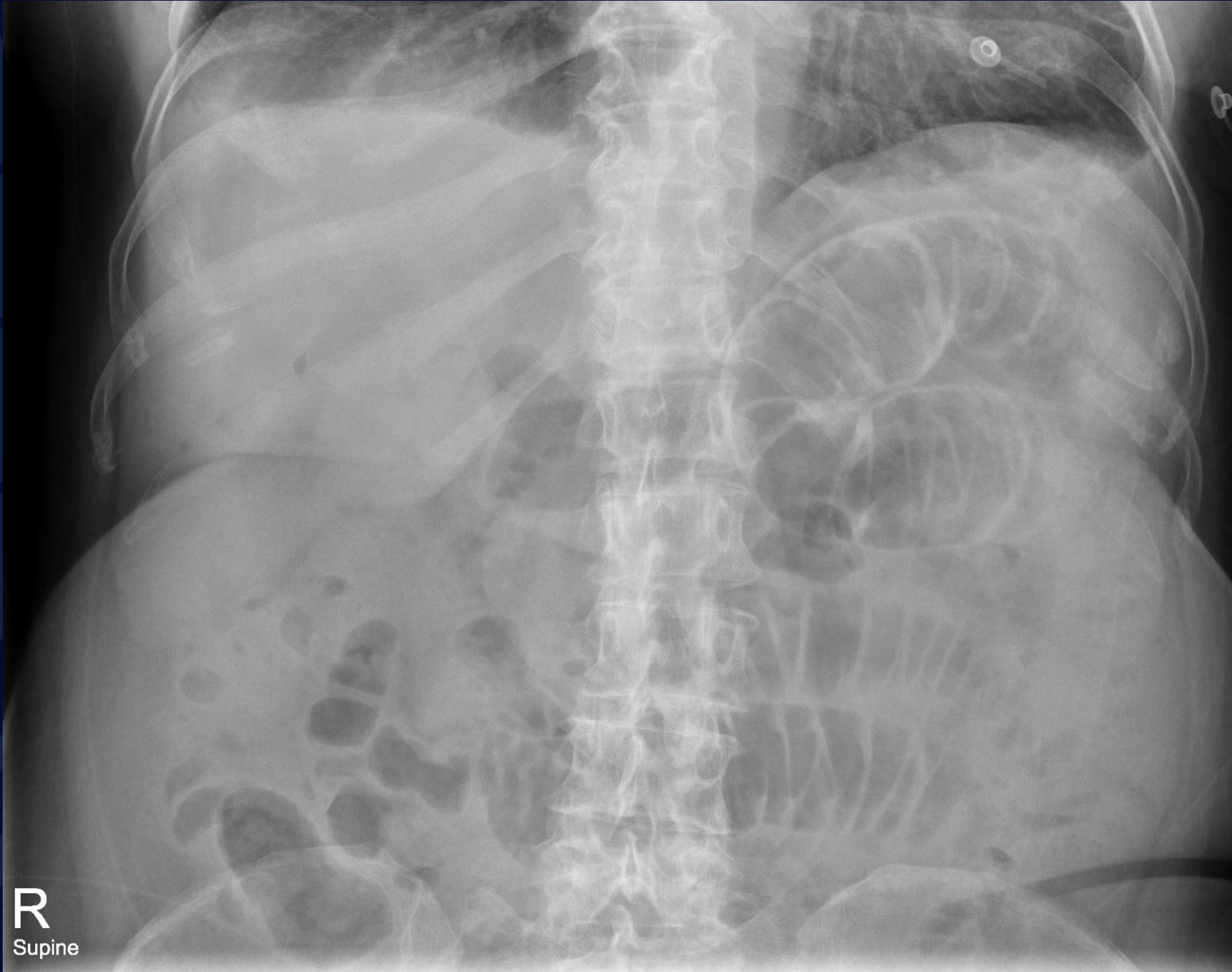

60F with abdominal pain

Jeffrey Guzelian MD



R
Supine

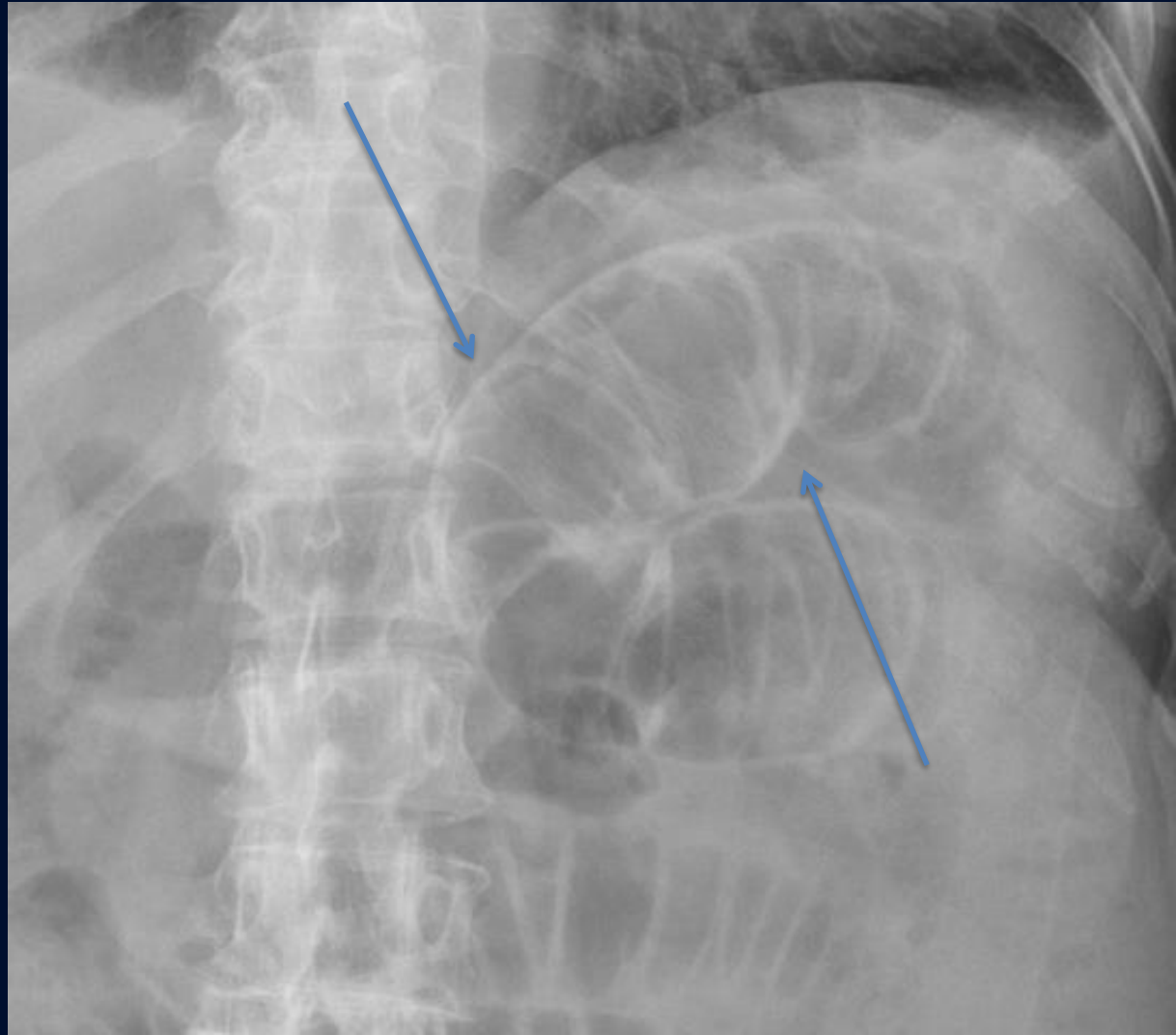


?

A large, stylized oak leaf graphic in a dark blue color, positioned on the left side of the slide. The leaf has a prominent central vein and several smaller veins branching off it. The leaf's edge is serrated.

Pneumoperitoneum

Supine AP of the abdomen demonstrates multiple dilated loops of proximal small bowel. Gas lucency outlines both sides of the bowel wall (arrows), indicative of pneumoperitoneum. This is known as Rigler's sign.



Pneumoperitoneum (Rigler's sign)

- On supine view of the abdomen, pneumoperitoneum is often seen as gas on both side of the bowel wall (both intraluminal and intraperitoneal). This is known as Rigler's sign or the Double Wall sign.
- Upright or decubitus views can be obtained for confirmation of pneumoperitoneum
- A potential false Rigler's sign can result from two loops of bowel in contact with one another