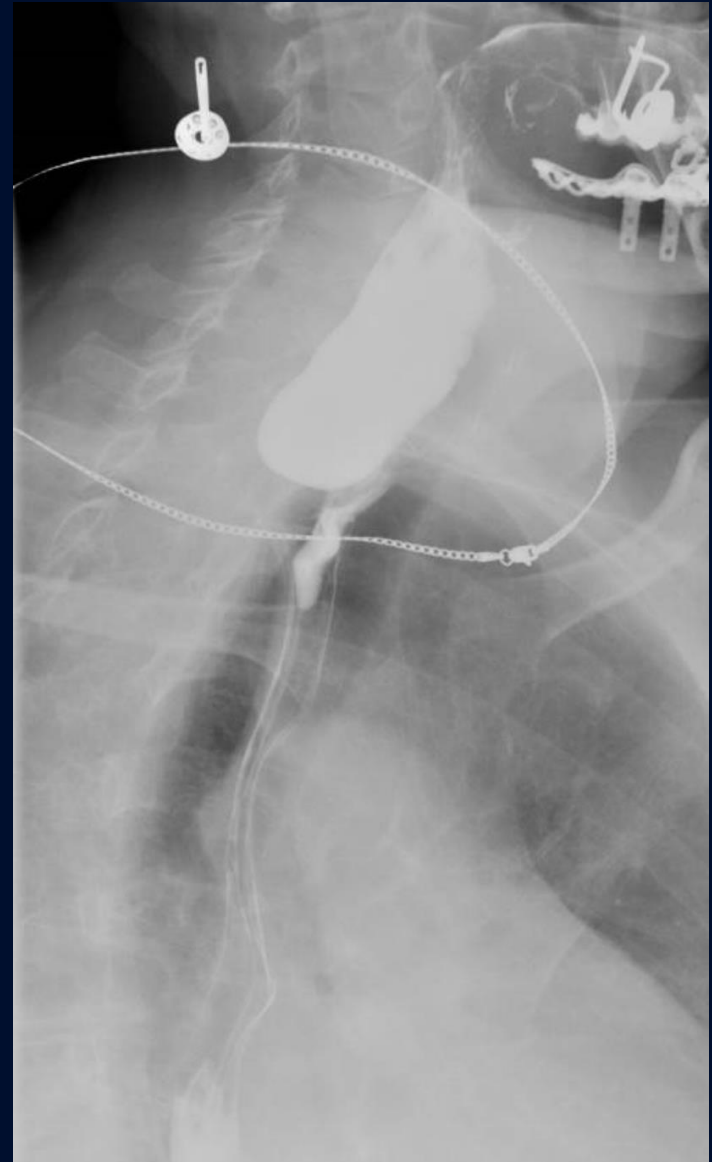
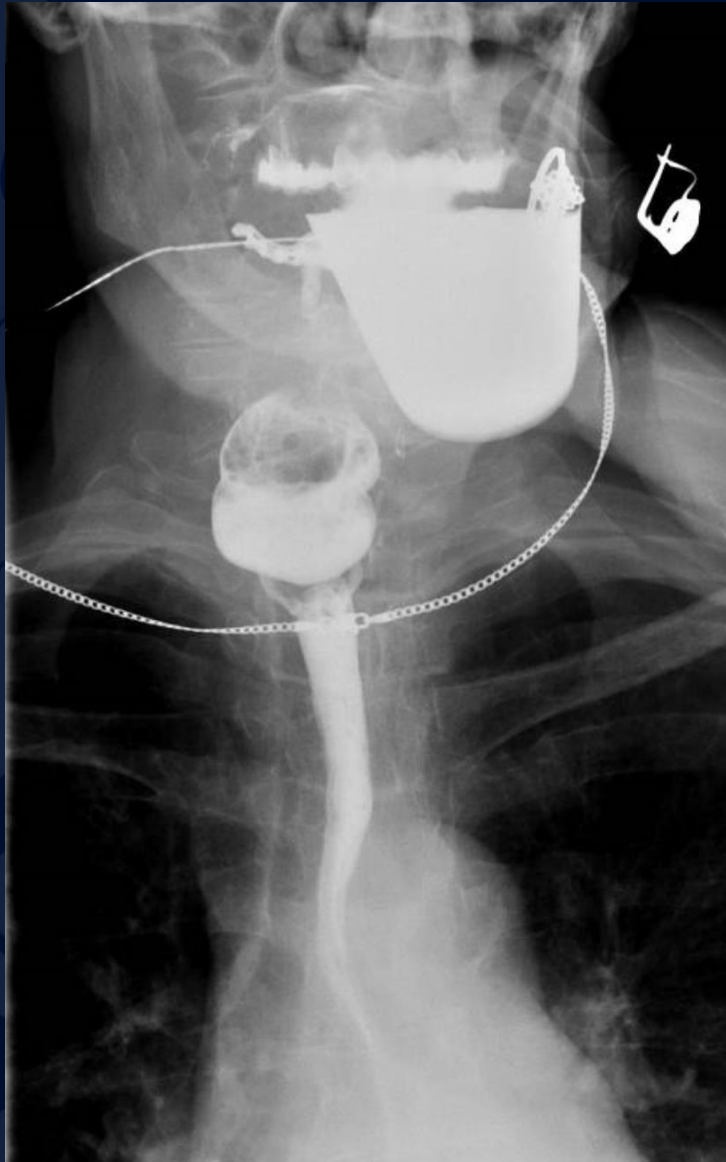

# 58-year-old female presents with dysphagia

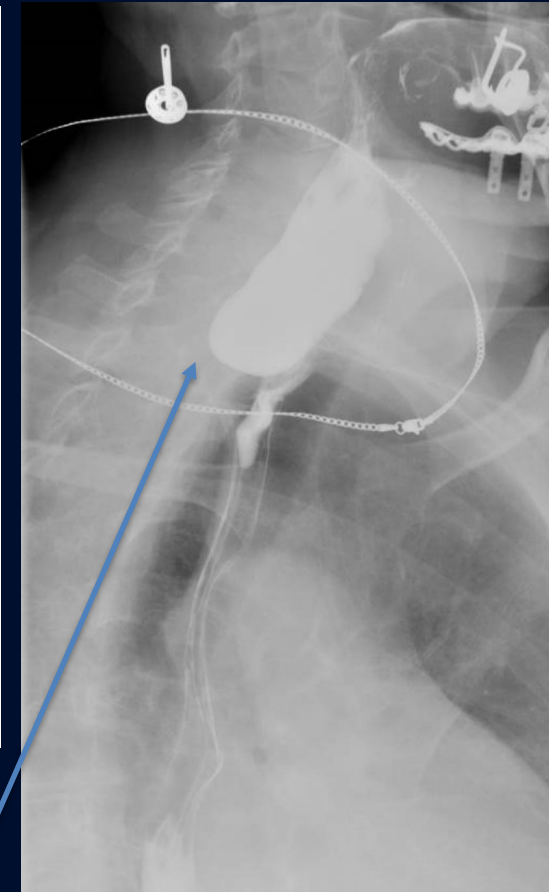
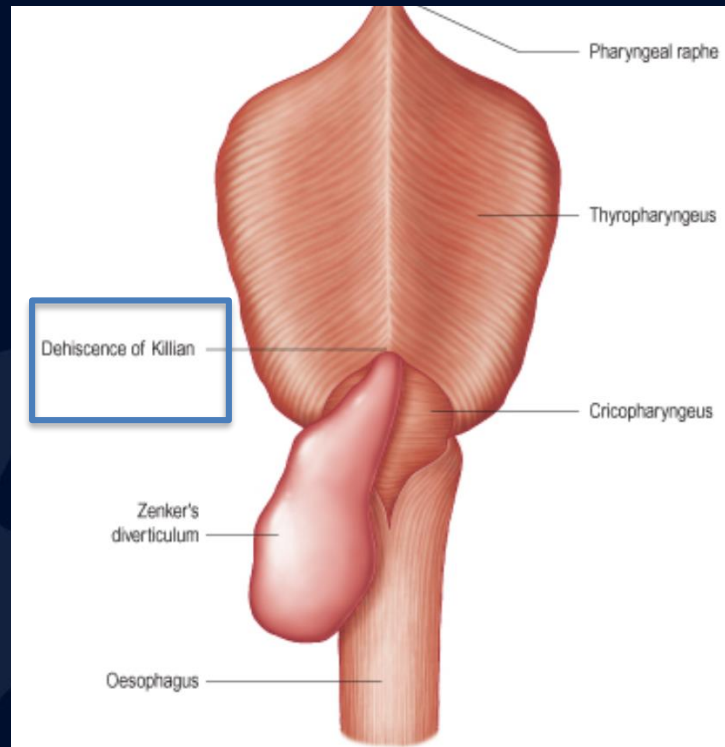
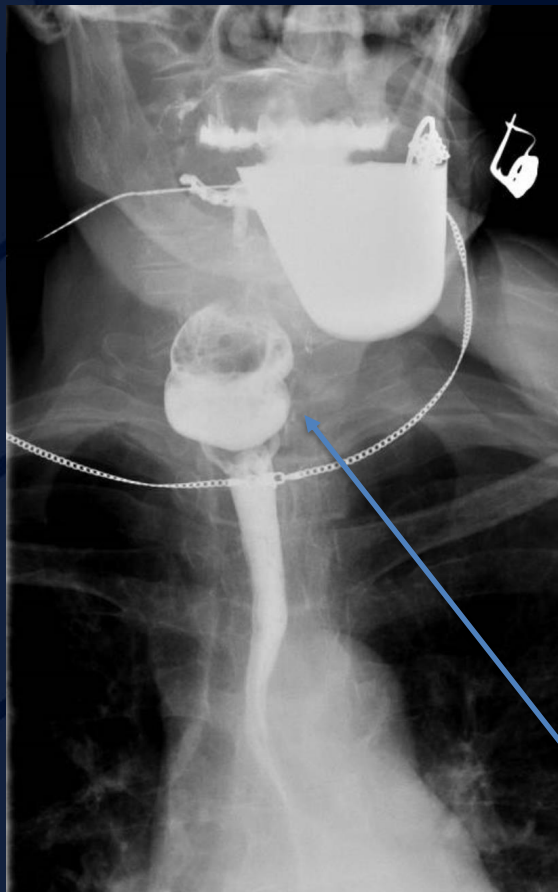
John J. DeBevits IV, MD



A large, stylized oak leaf graphic in a dark blue color, positioned on the left side of the slide. It features detailed vein patterns and a lobed edge.

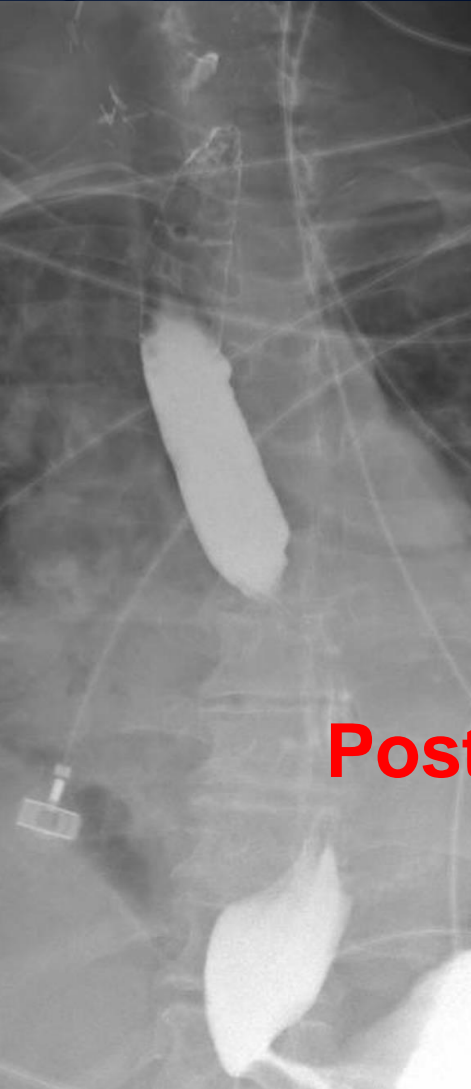
?

# Zenker diverticulum

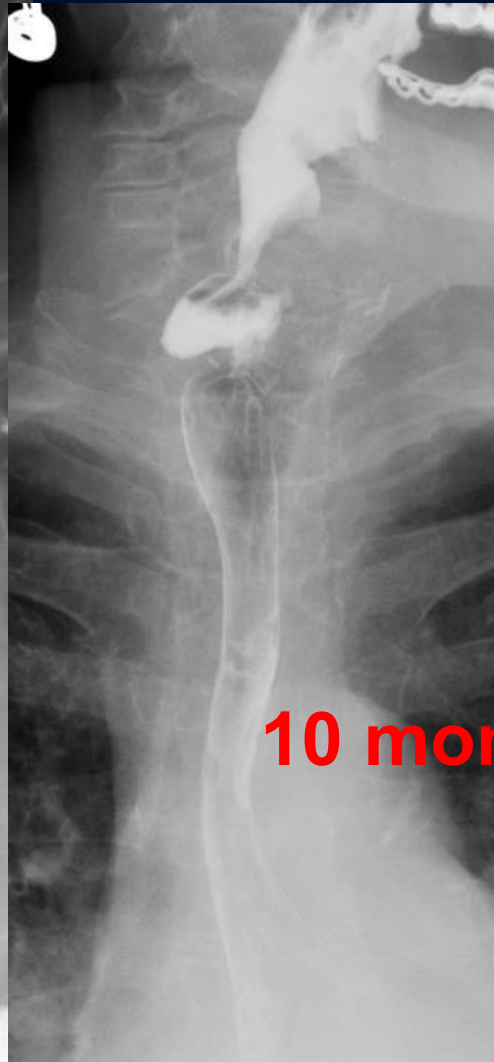
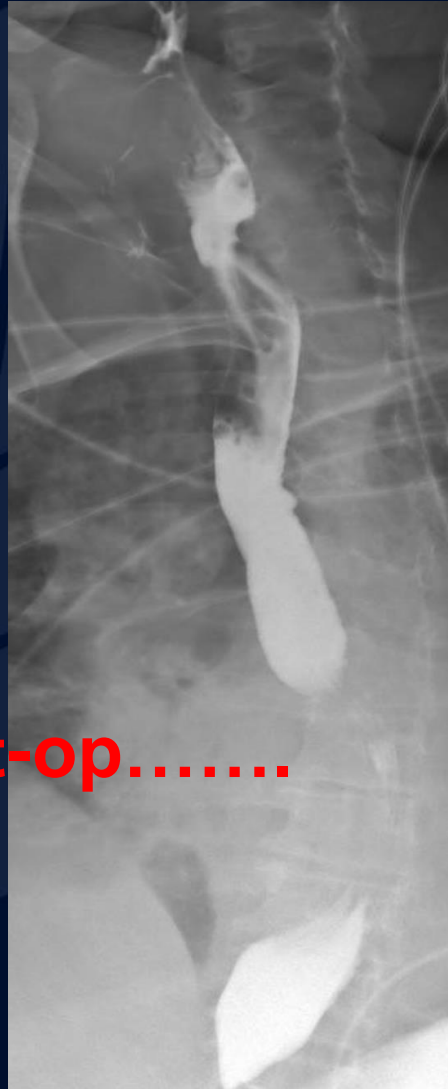

Large outpouching of the esophageal mucosa with filling of contrast media within the defect.

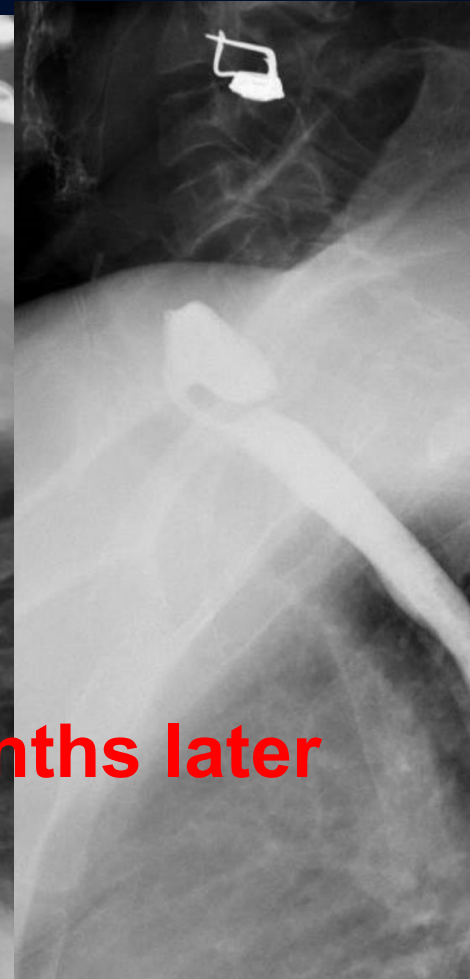
# Additional images of intrigue



Post-op.....



10 months later



A large, stylized oak leaf graphic in a dark blue color, positioned on the left side of the slide. The leaf has a prominent central vein and several smaller veins branching off it. The background is a solid dark blue.

Tend to recur...

# Zenker diverticulum

- **False, pulsion** type of diverticulum with mucosal herniation through area of anatomic weakness just above the cricopharyngeal muscle (Killian triangle)
- Presents with esophageal dysphagia, regurgitation and aspiration of undigested food
- Often associated with dysmotility, hiatal hernia, and GERD
- Complications include iatrogenic perforation during endoscopy or tube placement, aspiration, and small risk (0.3%) of carcinoma
- Treatment = surgical diverticulectomy or endoscopic repair
  - Following repair, commonly a residual outpouching will be seen, and many tend to recur...



# Zenker diverticulum

- Top ddx = Killian-Jamieson (KJ) diverticulum
  - Opening is **below** the cricopharyngeus muscle
  - Herniates in an **anterolateral** direction
- Other ddx = esophageal web, epidermolysis and pemphigoid

# References

1. <https://criticalcaremcqs.com/2010/06/26/otolaryngology-ent-mcqs-important-points/>
2. <http://www.radiologyassistant.nl/en/p472458f15c55a/esophagus-part-i.html>