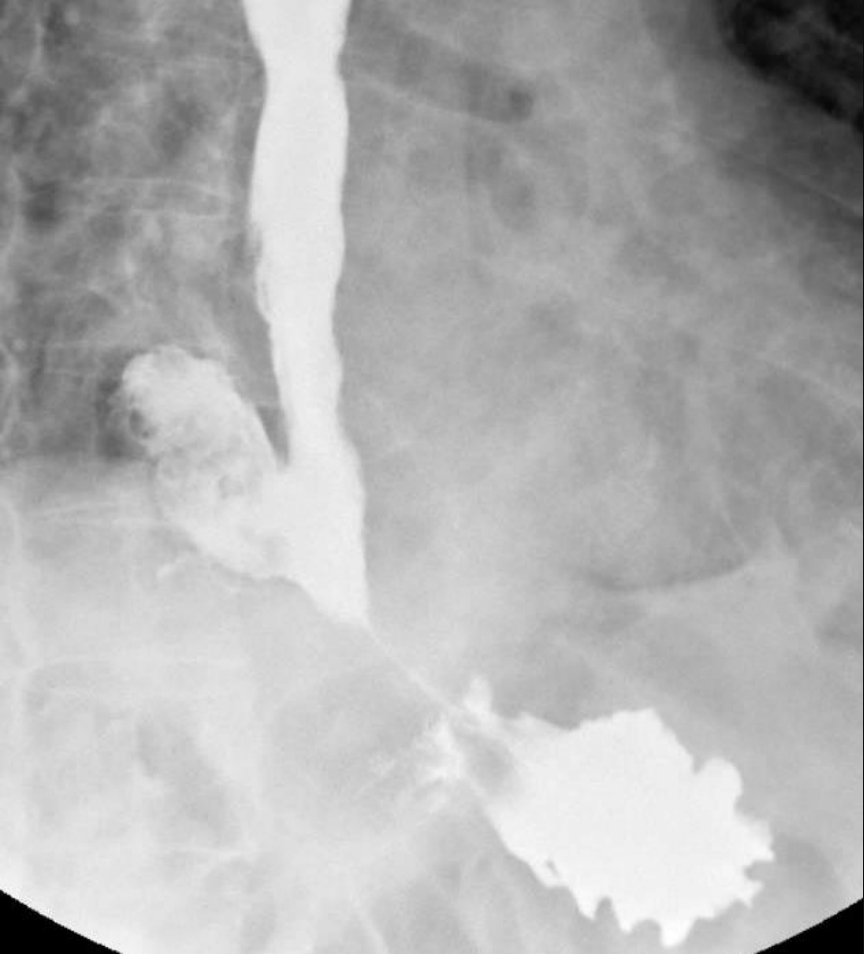
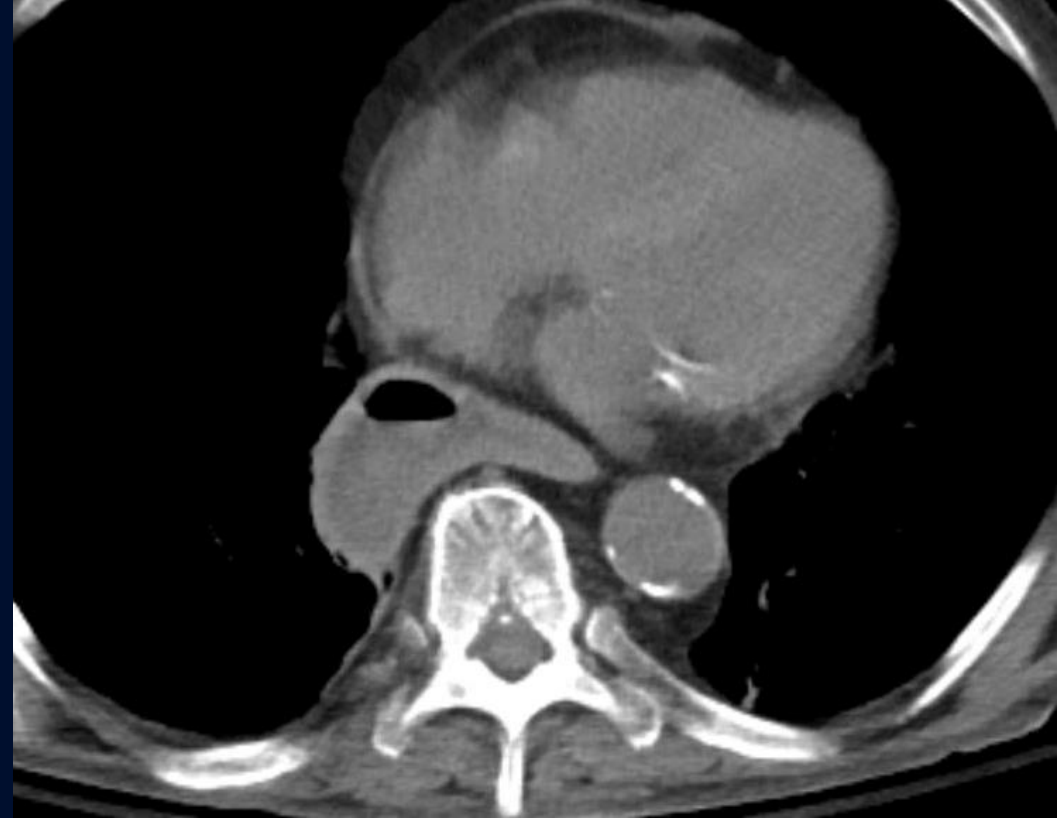
84M with dysphagia

Jeffrey Guzelian, MD

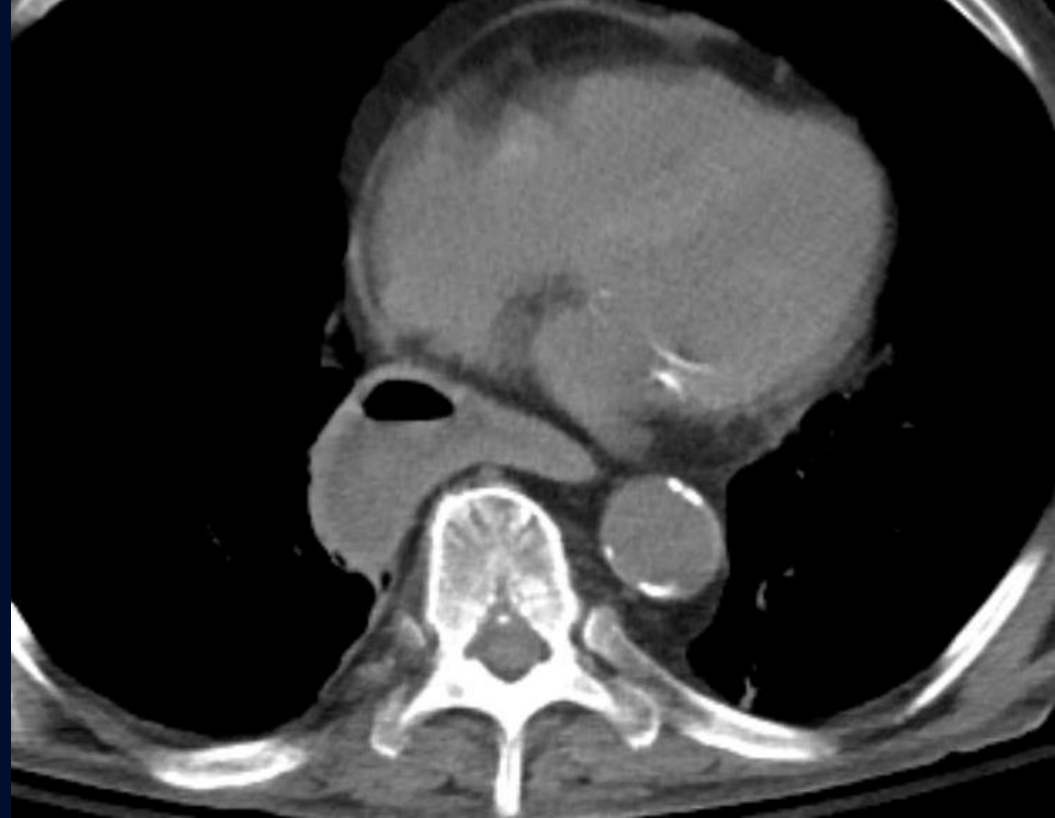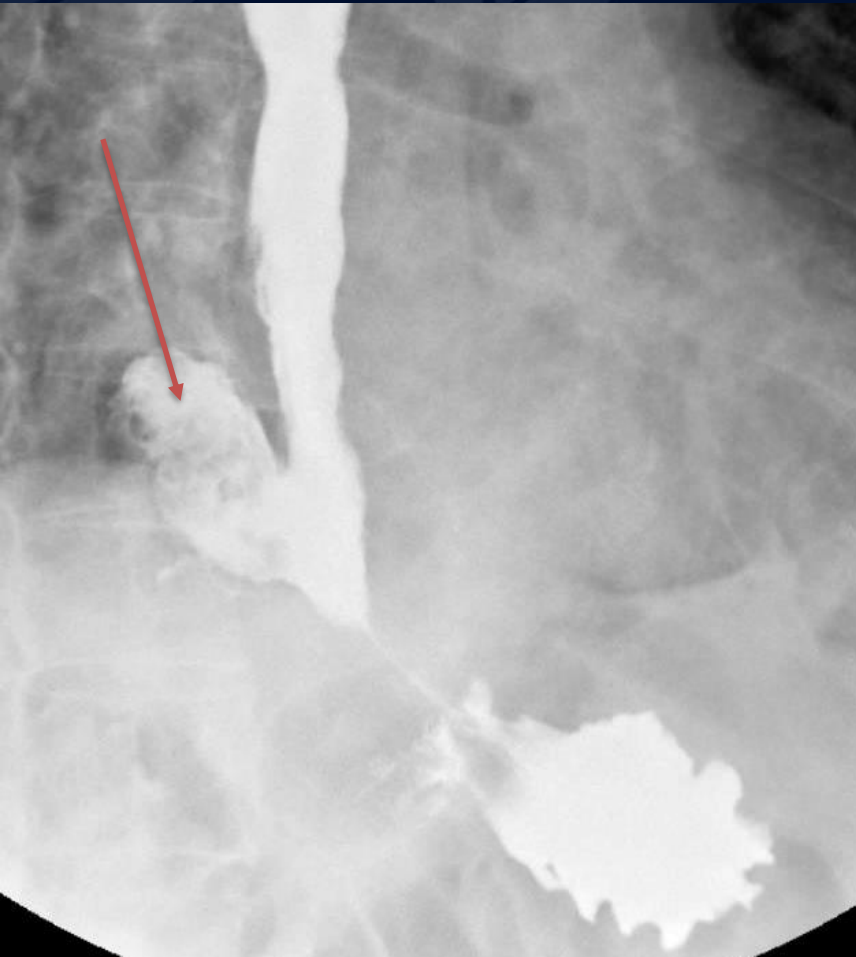




?

Epiphrenic Diverticulum

Fluoroscopic spot image from barium esophagram demonstrates contrast filling a large diverticulum arising from the distal esophagus (arrow)



Axial NECT confirms diverticulum arising from distal esophagus

Epiphrenic diverticulum

- A pulsion diverticulum arising just above the lower esophageal sphincter, usually right sided
- Due to increased intraluminal pressure associated with dysmotility syndromes
- Can present with dysphagia, regurgitation
- DDX: distal esophageal ballooning s/p myotomy, paraesophageal hiatal hernia (usually left sided)
- Tx: myomectomy or diverticulectomy

References

1. Fasano NC, Levine MS, Rubesin SE et al. Epiphrenic diverticulum: clinical and radiographic findings in 27 patients. *Dysphagia*. 2003;18 (1): 9-15