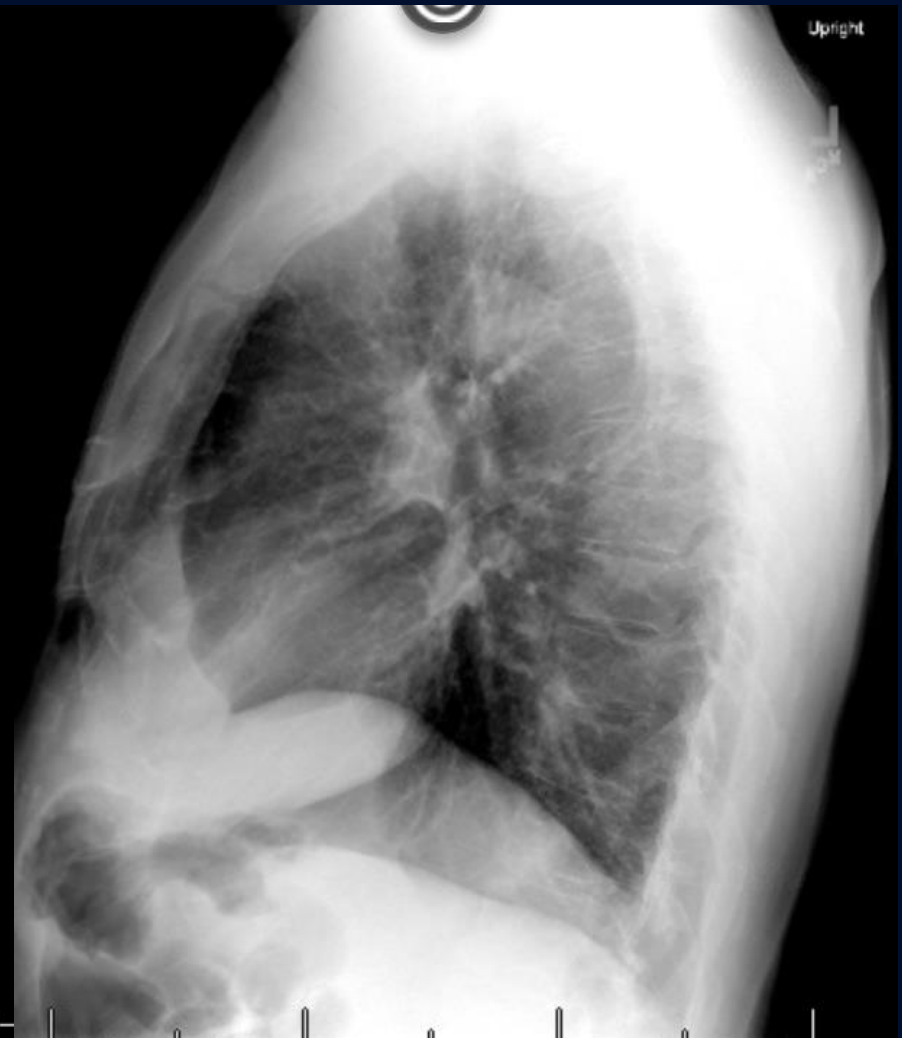
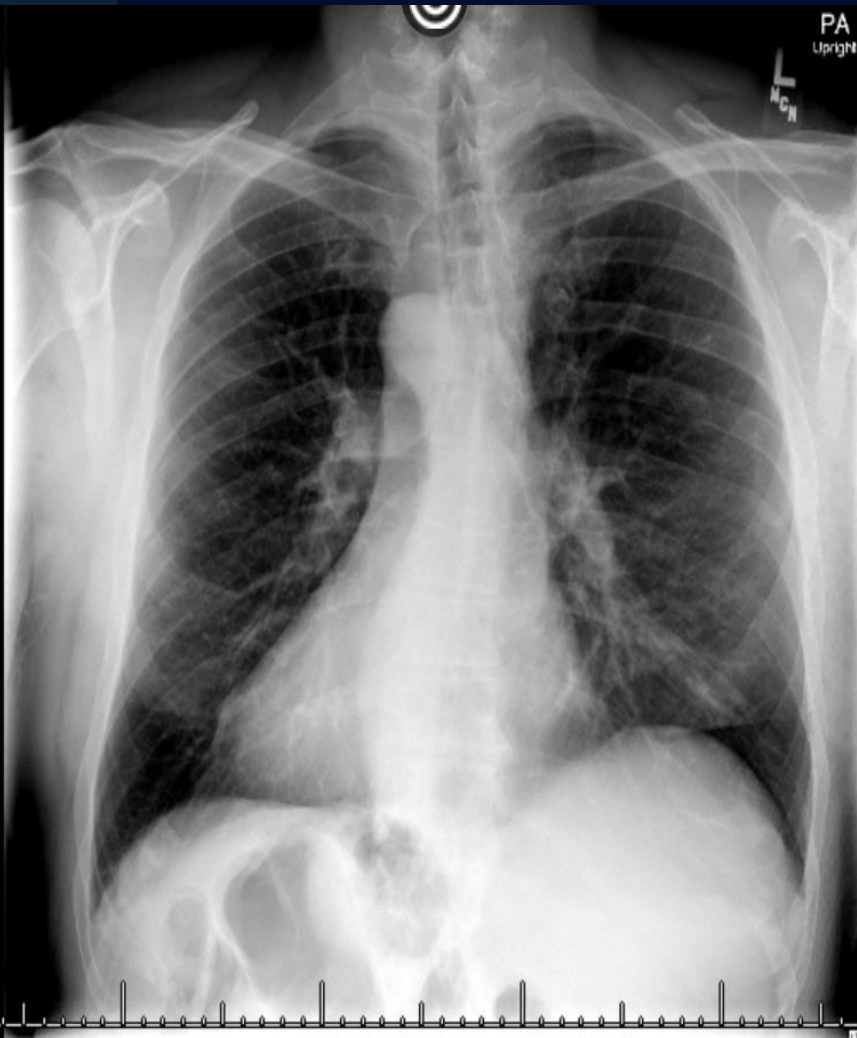
57 yr old man with chest pain

Allan Zhang, DO

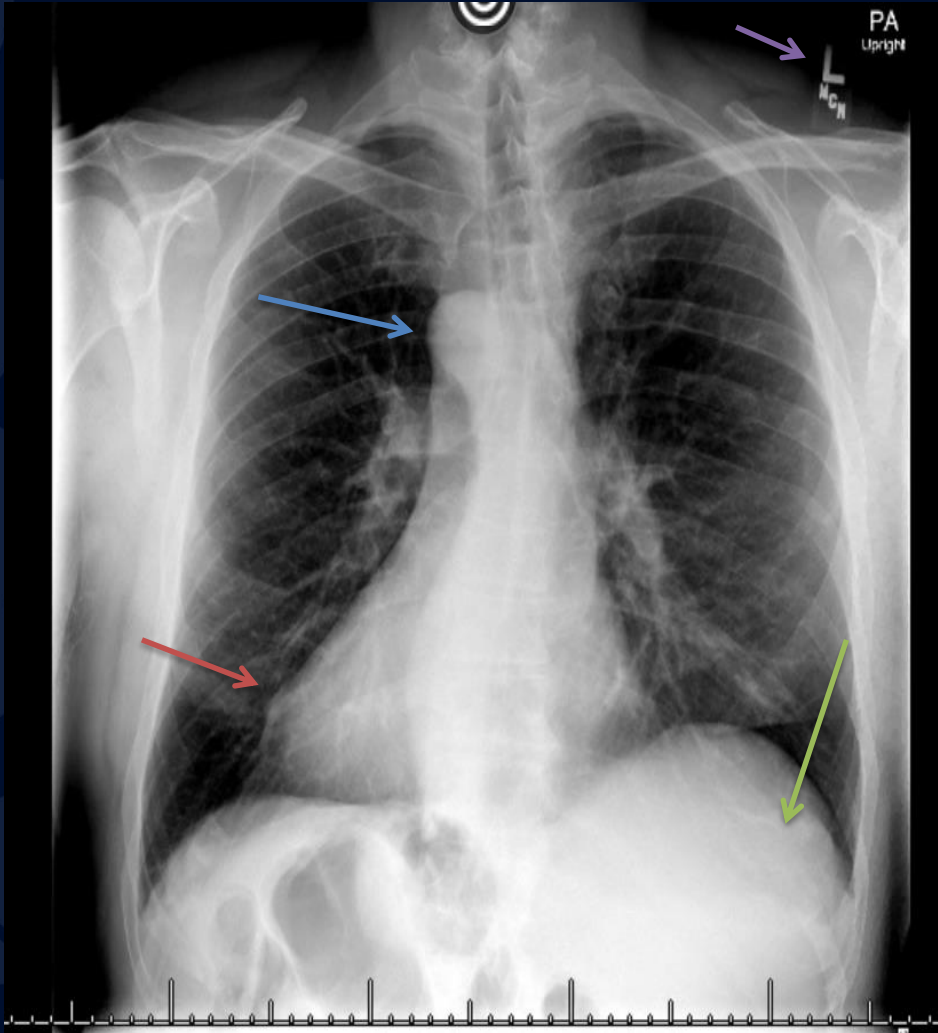




?

A large, stylized oak leaf graphic in a dark blue color, positioned on the left side of the slide. The leaf has a prominent central vein and several smaller veins branching off, with a serrated edge.

Situs Inversus Totalis



- Purple arrow: Labeled LEFT, correctly
- Green arrow: Liver on the left
- Blue arrow: Right arch
- Red arrow: Cardiac apex directed toward the right

Situs inversus totalis

- Differentiate from isolated dextrocardia (cardiac apex right, abdominal organs normal)
- Associated abnormalities
 - 20% have Kartagener syndrome
 - SI, bronchiectasis, sinusitis
 - Associated bowel malrotation increases risk for volvulus

Situs inversus totalis

- Imaging features on chest radiograph to evaluate are:
 - location of cardiac apex
 - location of aortic arch
 - location of stomach bubble / liver

References

- Situs Revisited: Imaging of the Heterotaxy Syndrome, *radiographics*