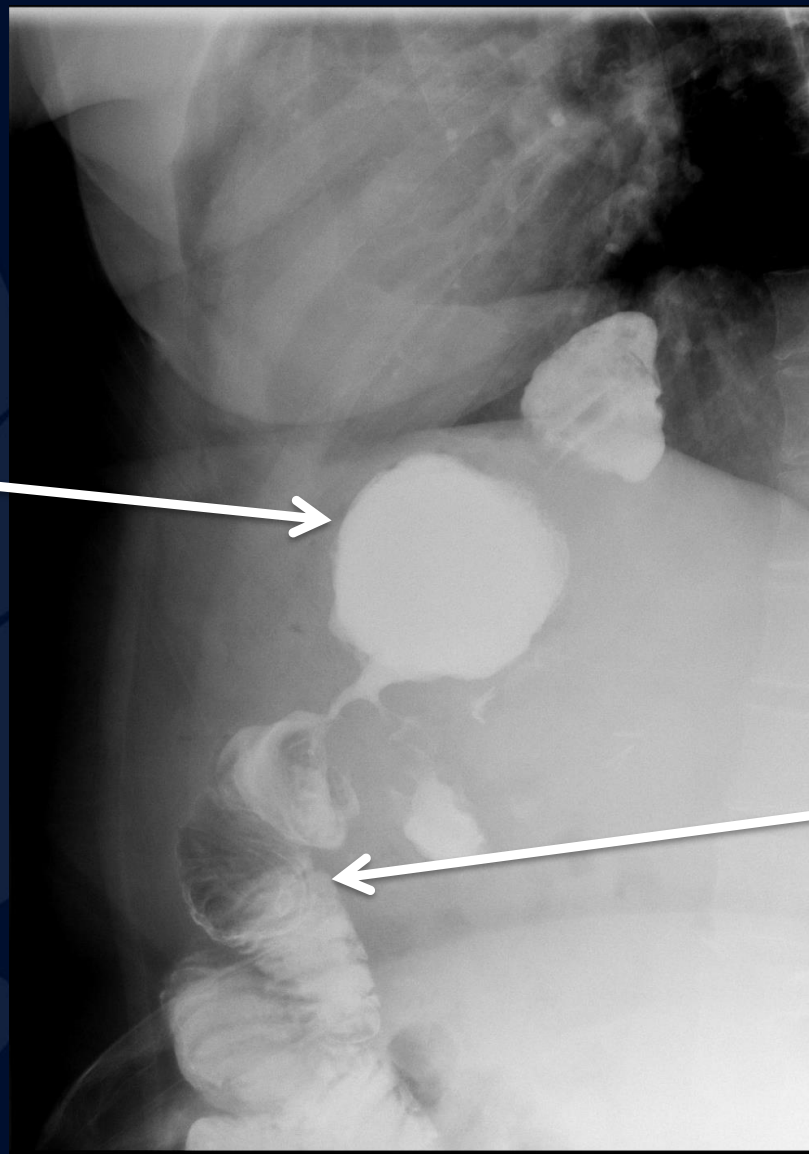


45 y/o F with nausea and  
dysphagia status post gastric  
bypass

Atul Kumar, MD, MS

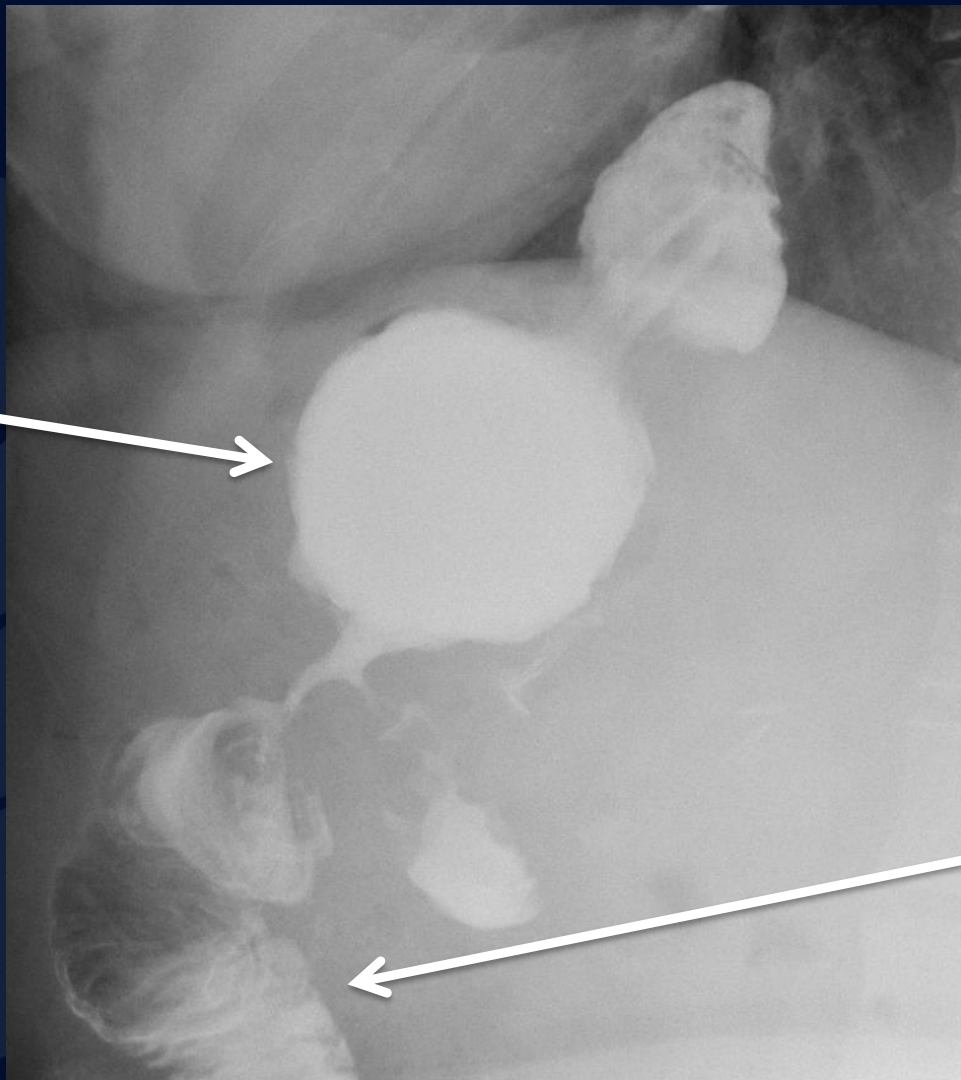
Gastric  
Pouch



Jejunum

Lateral Fluoroscopy

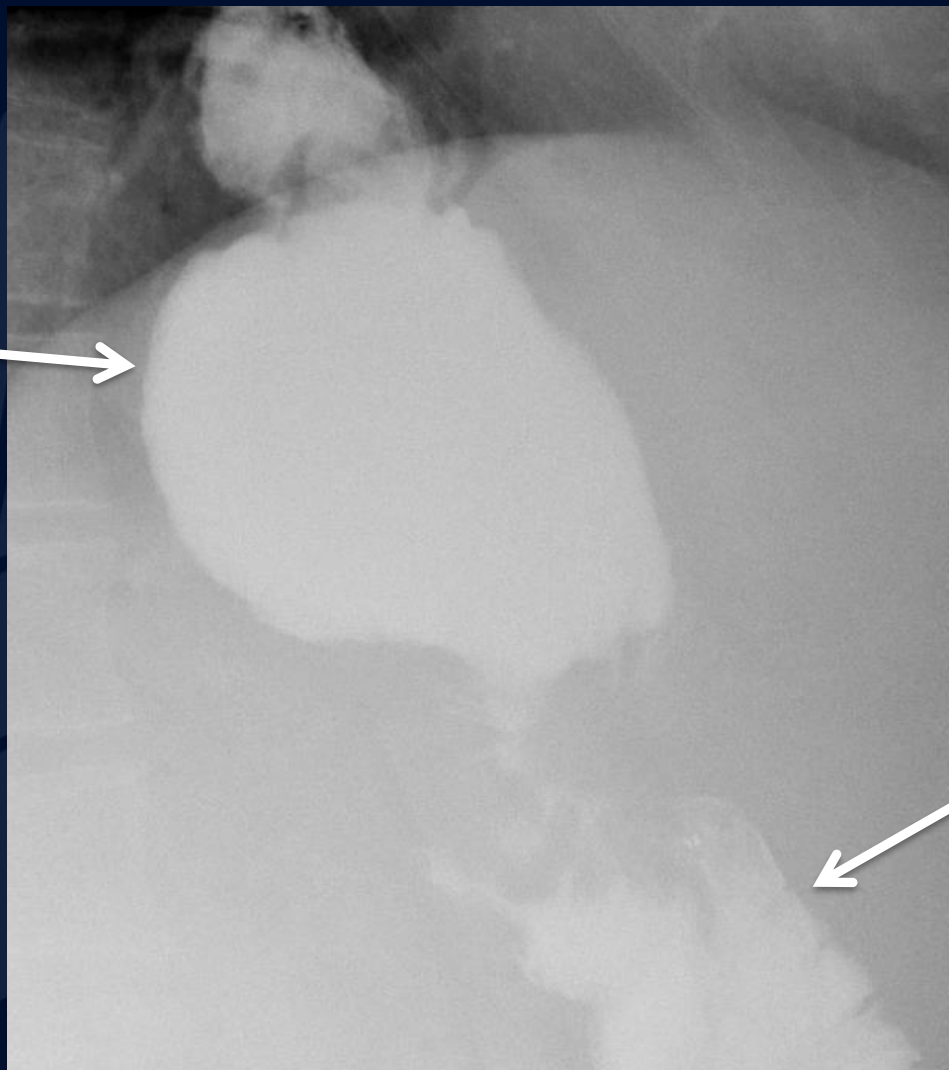
Gastric Pouch



Jejunum

Lateral Fluoroscopy

Gastric Pouch

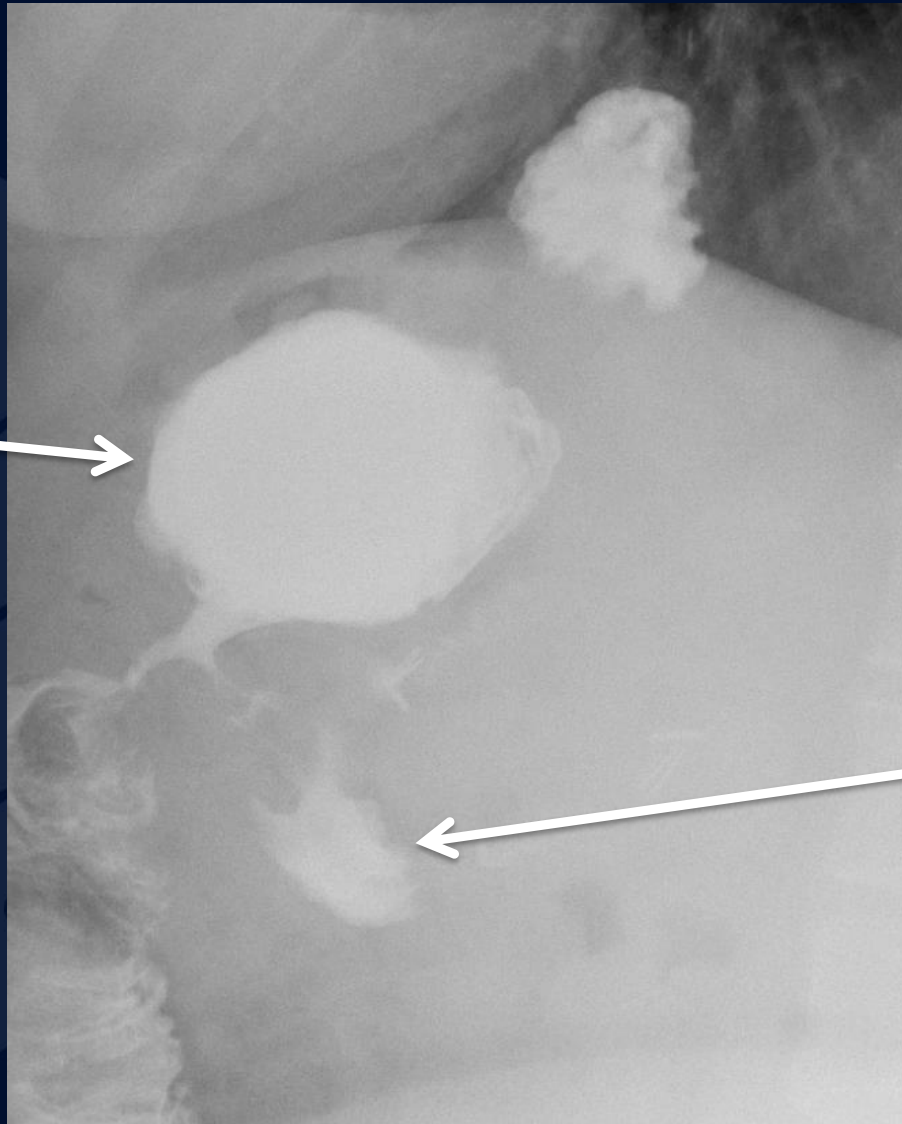


Jejunum



Oblique Fluoroscopy

Gastric  
Pouch



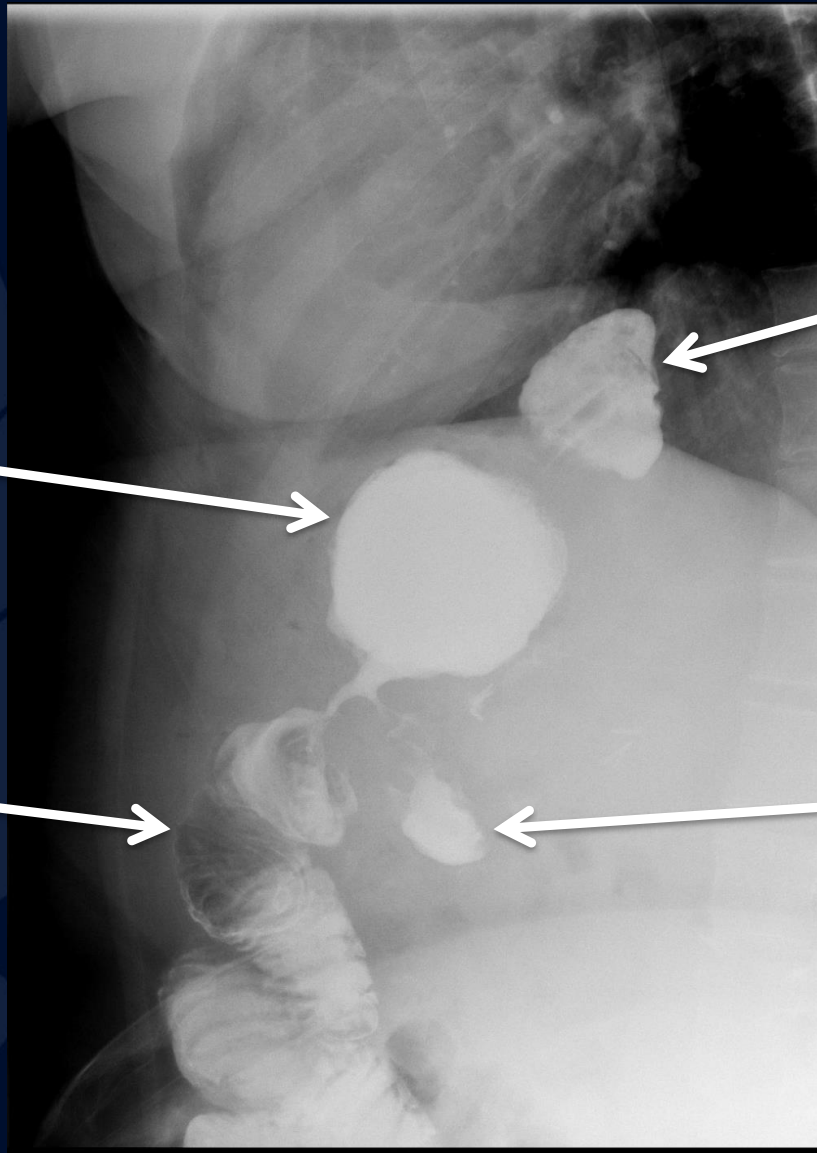
Jejunum

Lateral Fluoroscopy

A large, stylized oak leaf graphic in a dark blue color, positioned on the left side of the slide. The leaf has a prominent central vein and several smaller veins branching off it. The leaf's edge is serrated.

?

# Gastrojejunostomy Anastomotic Stricture



Gastric Pouch

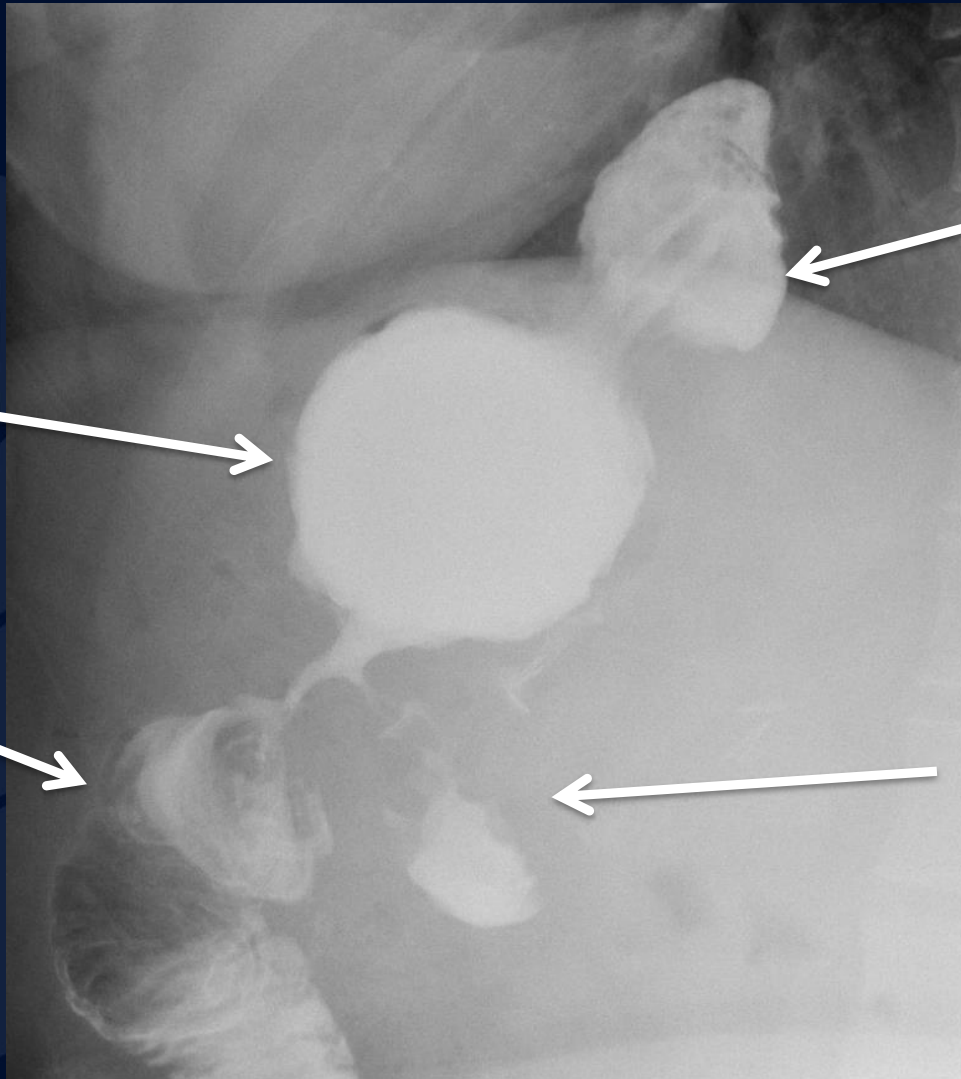
Hiatal hernia

Roux jejunal limb

Blind end of Roux limb

Lateral Fluoroscopy





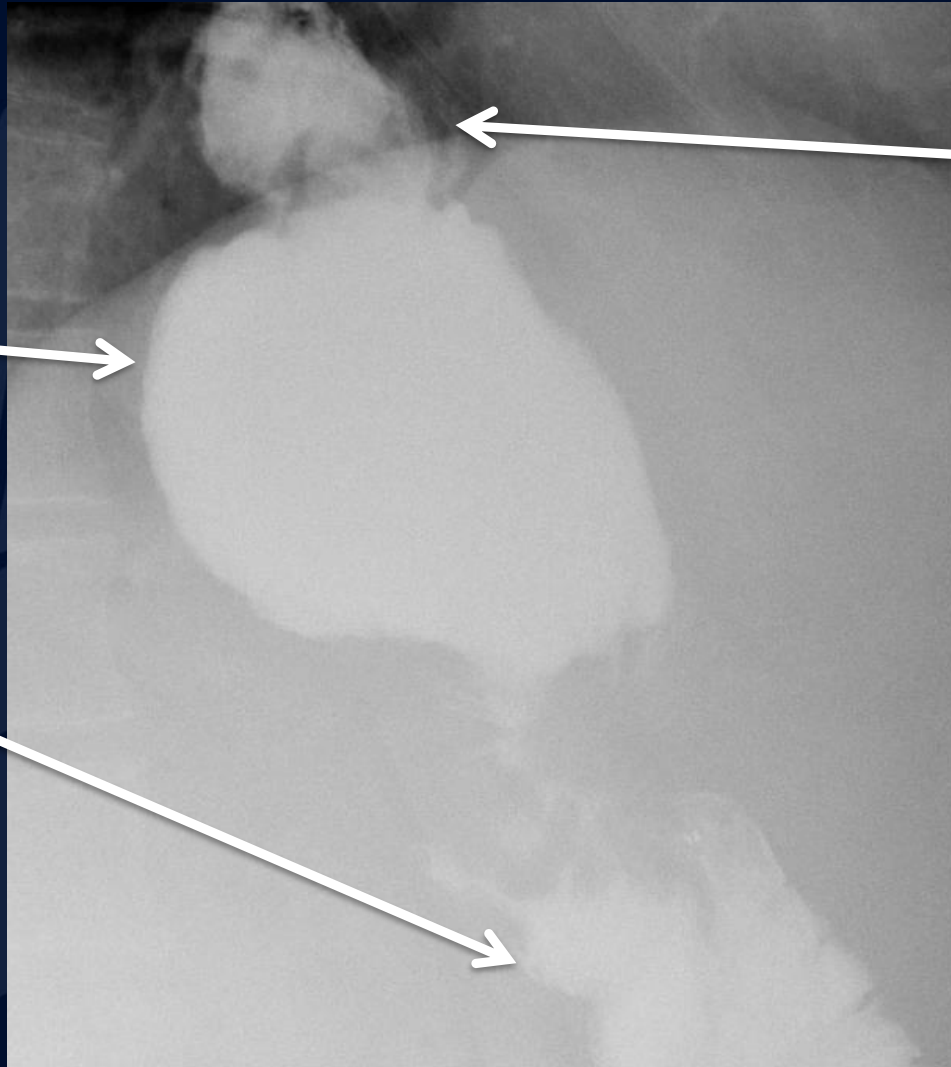
Gastric Pouch

Hiatal hernia

Roux jejunal limb

Blind end of Roux limb

Lateral Fluoroscopy

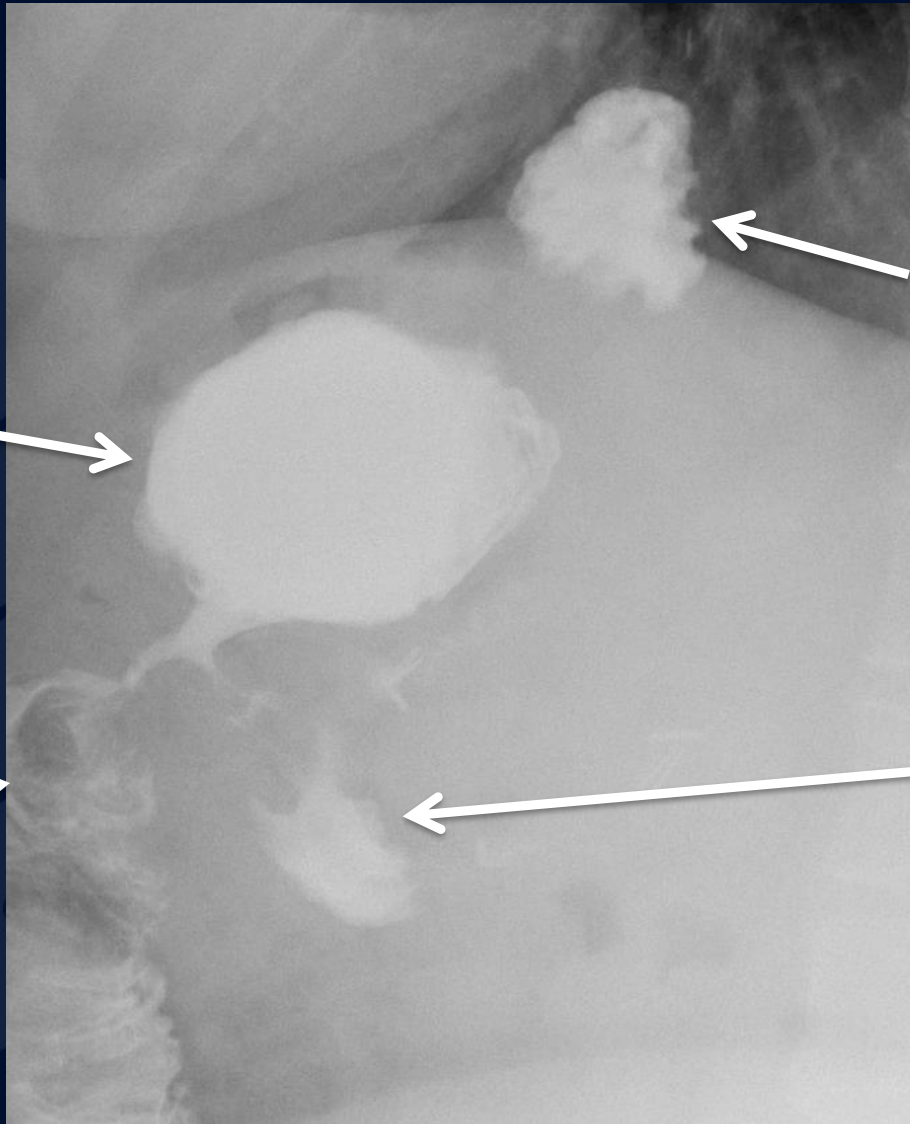


Hiatal hernia

Gastric Pouch

Roux jejunal limb

Oblique Fluoroscopy



Gastric Pouch

Hiatal hernia

Roux jejunal limb

Blind end of Roux limb

Lateral Fluoroscopy

# Bariatric Surgery and Complications

- Types of bariatric surgery
  - Laparoscopic gastric banding
  - Sleeve gastrectomy
  - Roux-en-Y gastric bypass
- Common complications of Roux-en-Y gastric bypass
  - Approximately 10% of cases will have GI complications
  - Spasm (early complication) vs stricture (late complication) of GJ junction
    - Dilatation of gastric pouch with slow emptying
  - Anastomotic leak
    - Early complication detected at routine upper GI procedure
    - Often controlled with surgical drain
  - Marginal ulcer
    - Ulcer near gastrojejunal anastomosis
    - Collection of contrast with adjacent mucosal thickening
  - Gastrogastric fistula
    - Contrast entering gastric remnant via gastric pouch
  - Small bowel obstruction
    - Due to adhesions or internal hernias