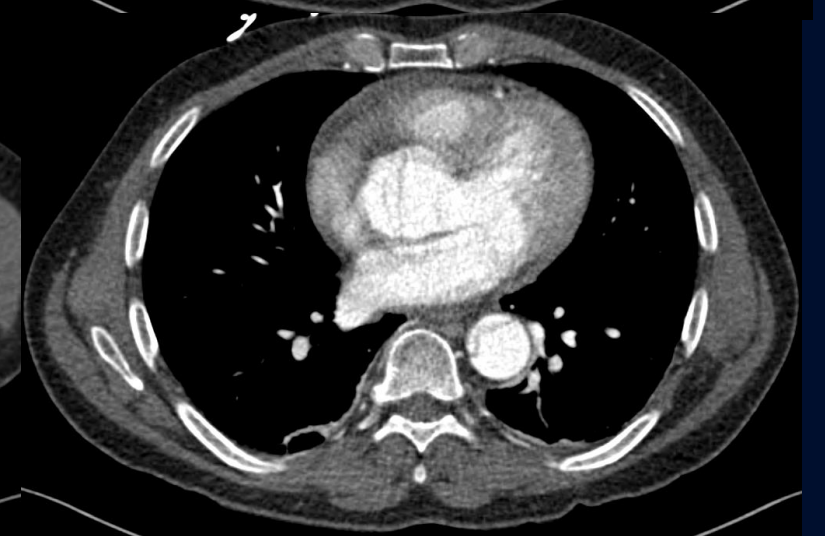
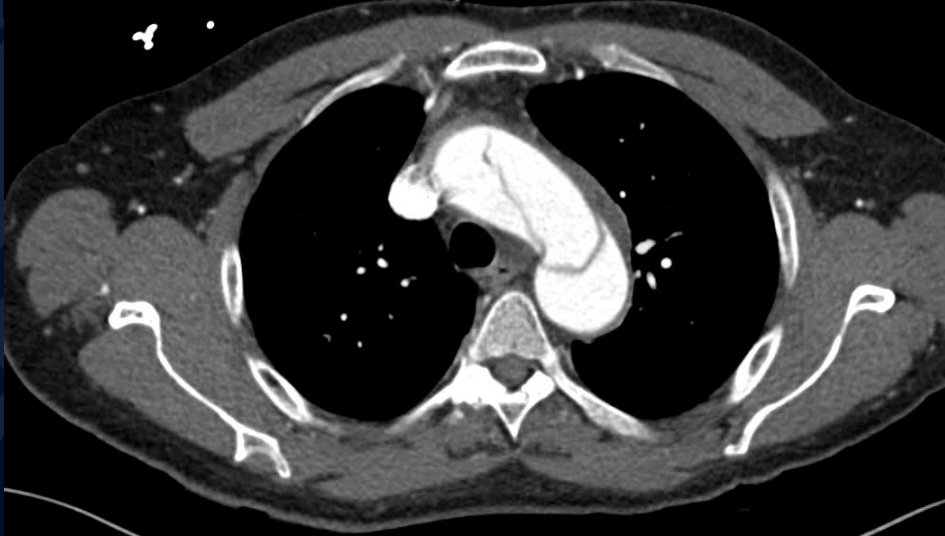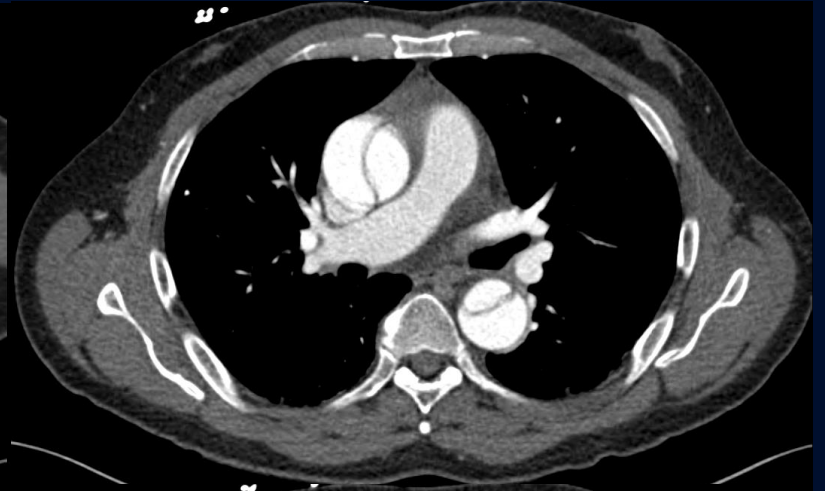
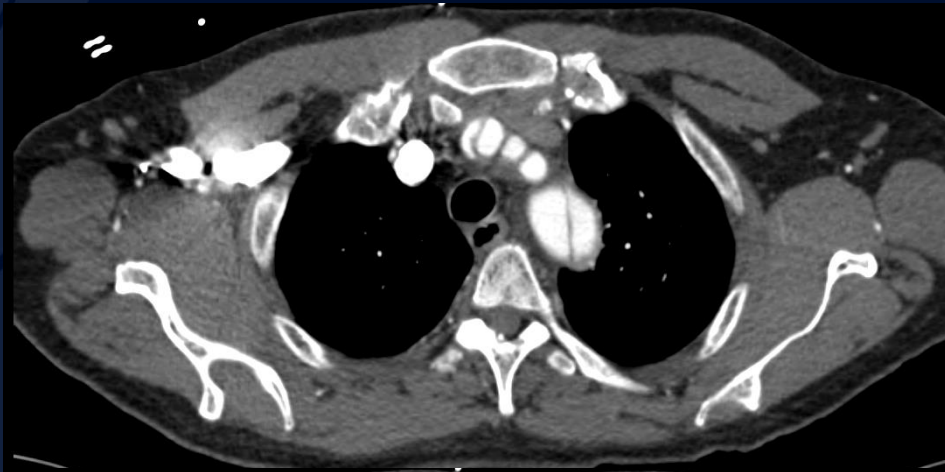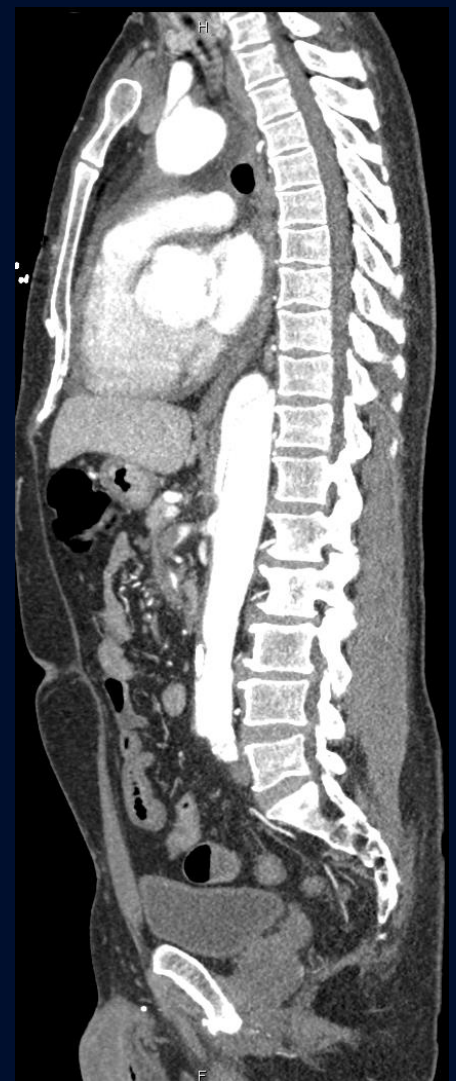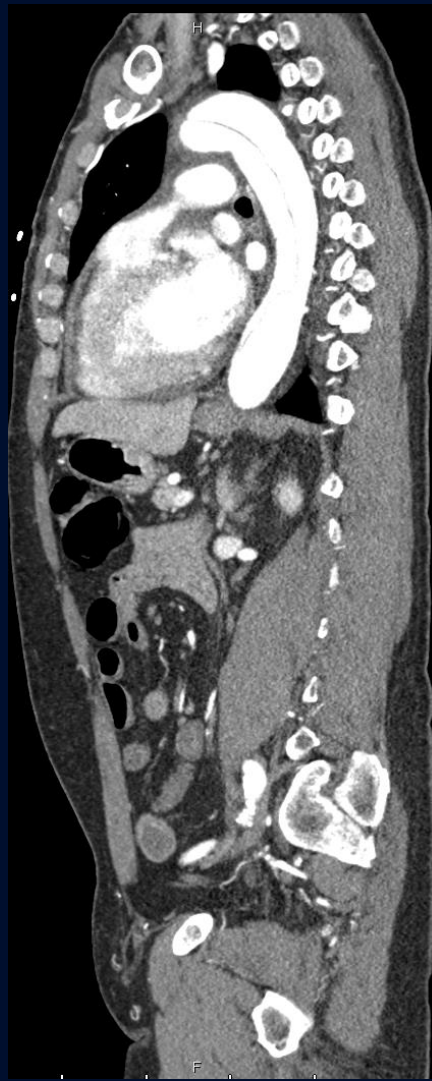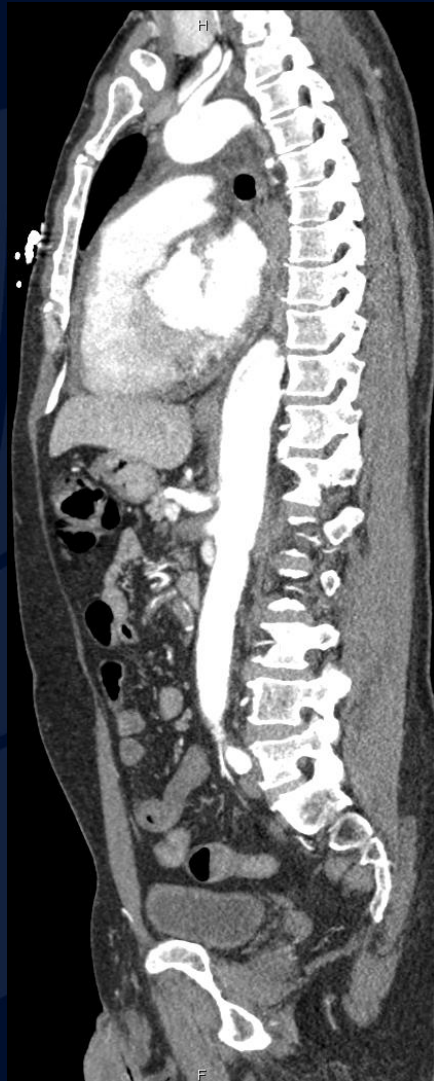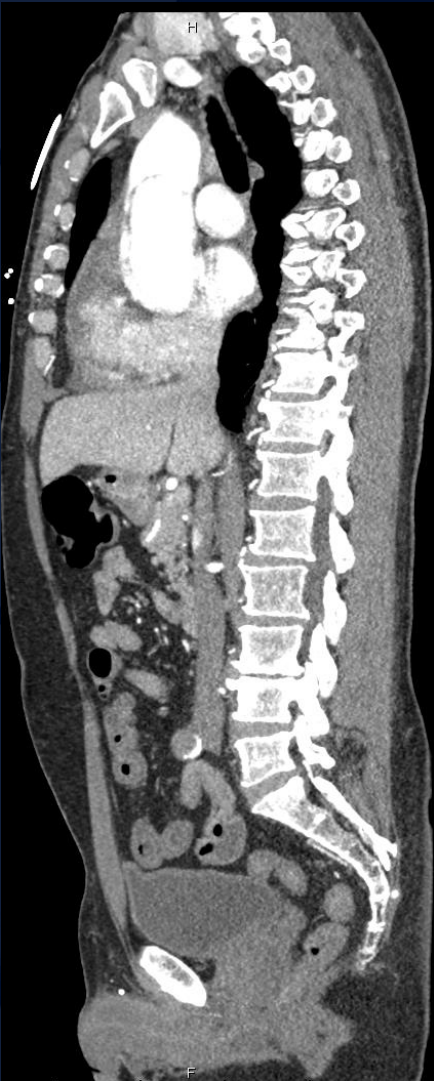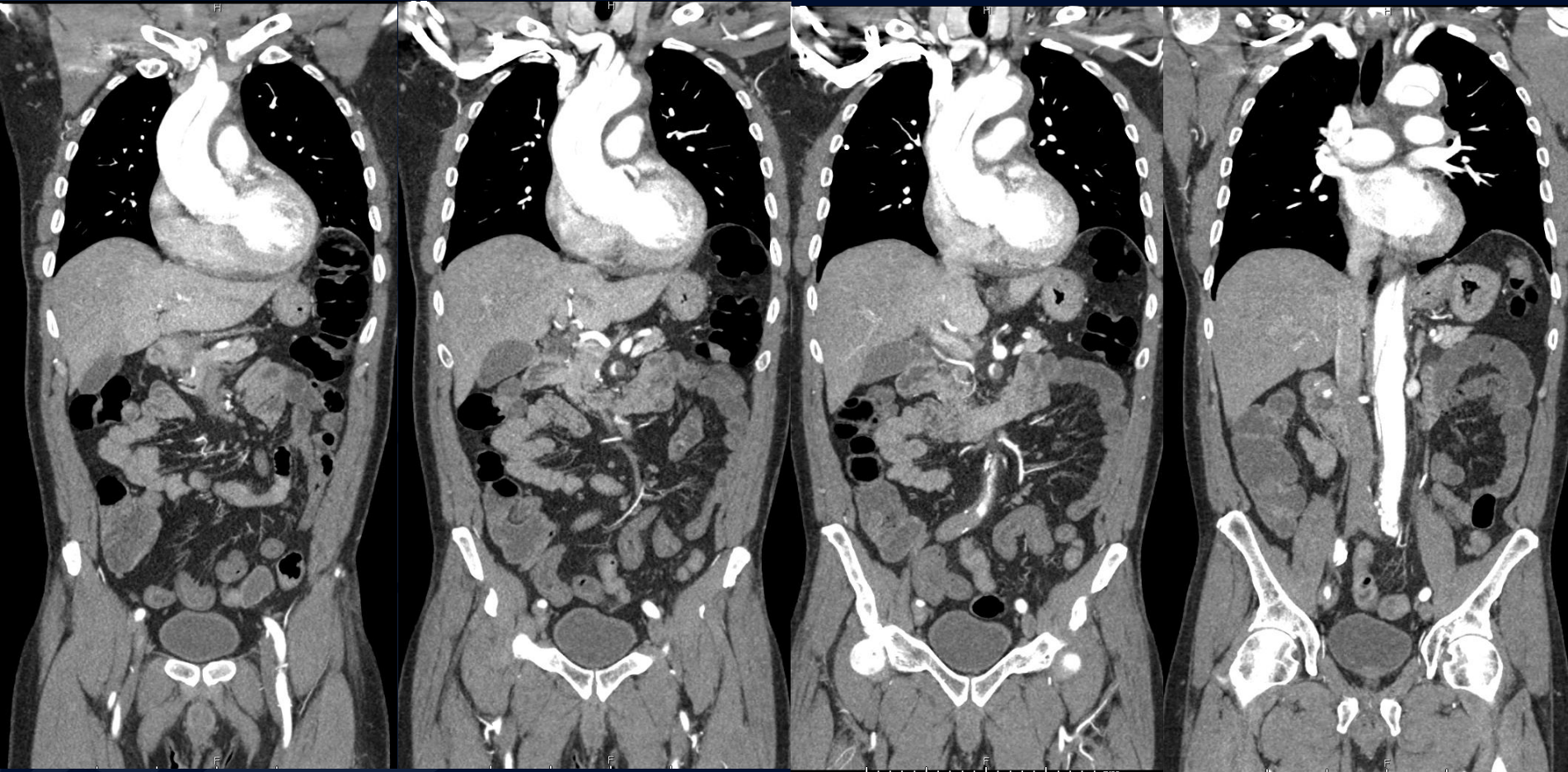


Patient is a 57 yo male who was admitted with chest pain which started abruptly, right lower extremity numbness and bright red blood per rectum.

Elena G. Violari M.D.



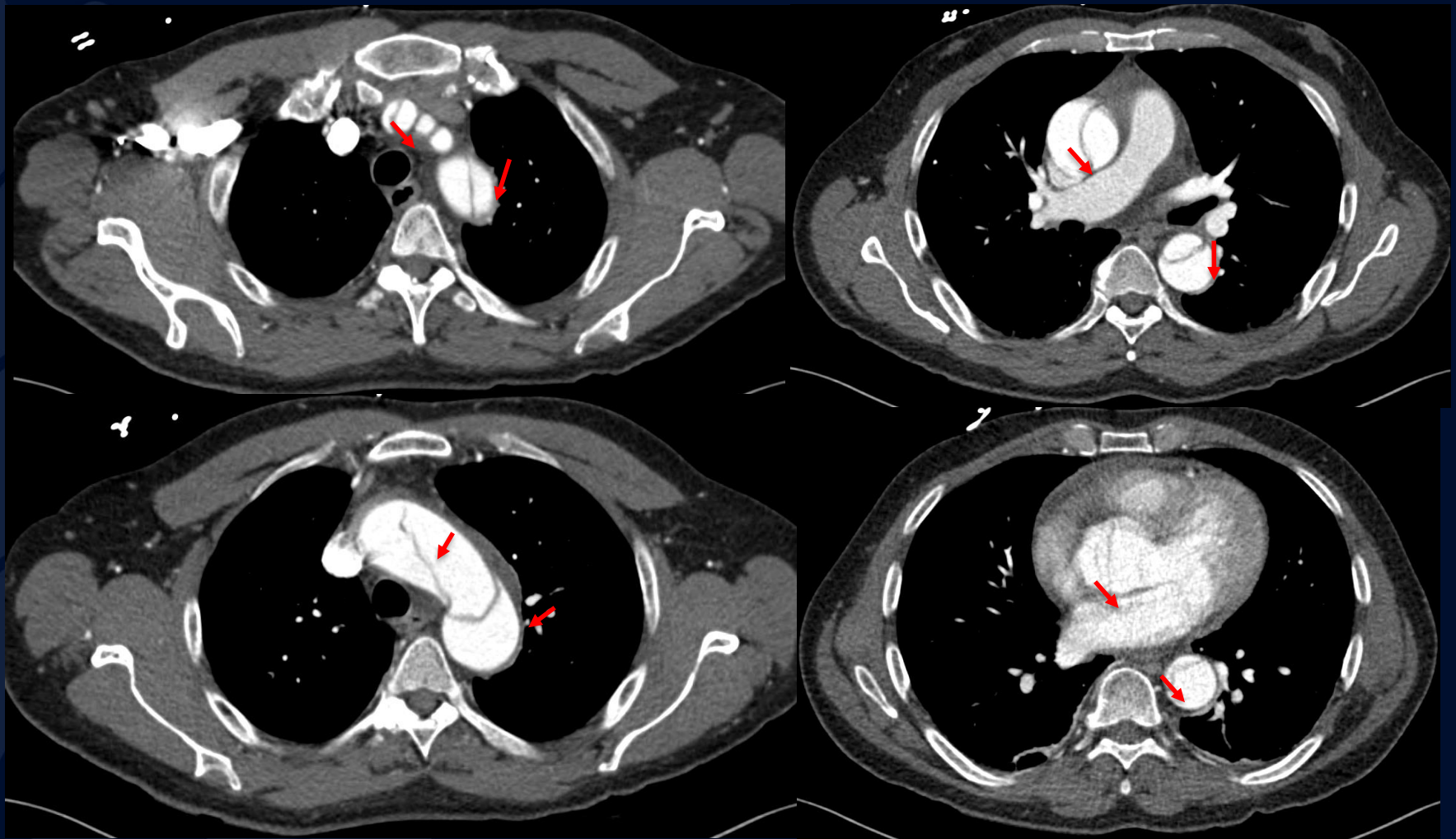




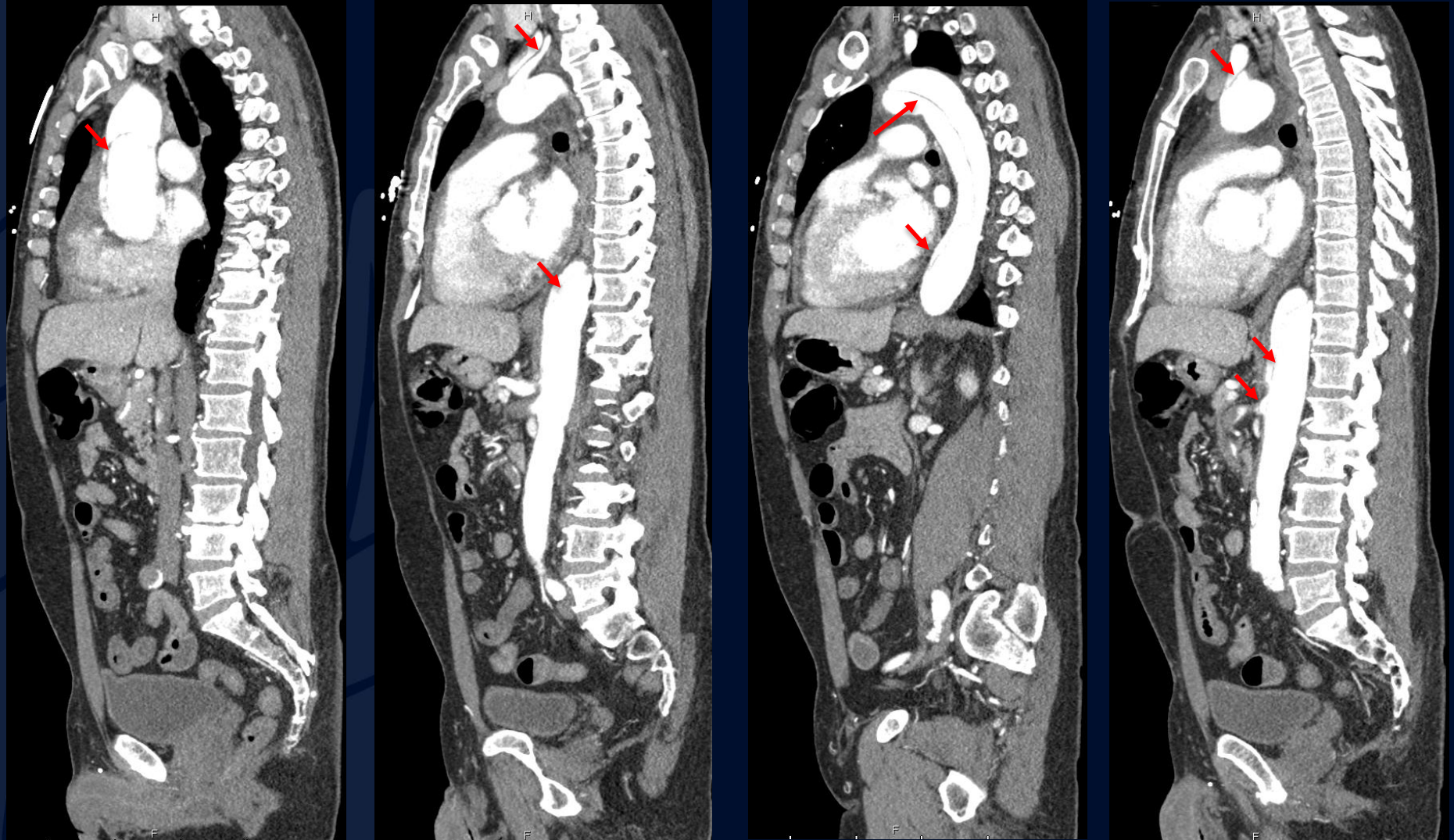


?

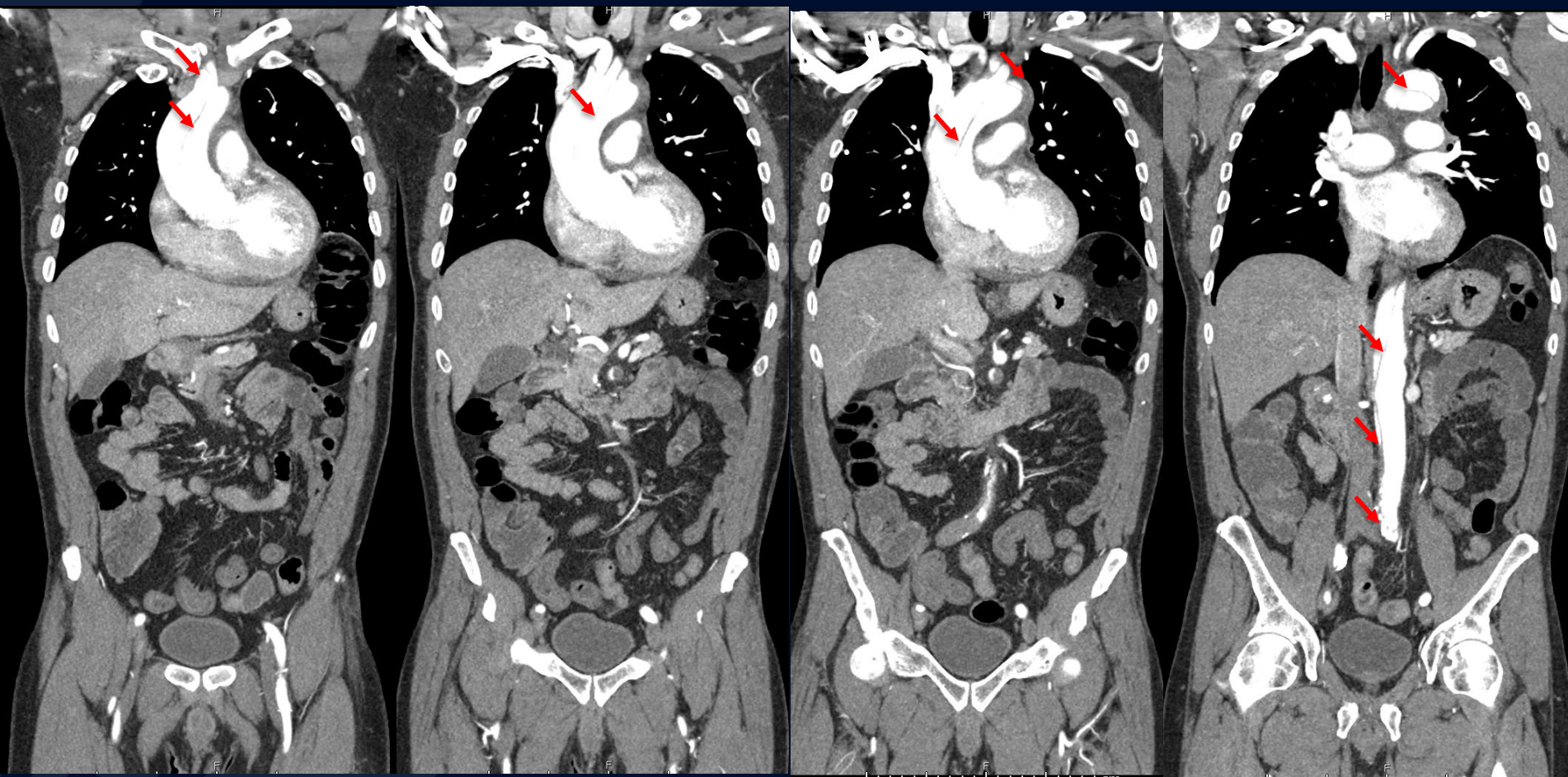
Aortic Dissection, Stanford Type A



Type A thoracic aortic dissection, commencing at the level of the aortic root. Dissection does extend into the origin of the brachiocephalic artery as well as within the origin of the left common carotid artery with significant narrowing at the origin of the left common carotid artery.



The thoracic aortic dissection extends into the abdominal aorta and involves the celiac and superior mesenteric arteries. The inferior mesenteric artery is patent. The bilateral renal arteries appear patent.



The dissection does extend inferiorly and involves the right common iliac artery which demonstrates near-complete occlusion proximally. This dissection continues along in the right external iliac artery which is significantly narrowed. The left external iliac artery is patent. Bilateral internal iliac arteries appear patent.

Aortic Dissection

Definition:

Most common form of the acute aortic syndrome (70%) and is most commonly caused by hypertension (70%). It occurs when blood enters the medial layer of the aortic wall through a tear or penetrating ulcer in the intima and tracks along the media, forming a second blood-filled channel within the wall.

Epidemiology

The majority of aortic dissections are seen in elderly hypertensive patients. In a very small minority, an underlying connective tissue disorder may be present. Other conditions / predisposing factors include:

- Structural aortic abnormalities
 - Bicuspid aortic valve
 - Aortic coarctation
 - Abnormal connective tissues
 - Marfan syndrome
 - Ehlers-Danlos syndrome
- Turner syndrome
- Pregnancy
- Intra-aortic balloon pumps

Aortic Dissection

Two general ways to **classify** aortic dissection:

1. **Time:** Acute (< 2 weeks), or Chronic

2. **Location:**

- **Stanford A:** Account for 75% of dissections and involves the ascending aorta and arch proximal to the take-off of the left subclavian (treated surgically).
- **Stanford B:** Occur distal to the take-off of the left subclavian and are treated medically unless there is complication (organ ischemia)

Clinical presentation:

1. Patients are often hypertensive and present with anterior or posterior chest pain and a tearing sensation in the chest.
2. Depending on the extent of dissection and occlusion of aortic branches, end organ ischemia may also be present (seen in up to 27% of cases) 5, including:
 - Abdominal organ ischemia
 - Limb ischemia
 - Ischemic or embolic stroke
 - Paraplegia: involvement of the artery of Adamkiewicz
 - Coronary artery involvement may result in collapse and death. Symptoms of cardiac tamponade (Beck's triad) may also be encountered.

Aortic Dissection

Plain radiograph:

- Widened mediastinum (more than 8 cm at the level of the aortic knob)
- Double aortic contour
- Irregular aortic contour
- Inward displacement of atherosclerotic calcification (more than 1 cm from the aortic margin)

CT / CT angiography:

Study of choice, to diagnose classify and evaluate for distal complications with Sensitivity and Specificity of ~100%

- Intimal flap
- Double lumen
- Mercedes-Benz sign in the case of a "triple-barreled" dissection
- Windsock sign
- Important to identify the true lumen!!! (placement of a stent graft in the false lumen can have dire consequences).
- Chronic dissection flaps are often thicker and straighter than those seen in acute dissections.

MRI / MR Angiography:

- MRA has been reserved for follow-up examinations, rapid non-contrast imaging techniques (e.g. true FISP) may see MRI having a larger role to play in the acute diagnosis, particularly in patients with impaired renal function.
- Limited availability with difficulties inherent in performing MRI on acutely unwell patients.

DSA - Angiography:

- Historically been the gold standard investigation.
- CTA has now replaced it, not only due to it being non-invasive but also on account of better delineation of the poorly opacifying false lumen, intramural hematoma and end-organ ischemia.
- Angiography is required for endoluminal repair.
- Risk of catheterizing the false lumen and causing aortic rupture

Aortic Dissection

True Lumen	False Lumen
Continuity with undirected portion of aorta	"CobWeb Sign"- slender linear areas of low attenuation
Smaller cross sectional areas (with higher velocity blood)	Larger cross sectional area (slower more turbulent flow)
Surrounded by calcifications (if present)	Beak sign
Usually contains the origin of celiac trunk, SMA and RIGHT artery	Usually contains the origin of LEFT renal artery
	Surrounds true lumen in Type A Dissection

Aortic Dissection

Treatment:

Stanford type A: Surgical

Stanford type B: Medical with aggressive blood pressure control with beta blockers as they reduce both blood pressure and also heart rate hence reduce extra pressure on the aortic wall OR Surgical if abdominal organ ischemia or persistent pain.

Complications:

- Dissection and occlusion of branch vessels
 - abdominal organ ischemia
 - limb ischemia
 - ischemic stroke
 - paraplegia: involvement of artery of Adamkiewicz
- Distal thromboembolism
- Aneurysmal dilatation: this is an indication for endovascular or surgical intervention
- Aortic rupture

A type A dissection may also result in:

- coronary artery occlusion
- aortic incompetence
- rupture into pericardial sac with resulting cardiac tamponade

Although the combination of blood pressure control and surgical intervention has significantly lowered in hospital mortality, it remains significant, at 10-35%.

References

1. Macura KJ, Corl FM, Fishman EK et-al. Pathogenesis in acute aortic syndromes: aortic dissection, intramural hematoma, and penetrating atherosclerotic aortic ulcer. *AJR Am Roentgenol*. 2003;181 (2): 309-16. doi:10.2214/ajr.181.2.1810309 -
2. Sebastià C, Pallisa E, Quiroga S et-al. Aortic dissection: diagnosis and follow-up with helical CT. *Radiographics*. 1999;19 (1): 45-60. doi:10.1148/radiographics.19.1.g99ja0945
3. Small JH, Dixon AK, Coulden RA, Flower CDR, Housden BA. *Fast CT for aortic dissection. Br J Radiol* 1996; 69:900-905.
4. Daily PO, Truebold HW, Stinson EB, Wuerfflein RD, Shumway EN. *Management of acute aortic dissections. Ann Thorac Surg* 1970; 10:237-247.
5. Prete R, Von Segesser LK. *Aortic dissection. Lancet* 1997; 349:1461-1464.