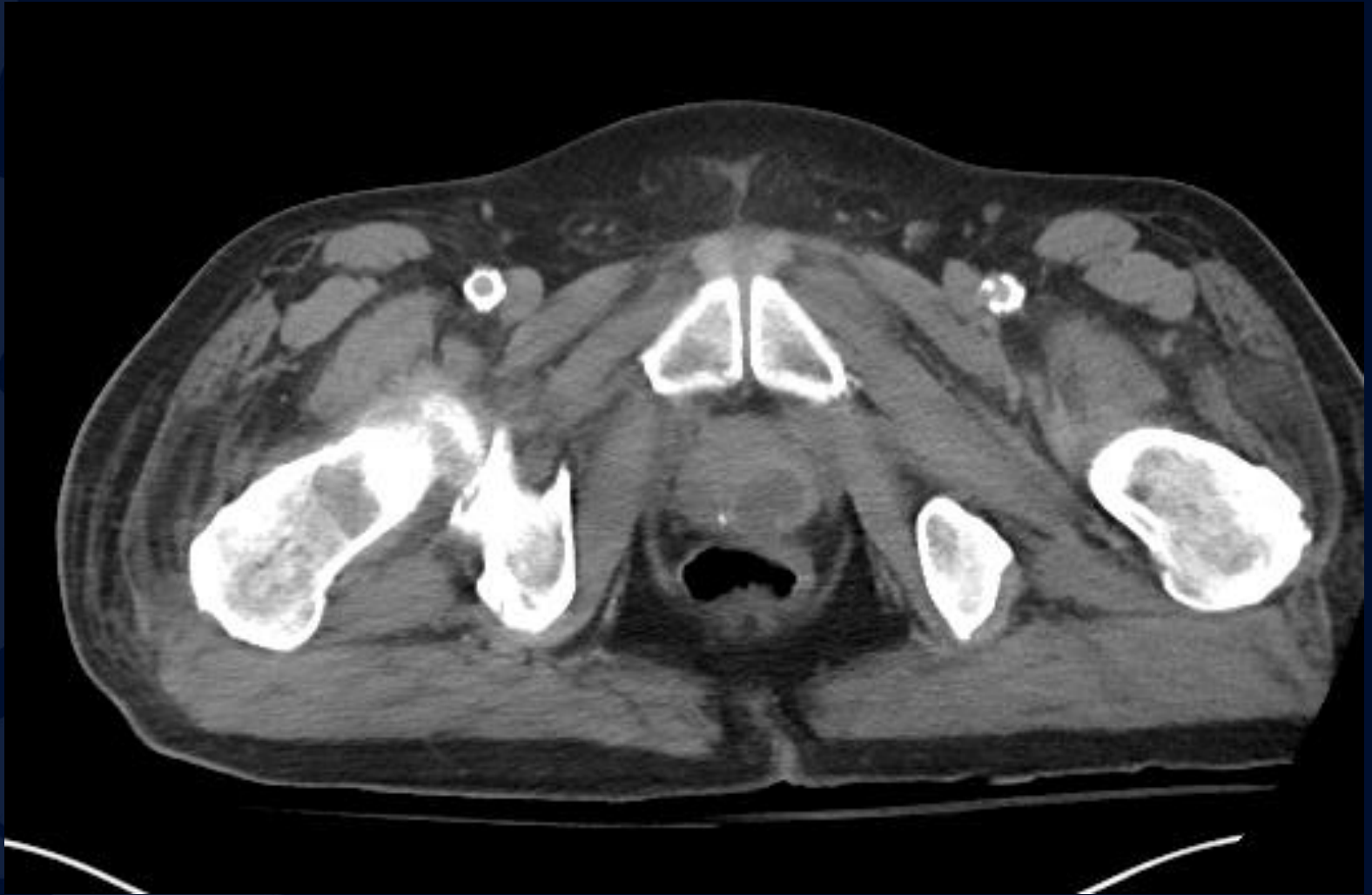
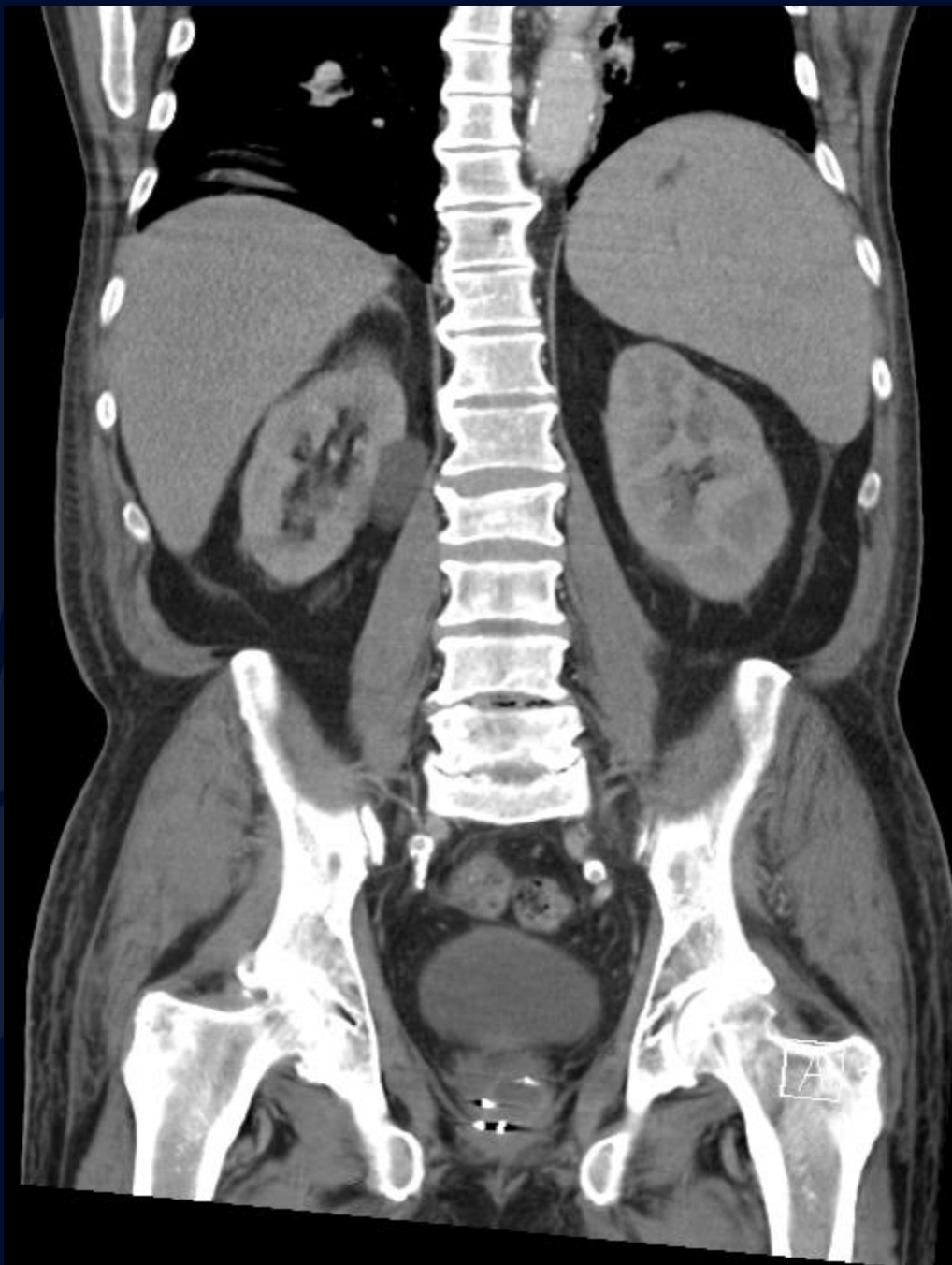
81M abdominal pain, fever of unknown origin, neutropenia

Krithika Srikanthan, MD

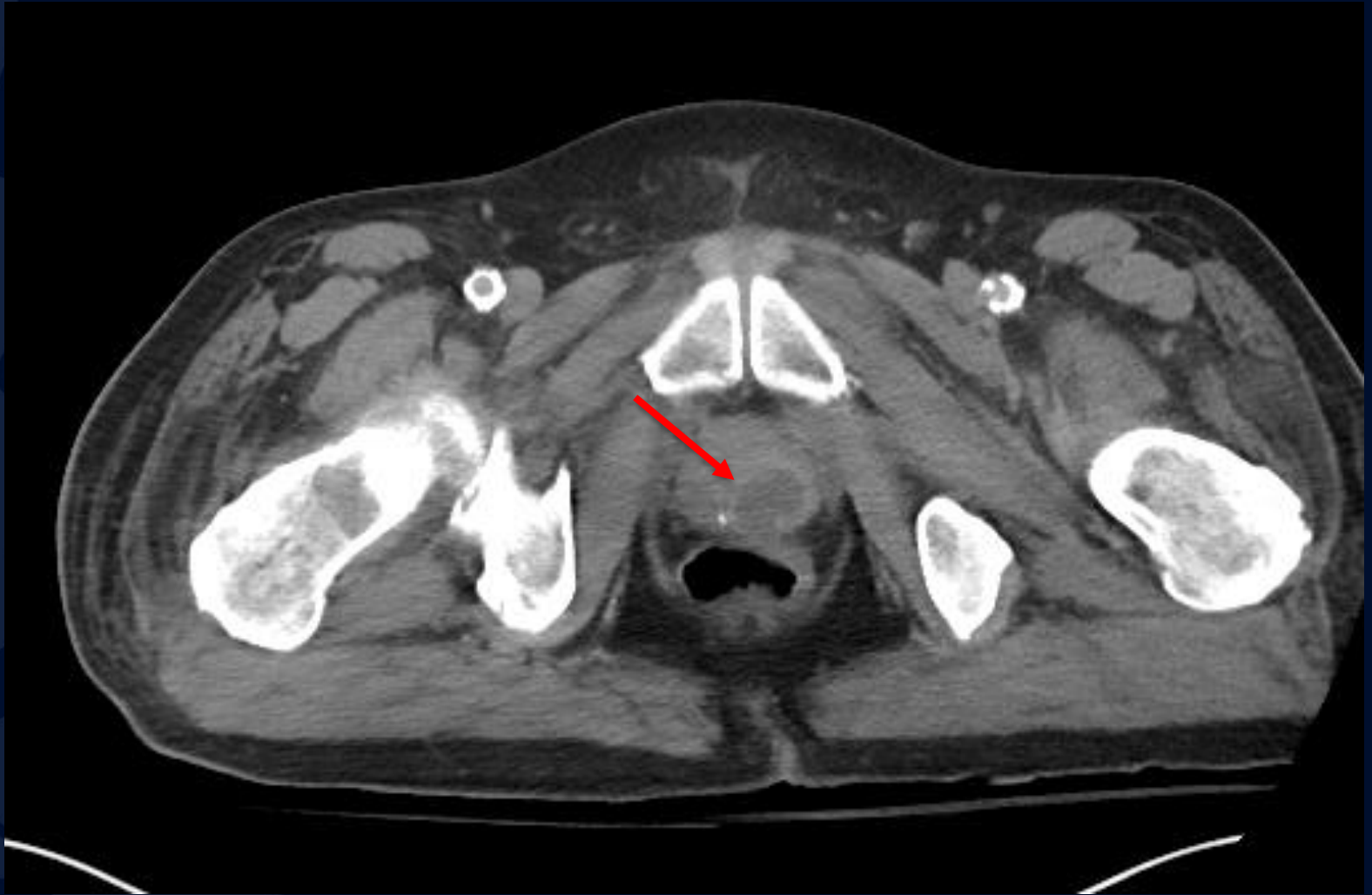

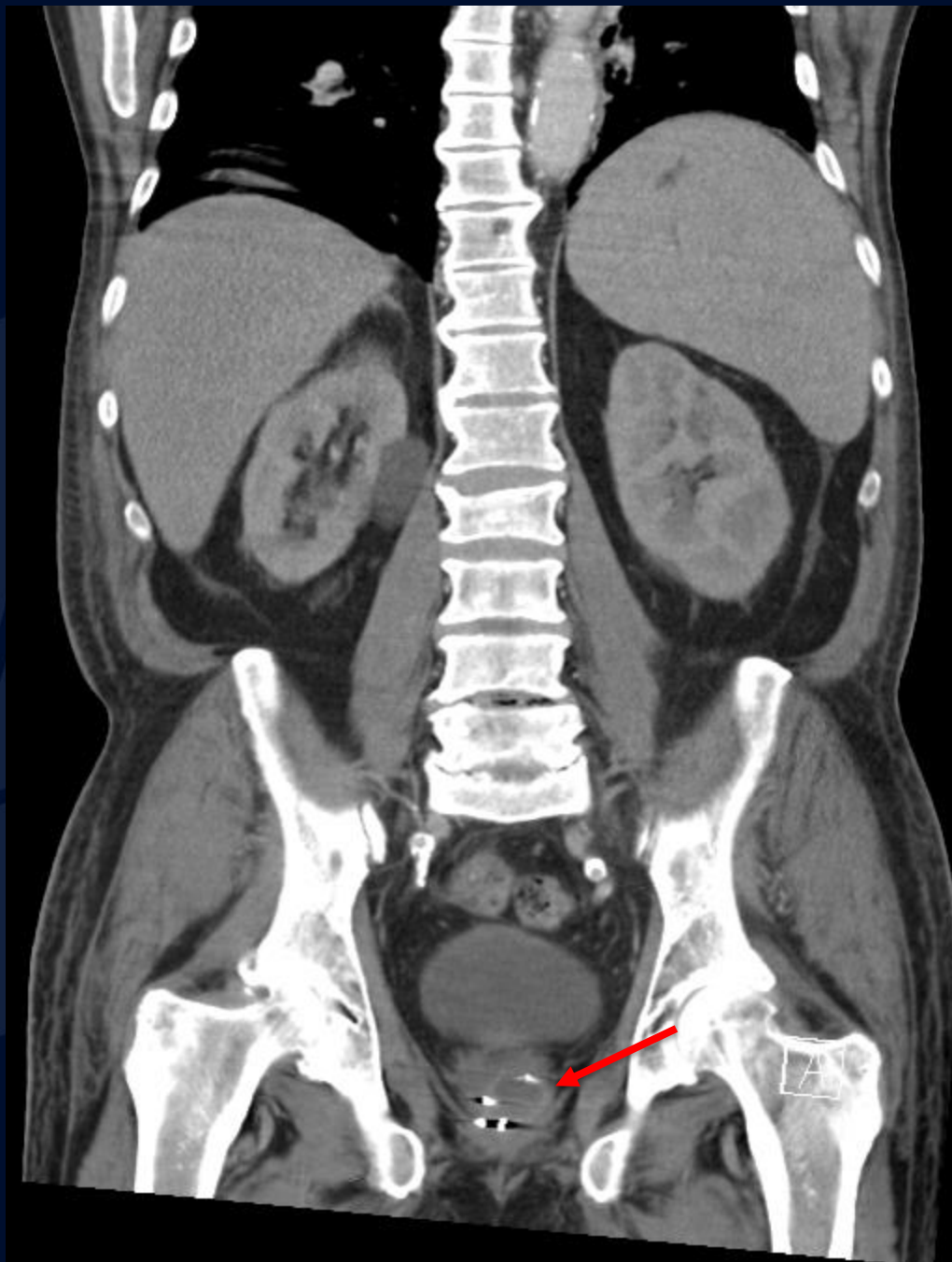




?

Prostate Abscess





Imaging Findings

- Rim-enhancing, unilocular or multilocular, low-attenuation mass in prostate
 - More commonly in peripheral portion of gland
 - Can be central following transurethral prostatectomy
- May extend through capsule into periprostatic tissues, seminal vesicles, peritoneum

Prostate Abscess

- Predisposing risk factors
 - Bladder outlet obstruction due to benign prostatic hyperplasia
 - Prior instrumentation
 - Chronic indwelling bladder catheters
 - Immunocompromised states, such as diabetes mellitus
- Rare as abx early reduces complications of prostatitis
 - Diagnosed in 0.2% of patients with urologic symptoms
 - Diagnosed in 0.5-2.5% patients hospitalized for prostatic symptoms
- Escherichia coli and Staphylococcus
- Rx: Antibiotics, Abscess drainage may be necessary

References

1. Statdx
2. <http://www.ajronline.org/doi/abs/10.2214/ajr.170.3.9490969>