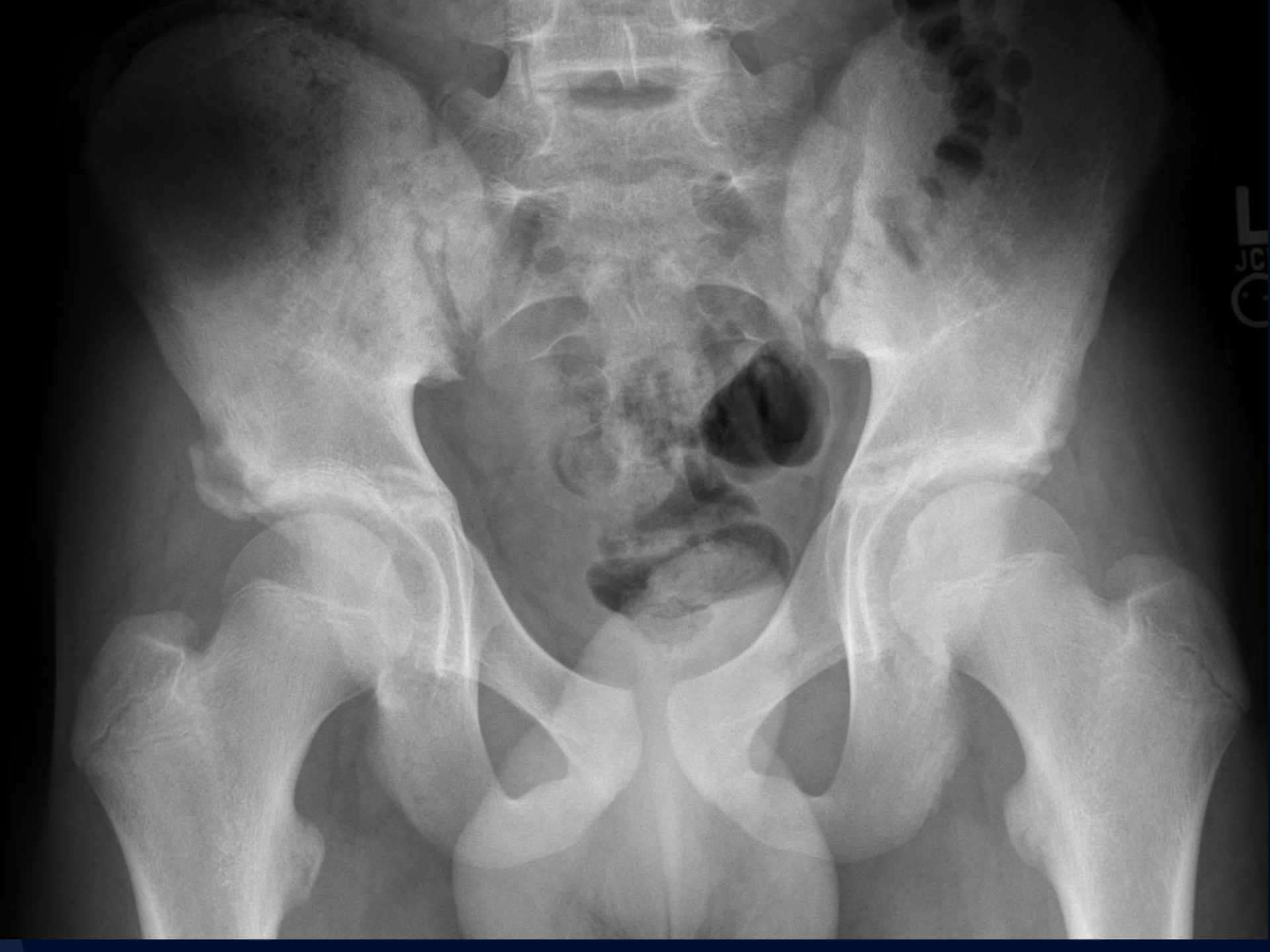

12 year old male with right hip pain

Jeffrey Guzelian, MD

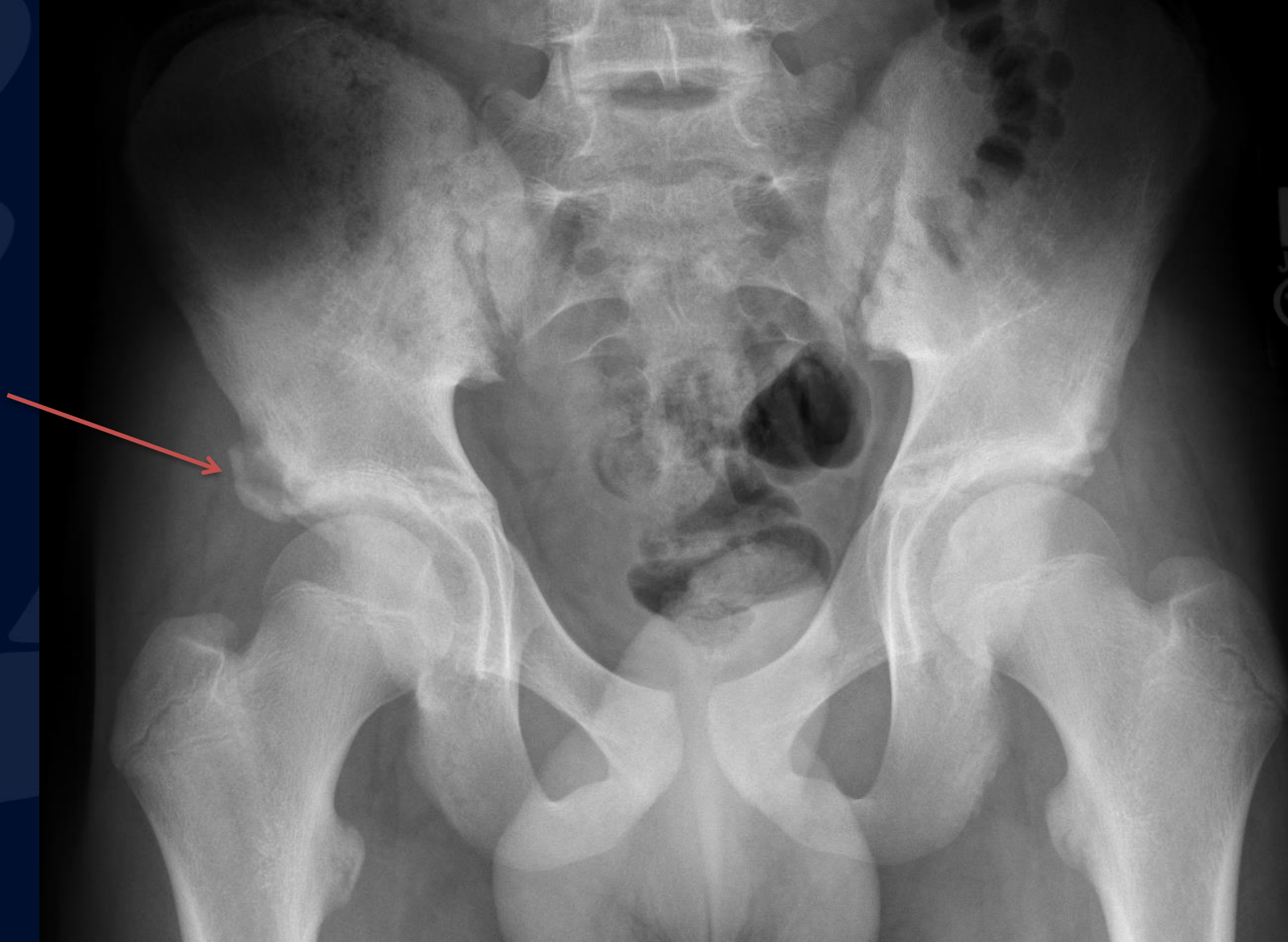


A large, stylized oak leaf graphic in a dark blue color, positioned on the left side of the slide. It features detailed vein patterns and a lobed edge.

?

Anterior Inferior Iliac Spine Avulsion

Avulsion fracture of the right anterior inferior iliac spine (arrow)



Anterior inferior iliac spine avulsion

- Tendon avulsion of the rectus femoris direct head at its origin on the AIIS
- Most common in male athletes 14-17 (kicking sports)
- Due to hip hyperextension
- One of the pelvic apophyseal avulsion injuries
- Usually managed conservatively
- DDx: heterotopic ossification, osteosarcoma, osteochondroma