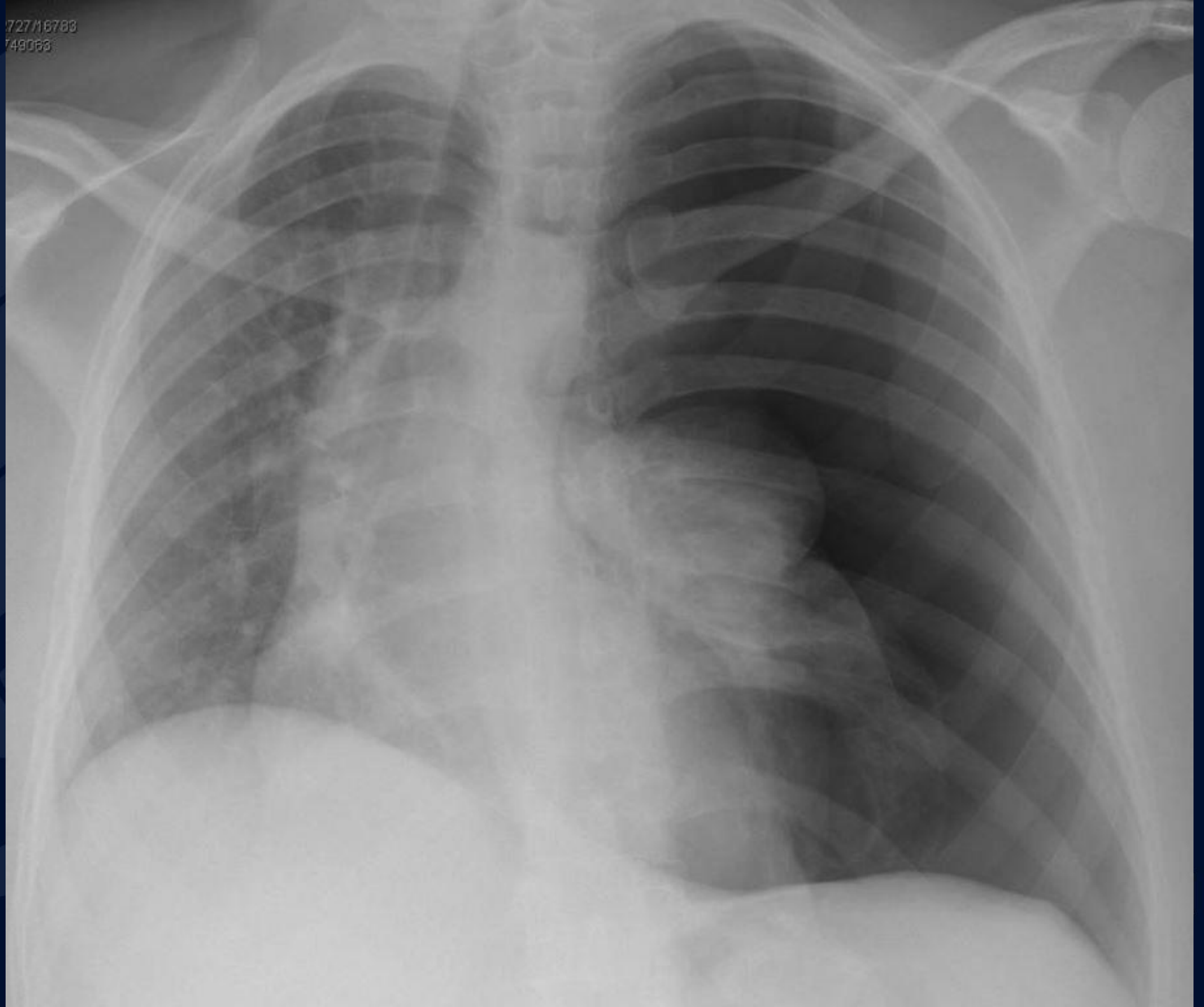


40F with epigastric pain

Jeffrey Guzelian, MD

72716788
749066

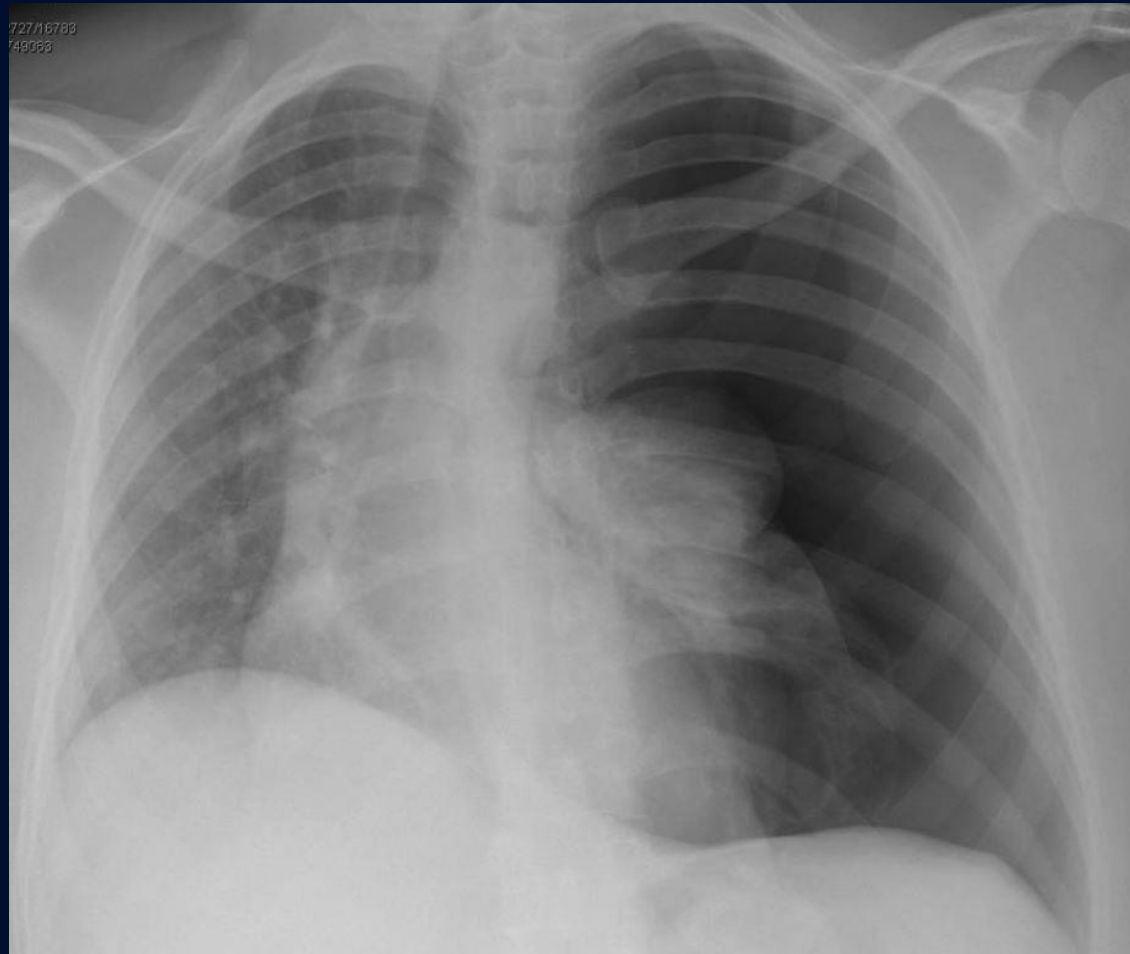


A large, stylized oak leaf graphic in a dark blue color, positioned on the left side of the slide. The leaf has a prominent central vein and several smaller veins branching off it. The leaf's edge is serrated.

?

Tension Pneumothorax

- Large left pneumothorax
- Contralateral shift of mediastinum
- Depression of left hemidiaphragm



Tension Pneumothorax

- Progressive accumulation of air in pleural space secondary to unidirectional ventilation
- Usually due to trauma, can be spontaneous eg bleb rupture
- Increased risk with positive pressure ventilation
- Buildup of pressure within pleural space compresses mediastinal structures
- Can result in circulatory instability, cardiac arrest
2/2 venous obstruction
- Tx: needle thoracotomy for chest decompression, chest tube for lung re-expansion