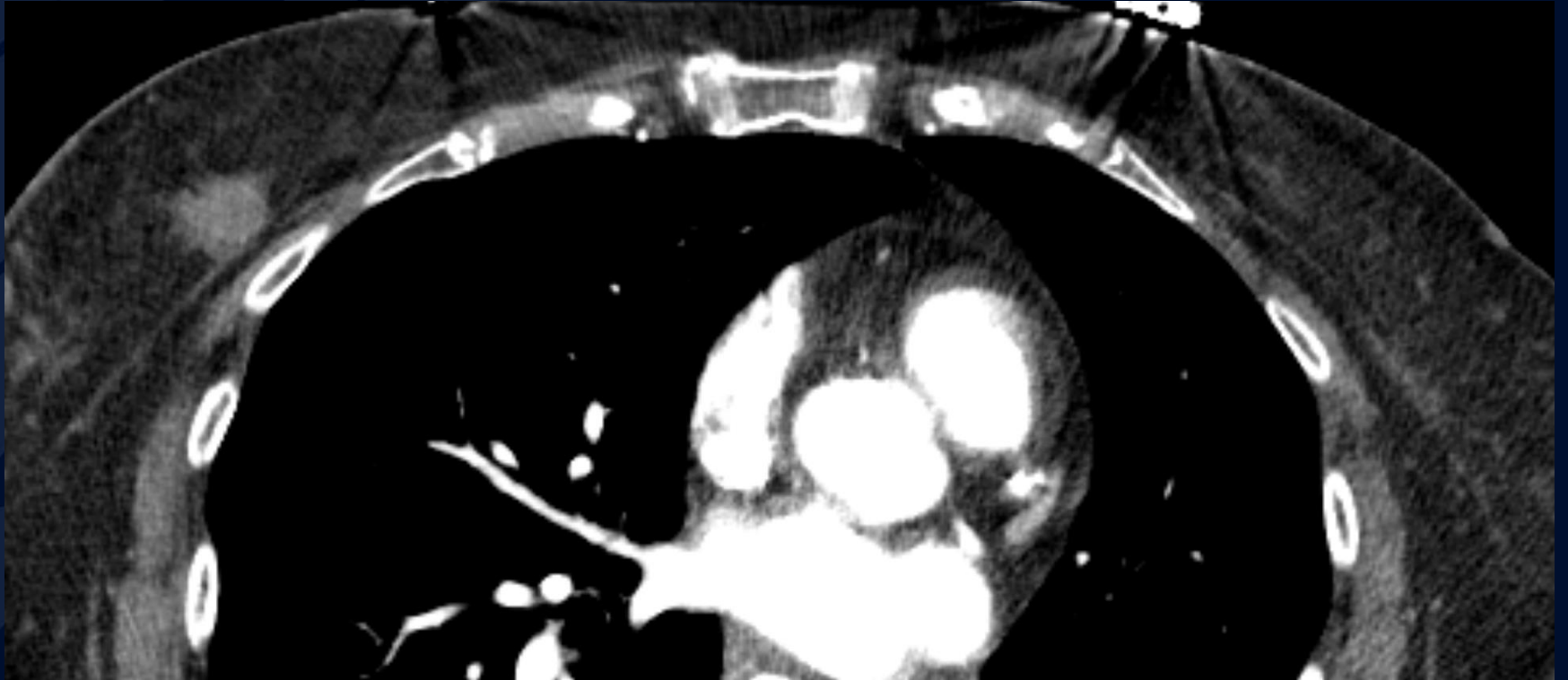


78 y/o F, SOB, incidental right breast finding on CTA chest

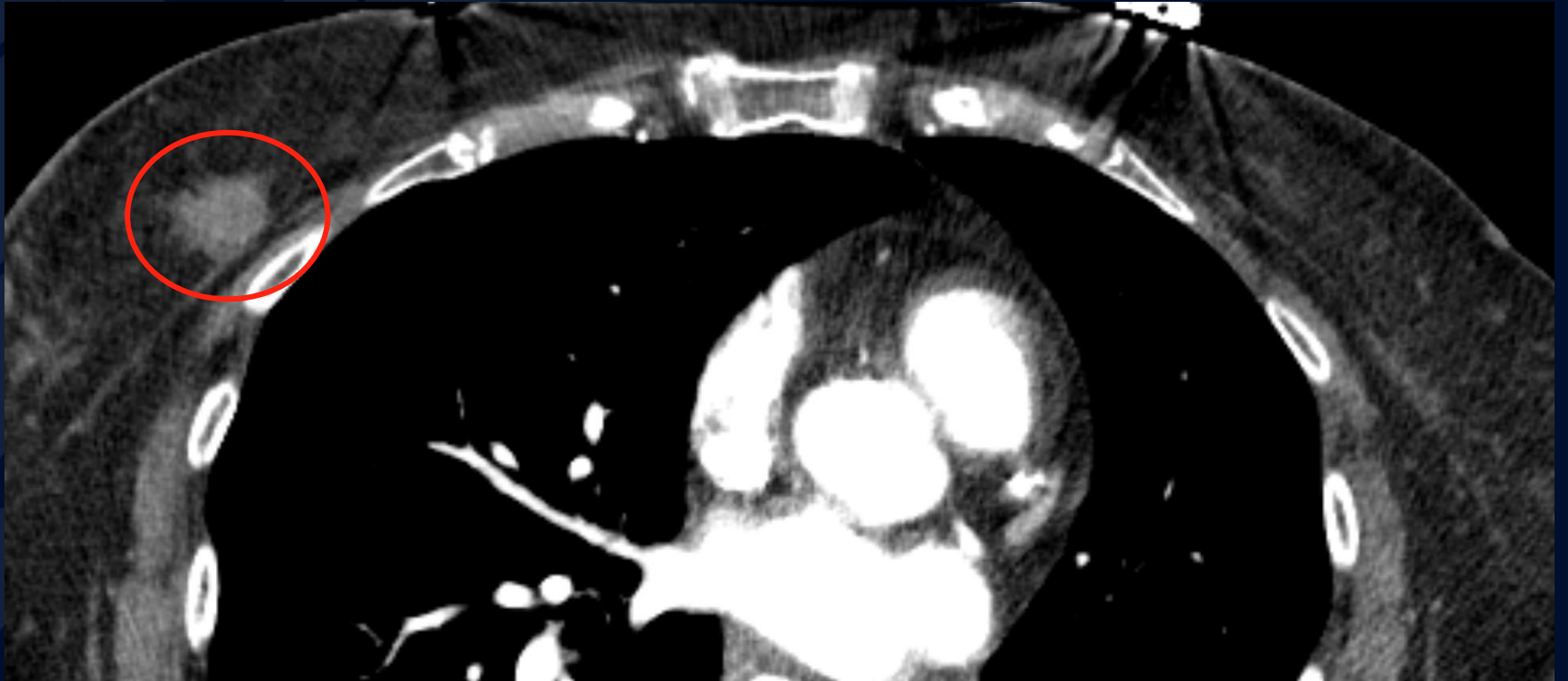
Allan Zhang DO



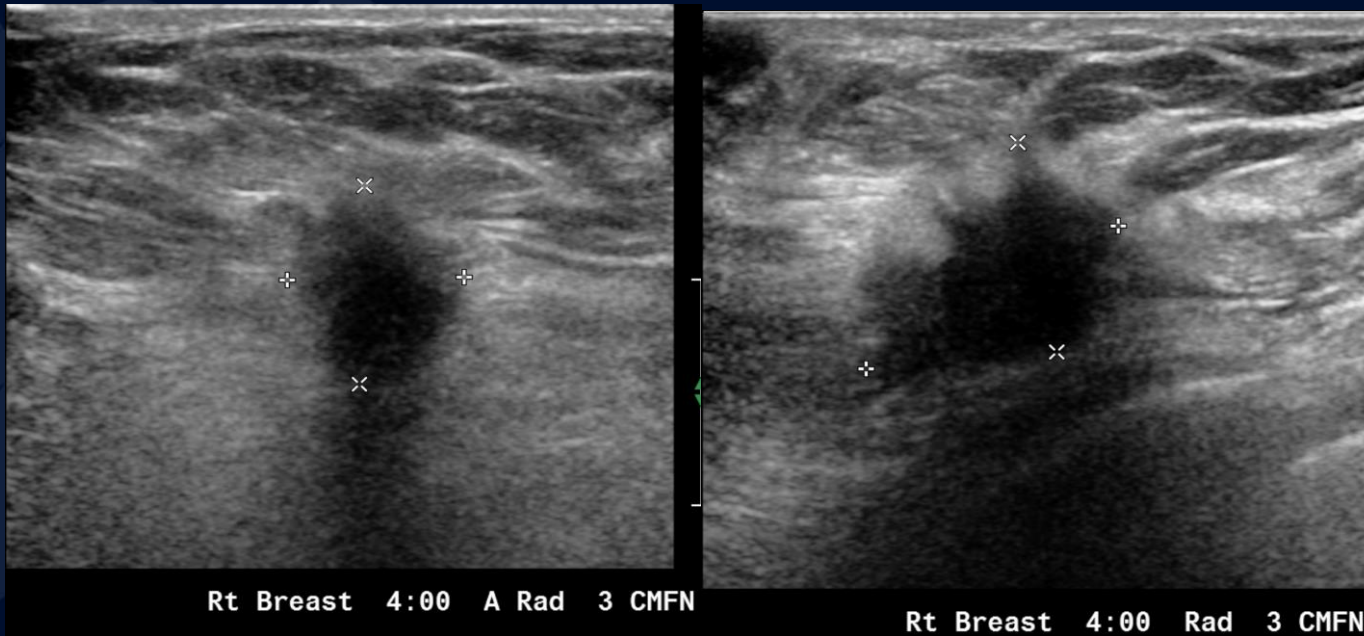
A large, stylized oak leaf graphic in a dark blue color, positioned on the left side of the slide. The leaf has a prominent central vein and several smaller veins branching off, with a scalloped edge.

?

Right breast carcinoma
incidentally noted on CT
angiogram of the chest for
pulmonary embolus



BI-RADS Classification



On ultrasound there is a right breast 4:00 2.2 cm hypoechoic mass with an irregular shape and indistinct margins. This mass is associated with shadowing.

BI-RADS Classification

- Category 0: Incomplete - need additional imaging
- Category 1: Negative
- Category 2: Benign finding(s)
- Category 3: Probably benign finding – short-interval follow-up recommended

BI-RADS Classification

- Category 4: Suspicious abnormality – biopsy recommended
- Category 5: Highly suggestive of malignancy – biopsy or direct surgical treatment recommended
- Category 6: Known biopsy – proven malignancy – appropriate action should be taken