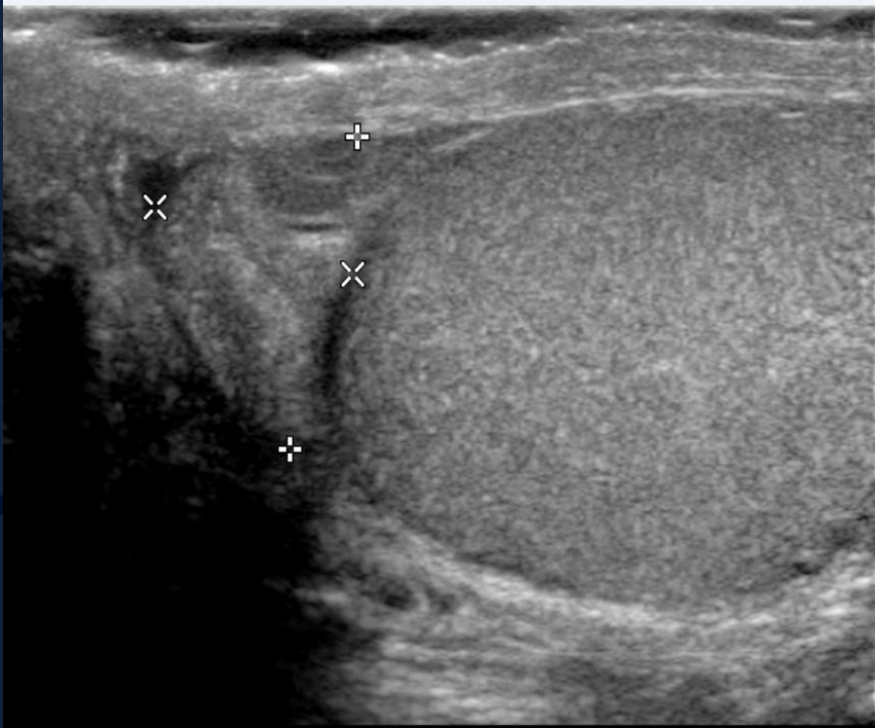
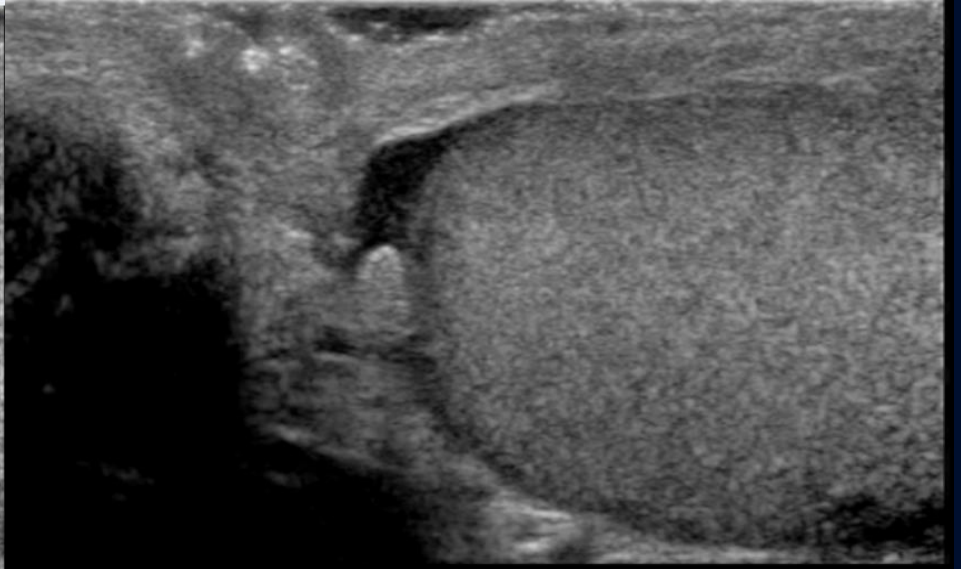


51 year old man, right testicular pain,
currently being treated with
antibiotics for 3 days. Status post left
orchiectomy for a germ cell tumor
performed in 2007

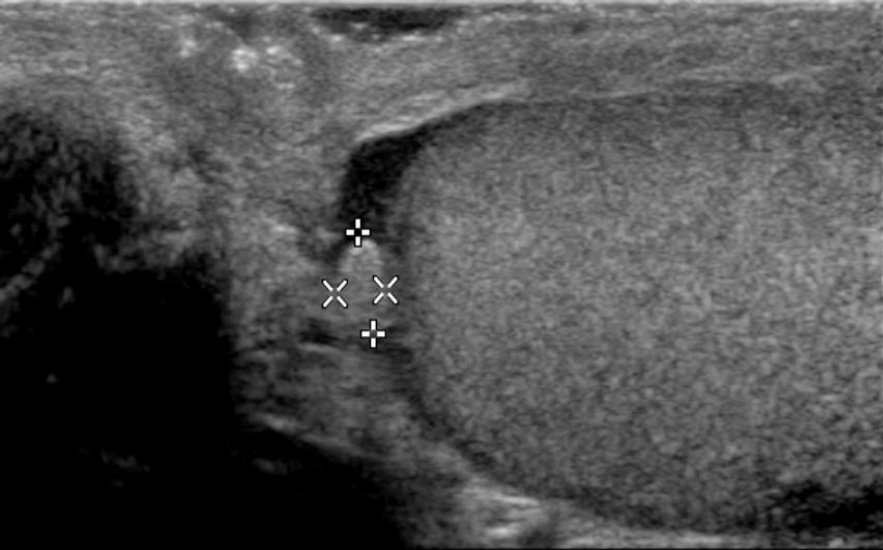
Allan Zhang, DO



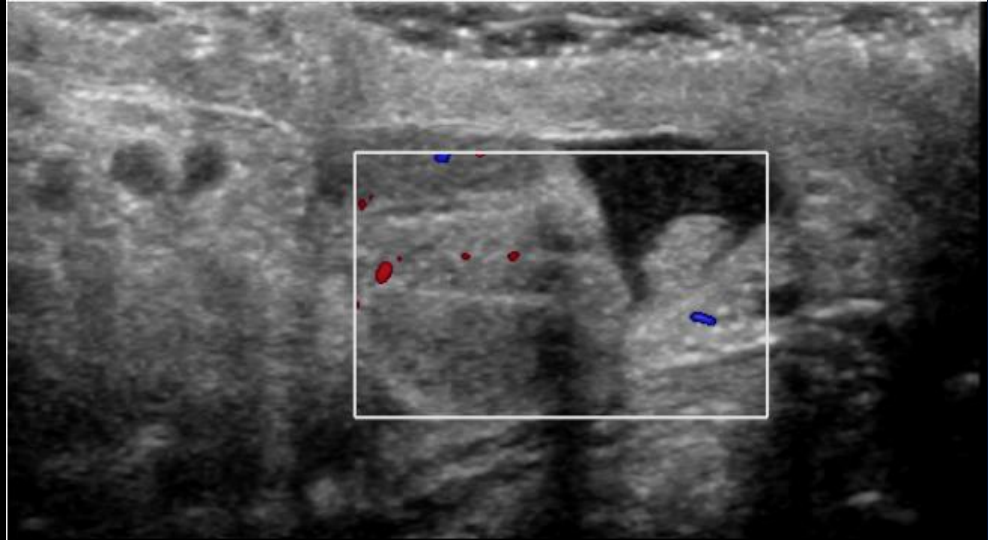
Long Rt Epi Head



Long Rt Testicle Sup



Long Rt Testicle Sup



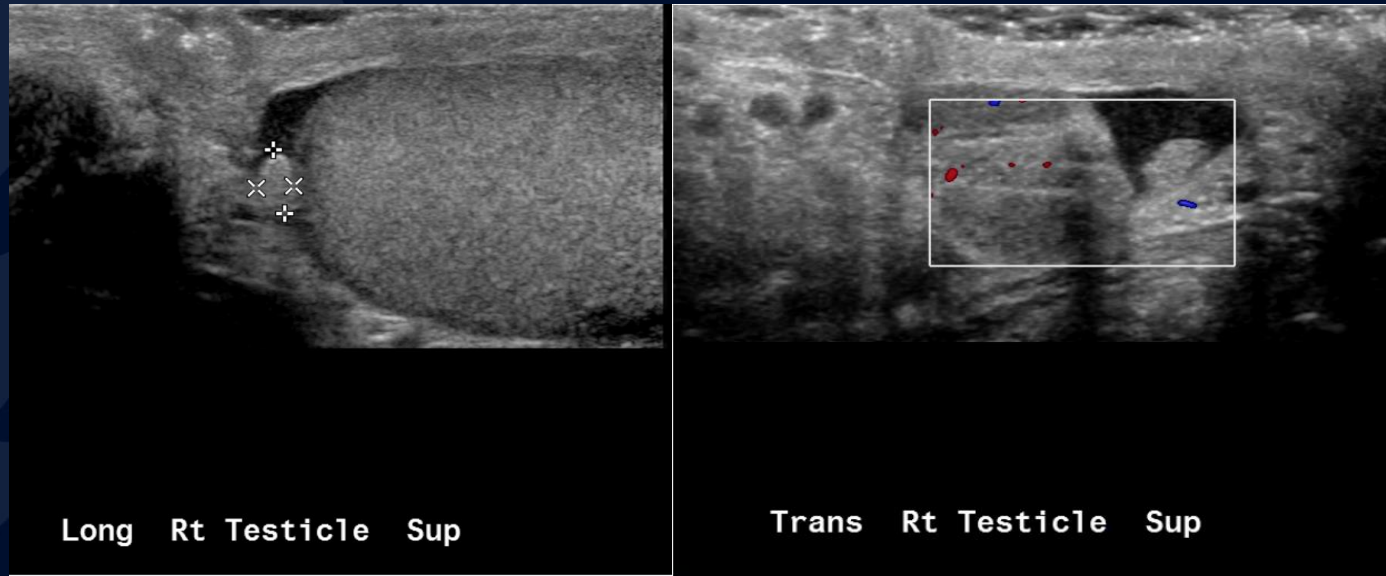
Trans Rt Testicle Sup



?

Torsion of Testicular Appendage

Torsion of testicular appendage



Gray scale and color Doppler of the of the right testicle demonstrates a well circumscribed testicular appendix with no color Doppler flow

Torsion of Testicular Appendage

- Imaging findings:
- Best diagnostic clue enlarged, spherical, hypoechoic, avascular nodule along testis or epididymis at site of patient pain + hyperemia of surrounding tissues.
- Ultrasound with Doppler best imaging modality → Classically, ↓ or absent internal vascularity of torsed appendix with periappendiceal hyperemia
- On grayscale → Appendix size best indicator of torsion (> 5-6 mm acutely)
- Duration of symptoms determines echogenicity < 24 hours: Hypoechoic with salt & pepper pattern, > 24 hours: Hypo-, iso-, or hyperechoic

Torsion of Testicular Appendage

- Top Differential Diagnoses
 - Testicular torsion
 - Epididymoorchitis or orchitis
 - Isolated scrotal wall edema
 - Inguinal hernia complications
 - Testicular or paratesticular tumor
 - Testicular trauma
- Management
 - Self-limited illness, excellent prognosis
 - Conservative pain management