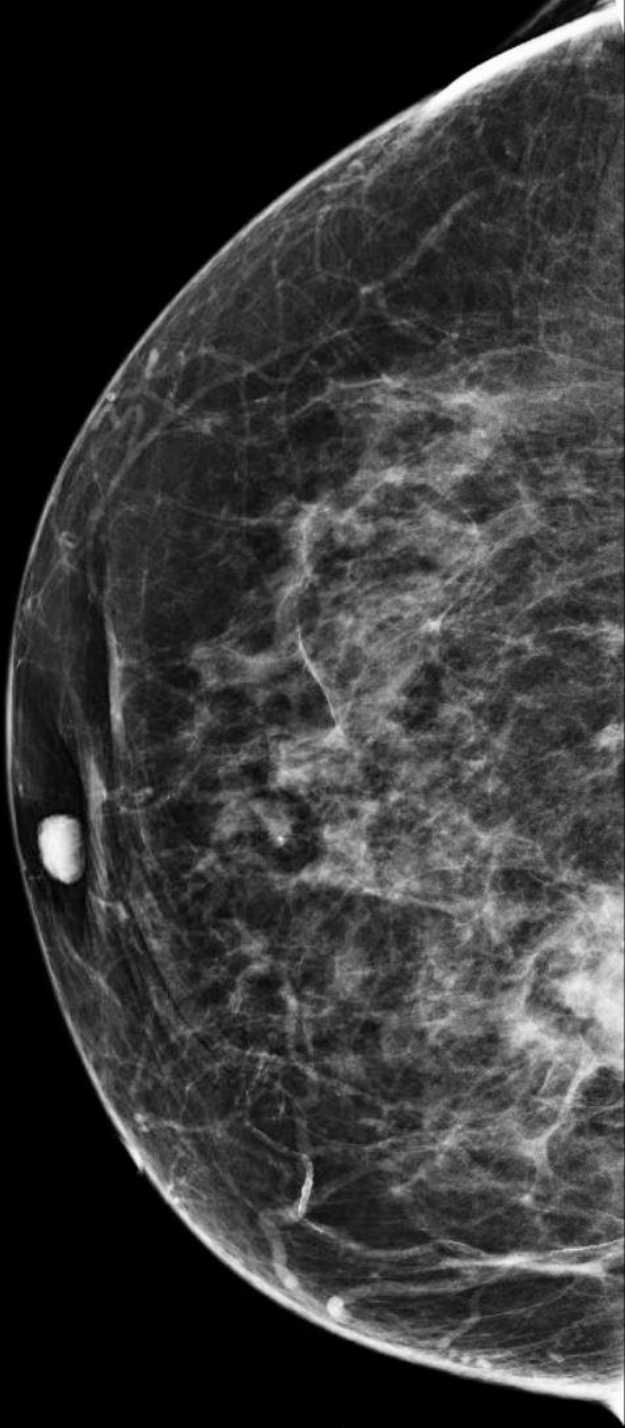


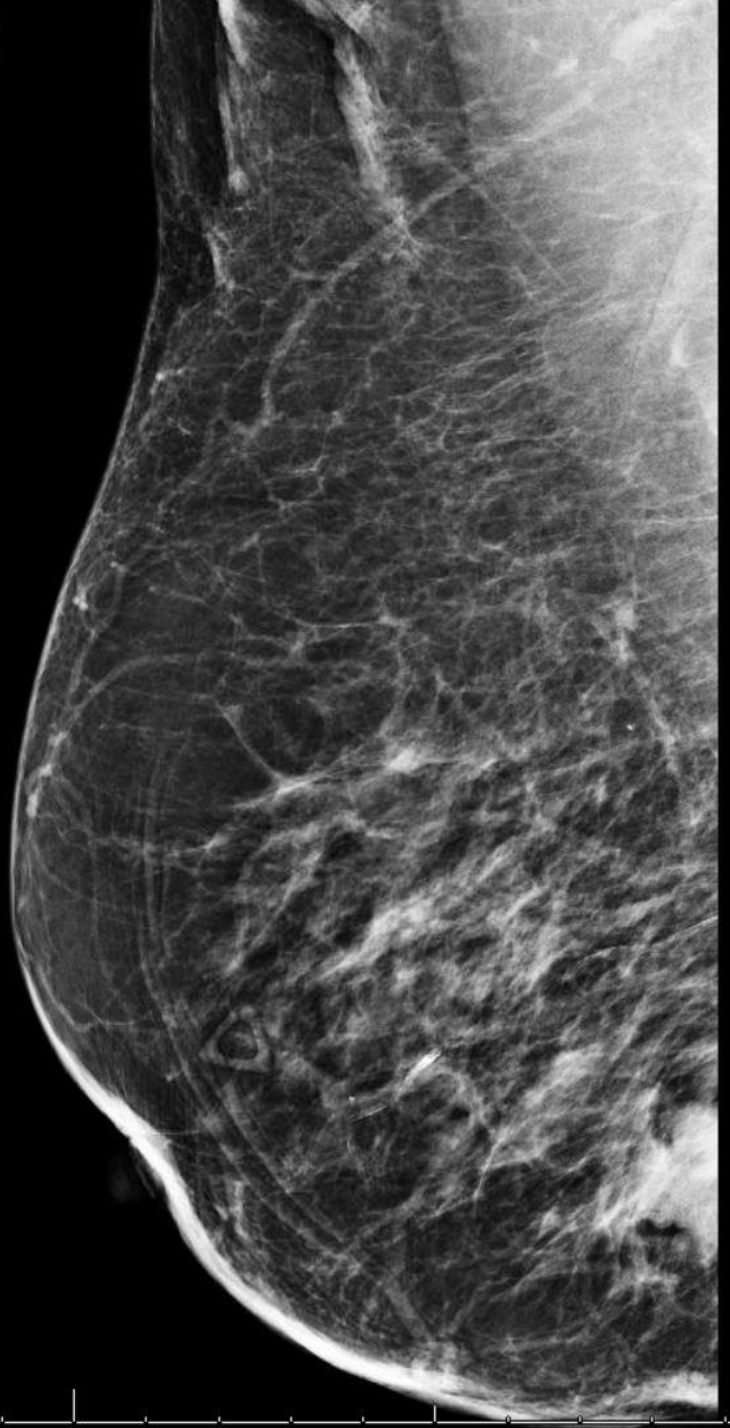
# 91 y/o F with a palpable right breast mass

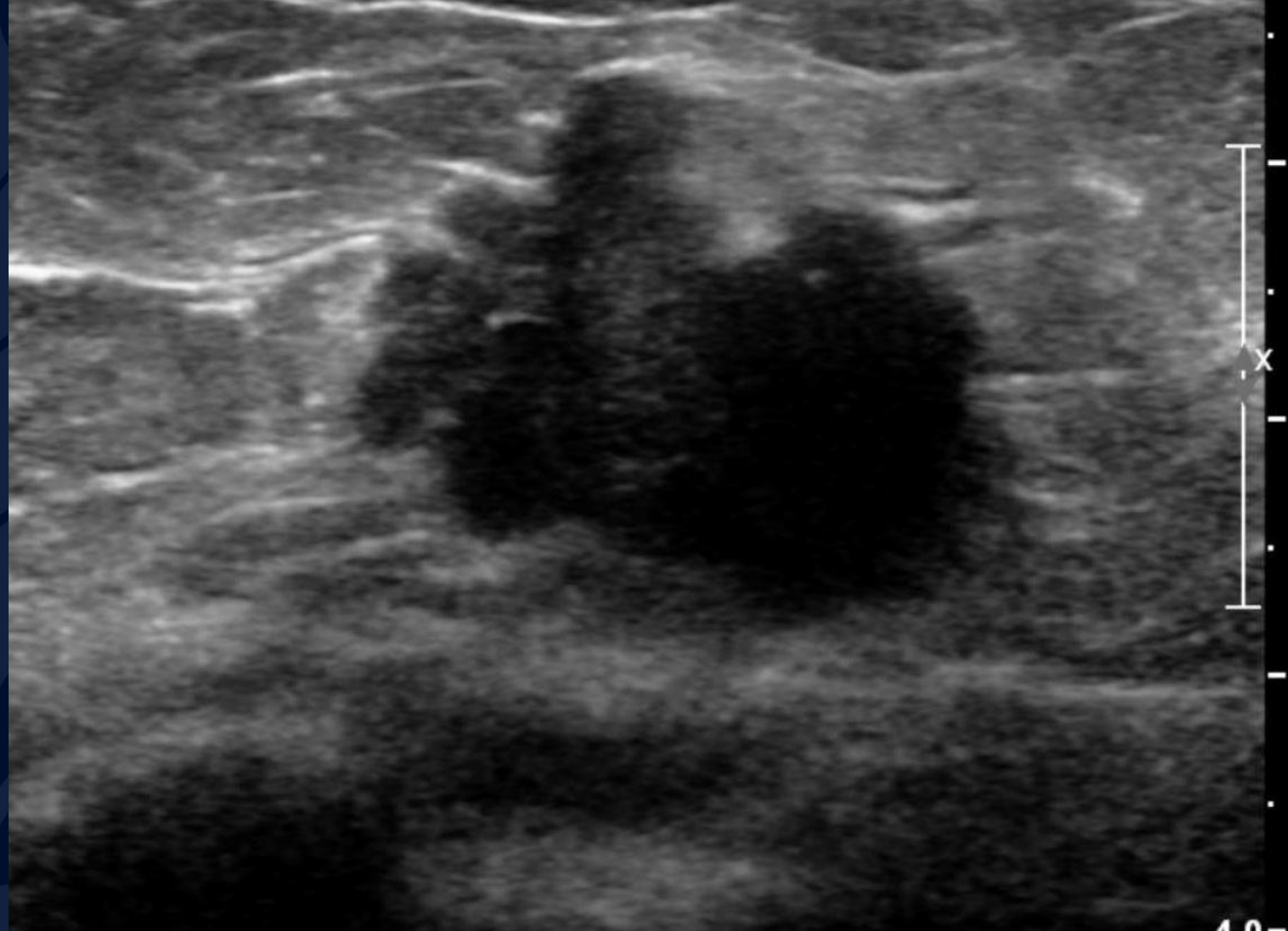
Jeffrey Guzelian MD

RCC



RMLO





4.0-

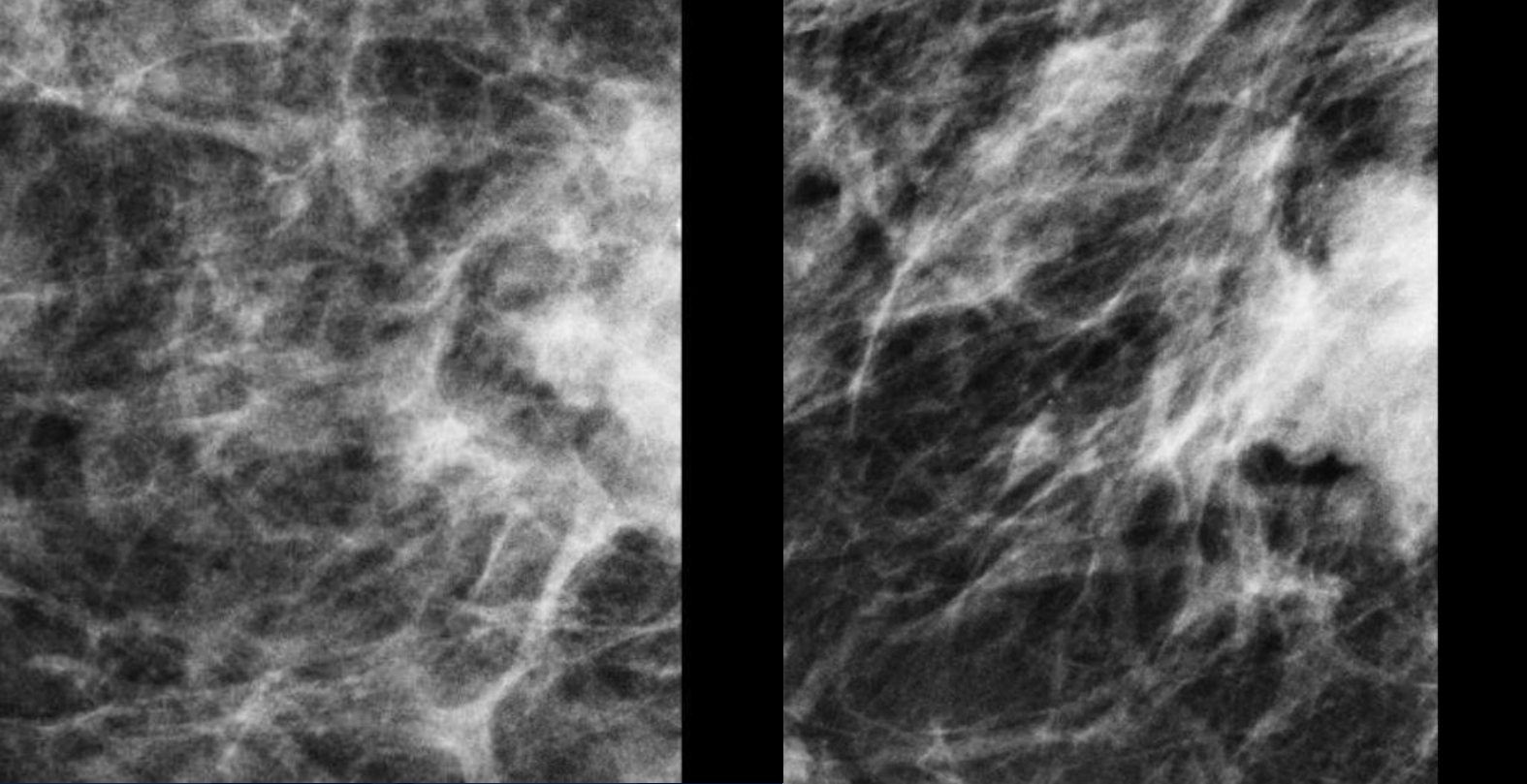
Rt Breast 5:00 A Rad 3 CMFN



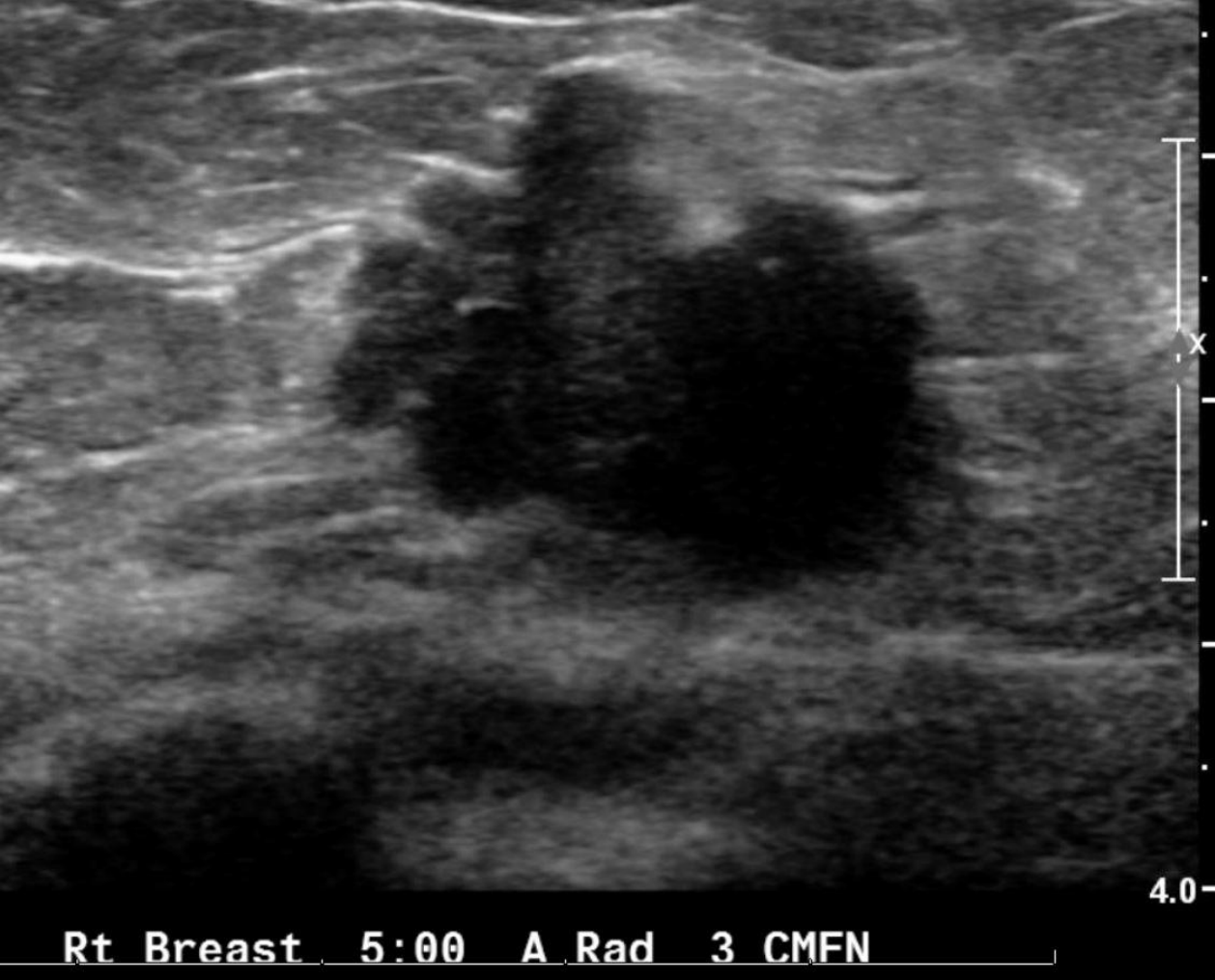?

A large, stylized oak leaf graphic in a dark blue color, positioned on the left side of the slide. The leaf has a prominent central vein and several smaller veins branching off it. The background of the slide is a solid dark blue.

# Invasive Ductal Carcinoma



CC and MLO views of the right breast demonstrate a partially visualized, high density, irregular mass located in the lower inner quadrant at posterior depth.



On a targeted right breast ultrasound, the hypoechoic 5:00 posterior depth mass is solid, irregular in shape, and has a microlobulated margins. There is no significant shadowing. This mass correlates with the mass on mammography.

# BIRADS 5

- Highly suspicious for malignancy right breast mass
- Ultrasound guided biopsy is recommended



# Invasive Ductal Carcinoma

- Extension of tumor cells through basement membrane; loss of myoepithelial cell layer
- Ductal: Implies cellular origin from ductal epithelium vs. "lobular" from breast lobules
- Mammography: Most commonly an irregular mass with spiculated or indistinct margins; Calcifications++ in 31-43%;  $\pm$  architectural distortion
- US: Irregular, hypoechoic mass without posterior enhancement
- MRI: Irregular enhancing mass; rapid wash-in, plateau or washout kinetics