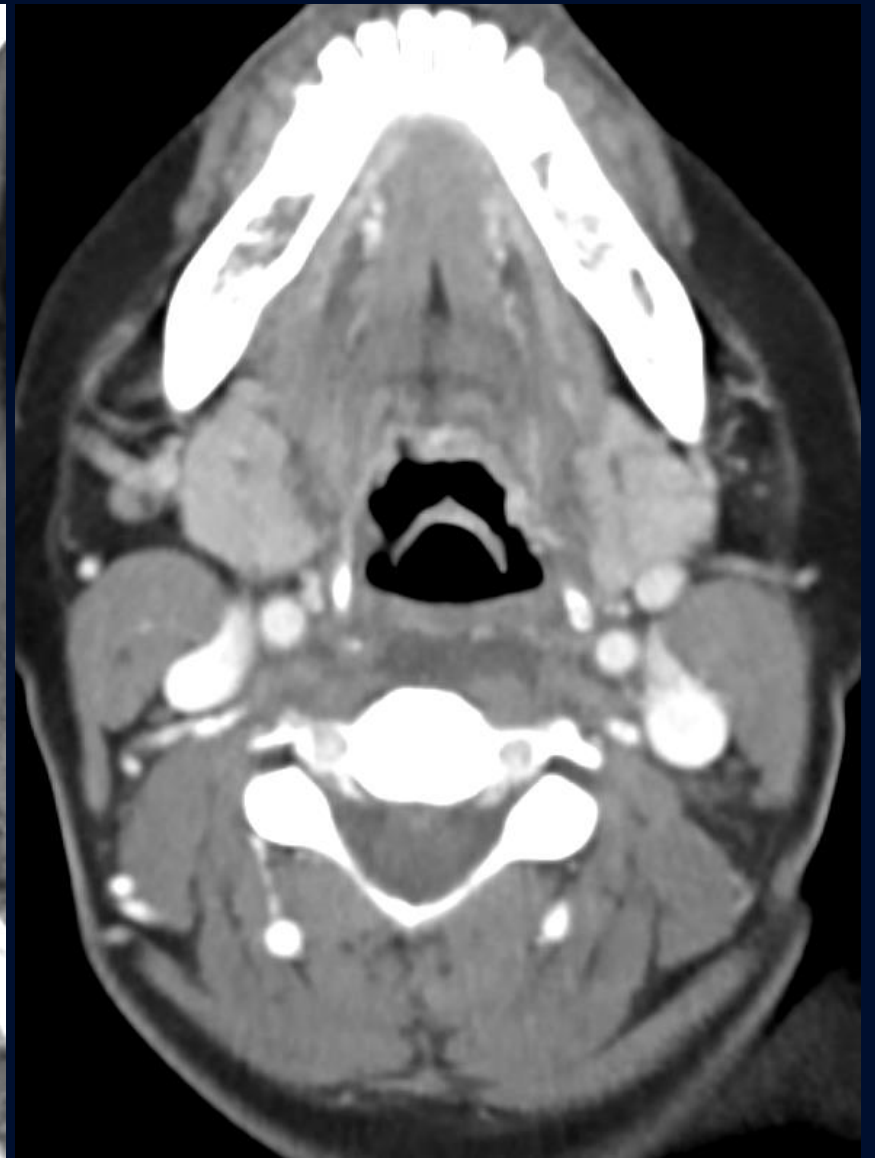
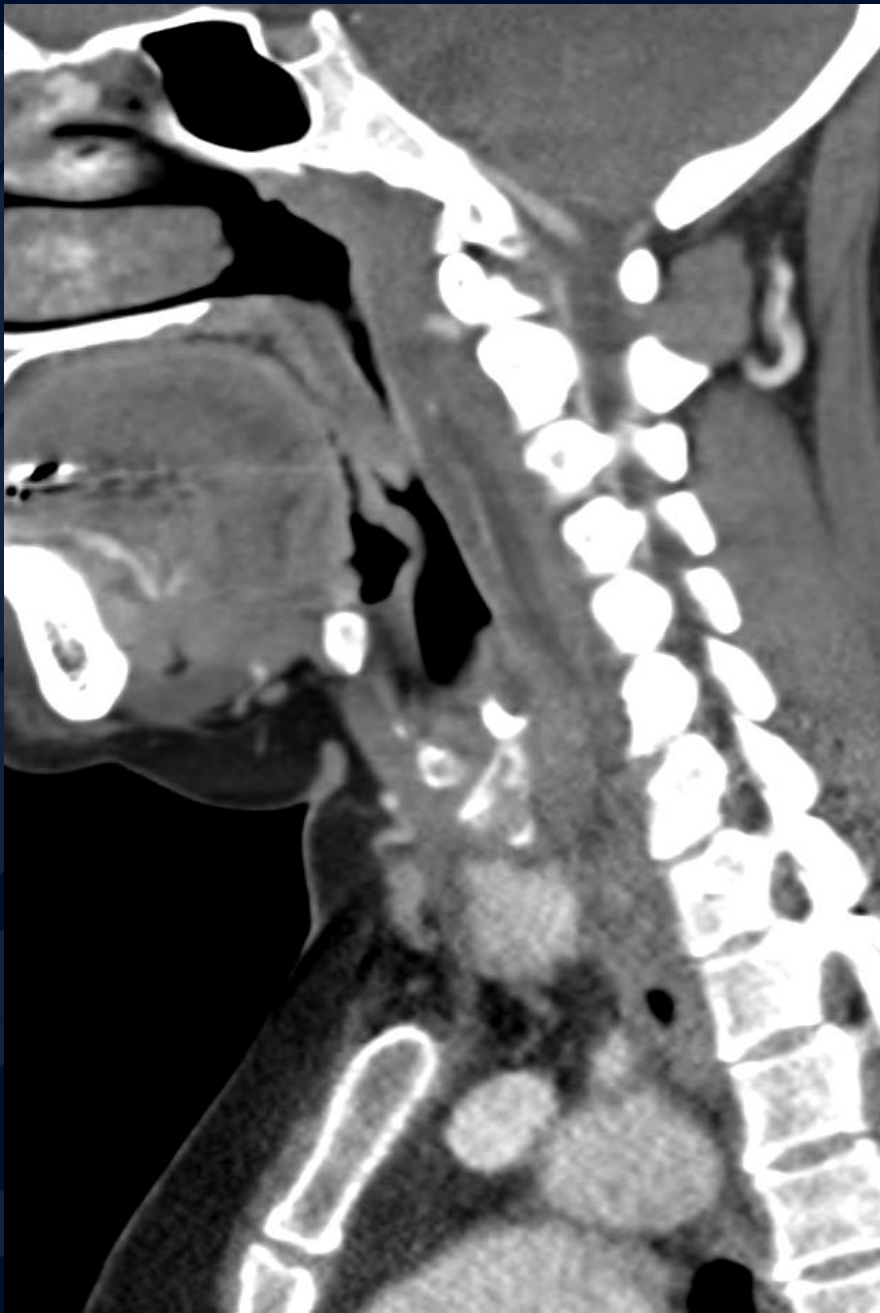

24 year old female, with neck pain.
Patient exercised yesterday (sit-ups).
No fever.

Allan Zhang DO

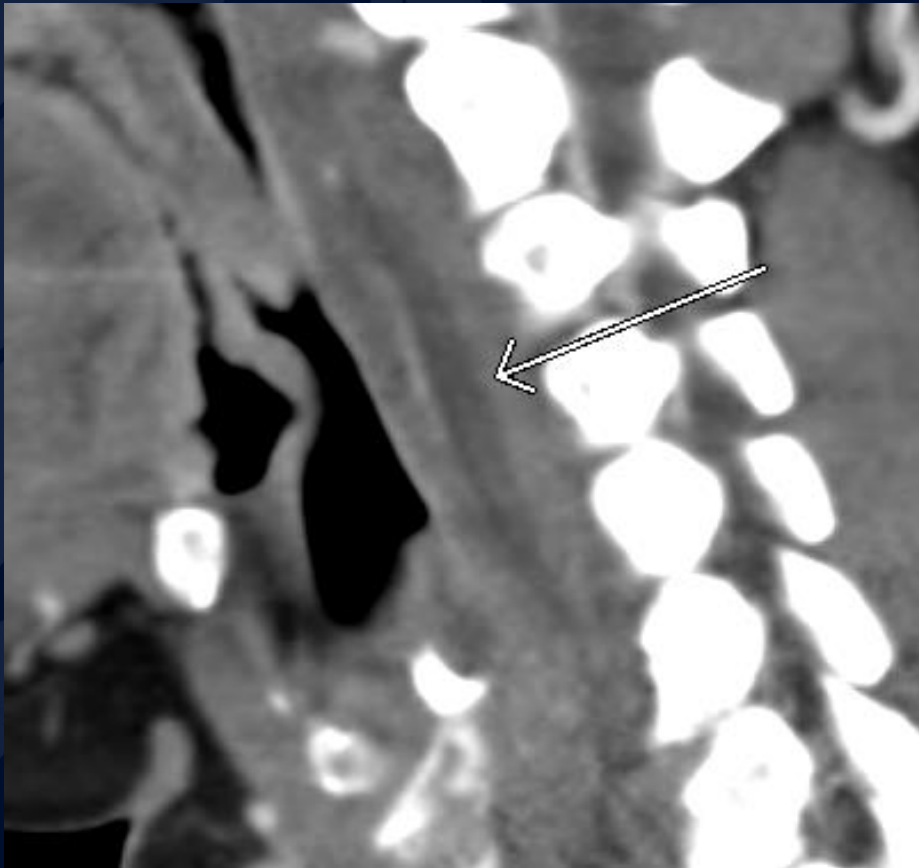


A large, stylized oak leaf graphic in a dark blue color, positioned on the left side of the slide. It features detailed vein patterns and a lobed edge.

?

Longus Colli Tendinitis

Longus Colli Tendinitis



- CECT, fluid collection in the retropharyngeal space (arrow)
- 10-13 HU

Longus Colli Tendinitis

- Imaging:
 - Smooth, mild expansion of RPS without peripheral enhancement
 - Prevertebral calcification(s) at C1-C2, not always present, however, when present it clinches diagnosis.
- Treatment:
 - Self limiting, anti-inflammatory medications

Calcific tendinitis of the longus colli muscle

- Differential Diagnosis:
- Retropharyngeal/prevertebral infection
 - Peripheral enhancement of collection \pm gas if abscess
 - Fever, WBC
 - No prevertebral calcifications