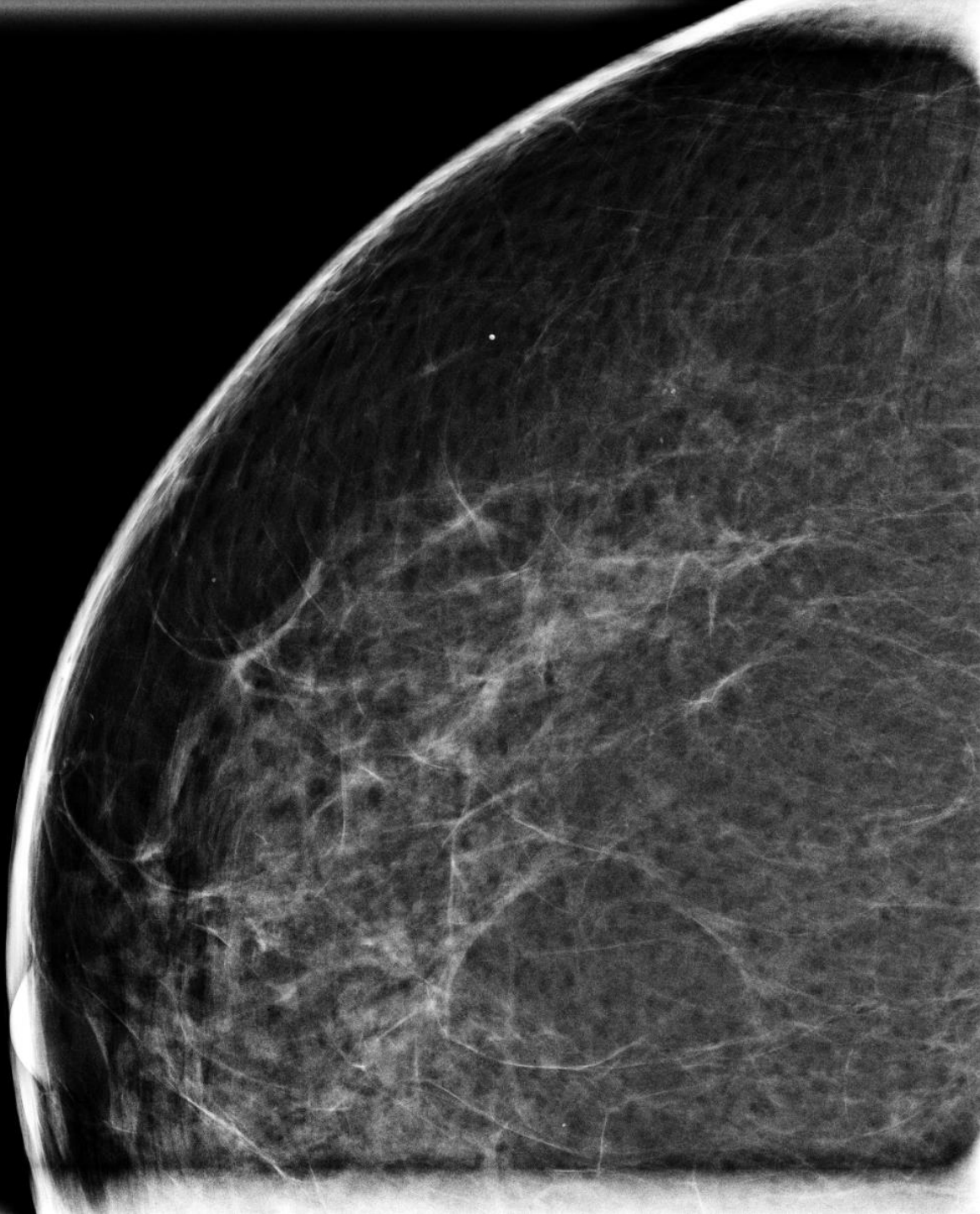


60 y/o female presents for a routine annual mammogram

Allan Zhang DO

- Indeterminate right breast calcifications were noted on screening mammography at middle depth within the lateral breast.
- BI-RADS 0
- Magnification views recommended

RMCC



UConn
HEALTH
RADIOLOGY

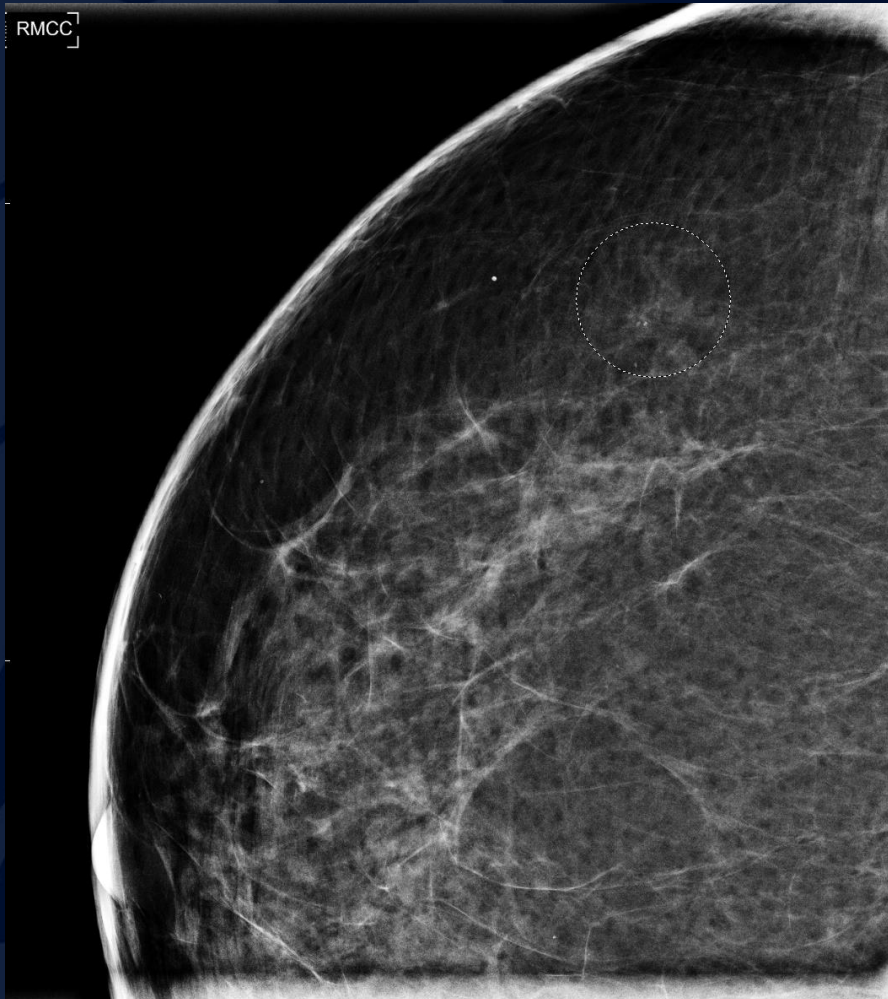
A large, stylized oak leaf graphic in a dark blue color, positioned on the left side of the slide. The leaf has a prominent central vein and several smaller veins branching off it. The leaf's edge is serrated.

?

A large, stylized oak leaf graphic in a dark blue color, positioned on the left side of the slide. The leaf has a prominent central vein and several smaller veins branching off it. The background of the slide is a solid dark blue.

Invasive Ductal Carcinoma

Invasive Ductal Carcinoma



- Right breast CC magnification view
- Lateral middle depth new grouped suspicious calcifications
- BI-RADS 4
- Stereotactic biopsy recommended

Invasive Ductal Carcinoma

- Demographics:
 - Rare < 30 years, increased incidence with age
- Mammography:
 - Irregular equal or high density mass with spiculated, indistinct, or microlobulated margins
 - Associated calcifications (Ca++) in 31-43%; these calcifications may represent ductal carcinoma in situ (DCIS) component
 - Focal asymmetry ± architectural distortion

Treatment

- Localized or early stage breast cancer includes:
 - T1-2: tumors < 5 cm
 - N0-1 : no nodes or involvement of <4 axillary nodes
- Breast-conserving surgery (BCS) for localized tumors
 - With BCS there is risk of leaving small areas of tumor behind. Therefore, BCS is always combined with radiation.
 - The risk of local recurrence is greater in tumors surrounded by an extensive DCIS component.
- Mastectomy is used for large tumor, multicentric disease
- Adjuvant or neoadjuvant chemotherapy for lymph node involvement or higher stage tumors
- ER/PR(+): Tamoxifen or aromatase inhibitor
- Targeted therapy: Trastuzumab (Herceptin) for HER2(+)