

Tomosynthesis improves cancer detection and simplifies workup of suspected abnormalities

By Melissa A. Durand, MD,
and Liane E. Philpotts, MD

Dr. Durand is Assistant Professor of Diagnostic Radiology, Yale University School of Medicine, New Haven, CT, and **Dr. Philpotts** is Professor of Diagnostic Radiology and Chief of Breast Imaging, Yale University School of Medicine, New Haven, CT.

Background

Breast tomosynthesis (BT) is a novel technology that has the potential to advance the field of mammography in both the screening and diagnostic environment. Initial studies estimated reduced recall rates from screening mammography of 30% to 40%.^{1,2} Higher cancer detection rates, better lesion margin analysis and more precise lesion location have also been reported.^{1,2} Tomosynthesis also has the potential to improve workflow efficiency as the 2-dimensional (2D) + tomosynthesis images have been shown to be equal to if not better than additional diagnostic 2D views.³

Presently approved for use as an adjunct to conventional 2D mammography, tomosynthesis images are acquired as 15 low-dose projection images, in a 4 sec sweep. These projection images are then reconstructed into 1-mm slices of the breast. Since the 3-dimensional (3D) images are acquired under the same compression as the 2D image, patient positioning is the same for both exams. The ability to review images slice by slice allows breast tissue to be displayed with less tissue superimposition compared to 2D mammography. This allows true lesions to be more clearly demonstrated.

Patient Information

A 47-year-old female with heterogeneously dense breasts presented for a 6-month follow-up after a benign left breast biopsy and an annual mammography of the right breast. The patient had no family history of breast cancer. A combined 2D and 3D breast tomosynthesis examination was performed on a Hologic Selenia Dimensions system.

Imaging Findings

The 2D (RCC and RMLO) views demonstrate an ill-defined equal density mass in the 12 o'clock position (Figure 1). On the 2D views alone, the margins are not clearly seen. Right CC and MLO views from the previous year are also shown. These images illustrate the challenge of cancer detection in heterogeneously dense breasts (Figure 2).

The 3D (RCC and RMLO) views clearly demonstrate a spiculated mass in the 12 o'clock position, which is highly suspicious for malignancy (Figure 3). Because the tomosynthesis images provided exquisite lesion shape and margin detail along with precise location, additional spot compression views were not necessary and the patient went directly to ultrasound.

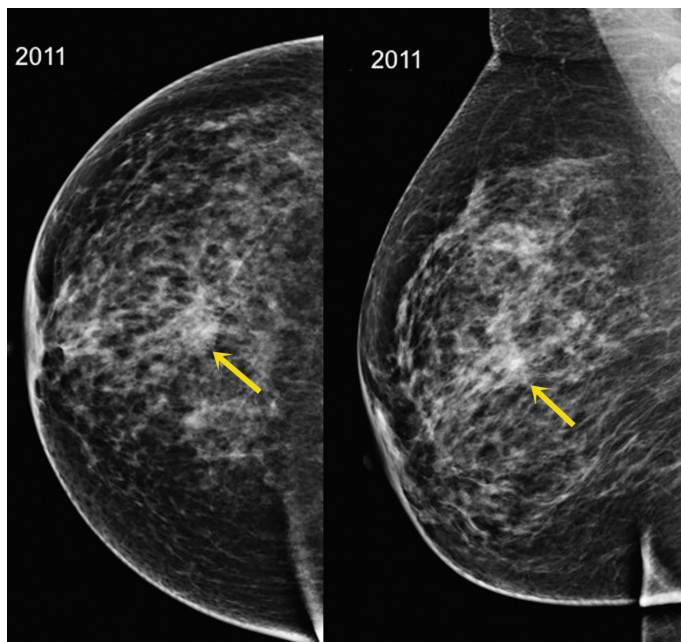


Figure 1. Right CC and MLO 2D views from 2011 demonstrate an ill-defined equal density mass in the 12 o'clock position.

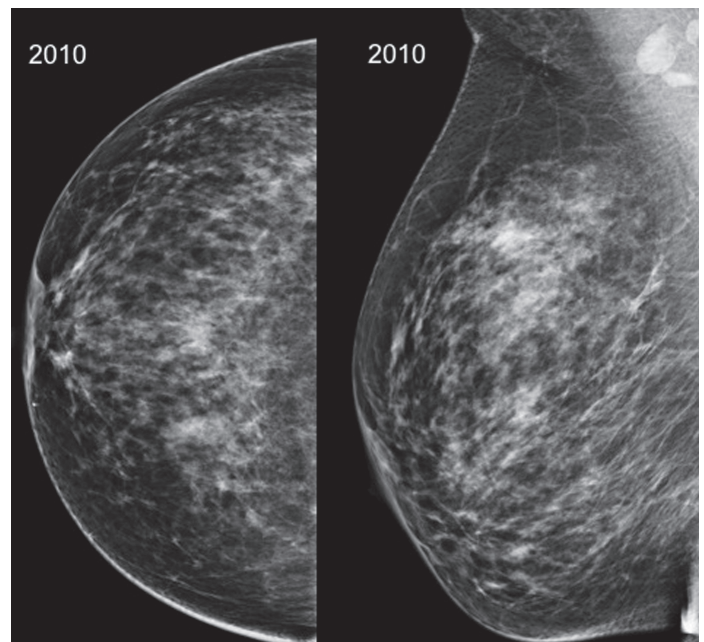


Figure 2. Images from 2010 show that there was little interval change in the 2D appearance of the breast, highlighting the challenge in cancer detection in heterogeneously dense breasts.

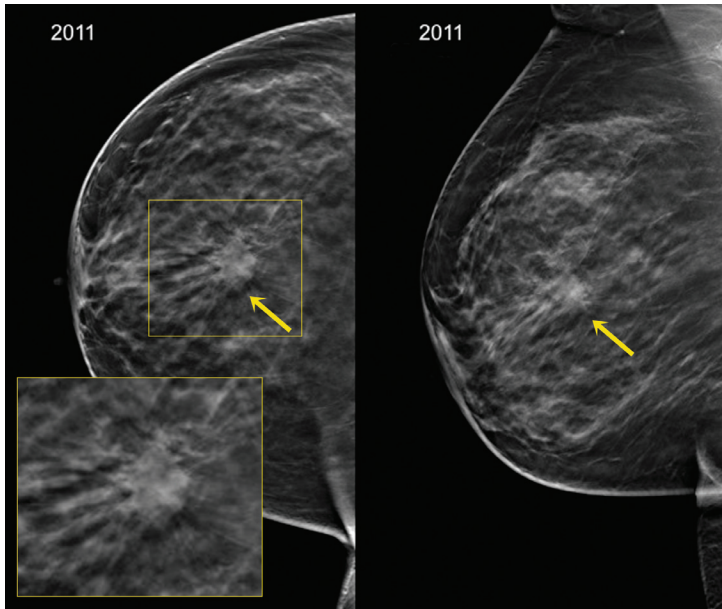


Figure 3. Right CC and MLO tomosynthesis views clearly demonstrate a spiculated mass in the 12 o'clock position.

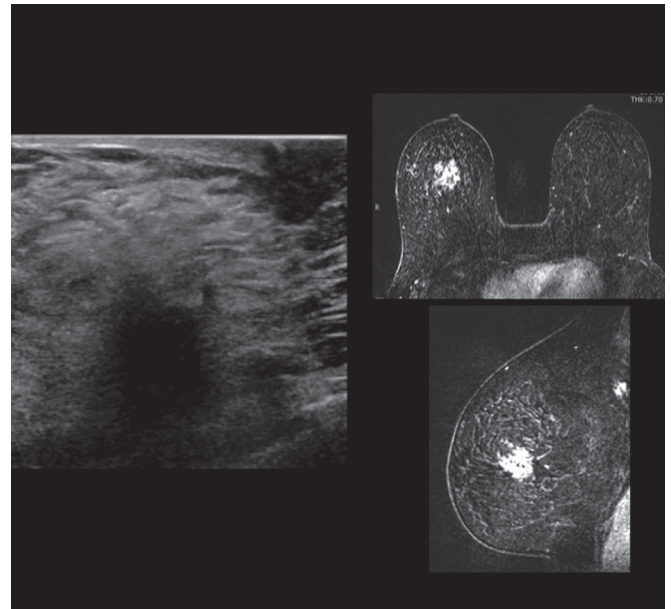


Figure 4. Right breast ultrasound confirmed a hypoechoic, shadowing mass with irregular margins and a bilateral breast MRI showed a spiculated mass with mixed kinetics including washout.

Right breast ultrasound confirmed a 1.9-cm hypoechoic, shadowing mass with irregular margins (Figure 4).

A bilateral breast MRI for extent of disease showed a 2.8 x 3.1-cm spiculated mass with mixed kinetics including washout (Figure 4).

Additional imaging for extent of disease demonstrated osseous metastases to a T12 vertebral body and the left frontal calvarium (not pictured).

Diagnosis

Clinically, Stage IV due to presence of osseous metastases.

The index lesion was a right breast infiltrating ductal carcinoma, nuclear grade 2 with a mucinous carcinoma component. The tumor was 90% estrogen receptor positive, 10% progesterone receptor positive, HER2-positive, and FISH negative.

Treatment

The patient was treated with palliative radiation therapy for the T12 vertebral metastasis and is currently being treated with tamoxifen for systemic treatment of ER+ metastatic disease and denosumab for bone disease.

Discussion

The sensitivity of conventional 2D digital mammography has been shown to be lower in women with dense breasts compared to women with scattered fibroglandular or fatty breasts.⁴ In our case, the abnormality, though visible on 2D, was a vague area of increased density on a background of heterogeneously dense tissue, not significantly changed from the patient's previous mammogram. Without

tomosynthesis, the lesion may not have been appreciated. Additionally, at least 2 supplementary views would have been required for better characterization. However, with the tomosynthesis images, the lesion is clearly visible as a distinct mass with an irregular margin and long spicules. We could confidently assess this as a BIRADS 5, highly suspicious finding, enabling the patient to proceed directly to ultrasound. No additional spot compression views were necessary. In the appropriate clinical setting, this decreased need for additional views could potentially be cost saving, time saving, and radiation dose saving.

Conclusion

Breast tomosynthesis allows for better visualization of lesions, especially in dense breasts. This can result in improved cancer detection and better characterization of lesion margins. We have been able to definitively identify highly suspicious lesions with the use of breast tomosynthesis that would otherwise have required additional views on conventional 2D mammography.

References

1. Poplack SP, Tosteson TD, Kogel CA, Nagy HM. Digital breast tomosynthesis: initial experience in 98 women with abnormal digital screening mammography. *AJR Am J Roentgenol.* 2007;189:616-623.
2. Gur DM, Abrams GS, Chough DM, Gonatt MA, Hakim CA, et al. Digital breast tomosynthesis: observer performance study. *AJR Am J Roentgenol.* 2009;193:586-591.
3. Hakim CM, Chough DM, Ganott MA, Sumkin JH, Zuley ML, Gur D. Digital breast tomosynthesis in the diagnostic setting: a subjective side by side review. *AJR Am J Roentgenol.* 2012;195:172-176.
4. Pisano ED, Hendrick RE, Yaffe MJ, Baum JK et al. Diagnostic Accuracy of Digital versus Film Mammography: Exploratory Analysis of Selected Population Subgroups in DMIST. *Radiology.* 2008;246:376-383.

The views and opinions expressed in this clinical case review are the opinions of the authors and do not necessarily reflect the views and opinions of the sponsoring company.

This article is intended for medical professionals and/or specific product users residing in the United States and other countries and should not be considered as a solicitation or promotion of any product or of an indication of any product that is not authorized by the laws and regulations of another country where the reader resides. This article could refer to products that are or may not be available in any particular country, and/or may not have received market clearance by a governmental regulatory body for indications and restrictions in different countries.

Hologic, Selenia and Dimensions are trademarks and/or registered trademarks of Hologic, Inc.